



Title	Endoscopic ultrasound-assisted direct peritoneal visualization with a small-caliber scope-a proof of concept study in a swine model(本文)
Author(s)	鈴木, 玲
Citation	
Issue Date	2015-03-24
URL	http://ir.fmu.ac.jp/dspace/handle/123456789/637
Rights	© 2014, Wolters Kluwer Medknow Publications. This is the peer reviewed version. Published version is "Endosc Ultrasound. 2014 Oct;3(4):226-31. doi: 10.4103/2303-9027.144535", used under CC BY-NC-SA.
DOI	
Text Version	ETD

Endoscopic Ultrasound

Endoscopic ultrasound-assisted direct peritoneal visualization with a small-caliber scope- a proof of concept study in a swine model --Manuscript Draft--

Manuscript Number:	EUS-D-14-00019
Full Title:	Endoscopic ultrasound-assisted direct peritoneal visualization with a small-caliber scope- a proof of concept study in a swine model
Short Title:	EUS-assisted peritoneoscopy in swine
Article Type:	Original Study
Keywords:	Natural Orifice Transluminal Endoscopic Surgery (NOTES); Peritoneoscopy; Cancer Staging; Tumor Implant; Endoscopic Ultrasound-Guided Fine Needle Aspiration (EUS-FNA).
Corresponding Author:	Manoop S. Bhutani, MD UT MD Anderson Cancer Center Houston, Texas UNITED STATES
Corresponding Author Secondary Information:	
Corresponding Author's Institution:	UT MD Anderson Cancer Center
Corresponding Author's Secondary Institution:	
First Author:	Rei Suzuki, M.D.
First Author Secondary Information:	
Order of Authors:	Rei Suzuki, M.D. Manoop S. Bhutani, MD Dongsuk Shin, PhD Atsushi Irisawa Irisawa, M.D., PhD Jason B. Fleming Rebecca Richards-Kortum, PhD Hiromasa Ohira, M.D., PhD
Order of Authors Secondary Information:	
Manuscript Region of Origin:	JAPAN
Abstract:	<p>Background: Laparoscopic and natural orifice transluminal endoscopic surgery techniques can diagnose peritoneal findings that suggest tumor cell dissemination. However, they have not been incorporated into routine practice, mainly owing to their complexity. To develop a minimally invasive endoscopic technique for the diagnosis of peritoneal findings, we conducted feasibility study using an acute swine model.</p> <p>Methods: This study involved 6 domestic pigs. Trans-gastric access to the peritoneal cavity was performed utilizing an endoscopic ultrasound fine needle aspiration (EUS-FNA) technique. After dilation of the needle hole with a biliary dilatation catheter and balloon, a small-caliber scope was inserted into the peritoneal cavity. Peritoneal images were obtained with the scope and a high-resolution microendoscope (HRME). Main outcome measurements were technical feasibility and time needed to access the peritoneal cavity. Results: Direct visualization of the peritoneum was successful in all 6 pigs and gained access to the gross appearance of the peritoneal cavity. HRME imaging with topical contrast agent also obtained reasonable quality images representing nuclei of the peritoneal mesothelium. Average operation time from the initiation of EUS-FNA to acquiring peritoneal images was 26.5 minutes (range 15-40 minutes). Autopsy found no damage to the adjacent organs, and stomach wall defects were tightly closed with hemostasis clips. Conclusions: Endoscopic ultrasound-</p>

	<p>assisted direct peritoneal visualization with small-caliber scope is technically feasible. HRME may assist in the diagnosis of findings on the peritoneum.</p>
Suggested Reviewers:	<p>Everson Artifon eartifon@hotmail.com He is a reknown endoscopist in the world. We believe he will be appropriate reviewer for this paper.</p>
	<p>Adrian Saftoiu adrian.saftoiu@umfcv.ro He's also famous endoscipst who has a lot of experience in experimental endoscopy using animal models.</p>
Opposed Reviewers:	<p>Kazuki Sumiyama kaz_sum@jikei.ac.jp No reason.</p>

1
2
3
4
5
6 **Endoscopic ultrasound-assisted direct peritoneal visualization with a small-caliber**
7 **scope– a proof of concept study in a swine model**
8
9

10 **Short title:** EUS-assisted peritoneoscopy in swine
11

12
13
14 Rei Suzuki, MD,^{1,2} Manoop S. Bhutani, MD,¹ Dongsuk Shin, PhD,³ Atsushi Irisawa, MD, PhD,⁴
15
16 Jason B. Fleming, MD,⁵ Rebecca Richards-Kortum, PhD,⁶ Hiromasa Ohira, MD, PhD,²
17
18
19
20
21

22 1) Department of Gastroenterology, Hepatology and Nutrition, the University of Texas MD
23 Anderson Cancer Center, Houston, Texas, USA. 2) Department of Gastroenterology and
24 Rheumatology, Fukushima Medical University School of Medicine, Fukushima, Fukushima,
25 Japan. 3) Department of Neurosurgery, the University of Texas Medical School at Houston,
26 Houston, Texas, USA. 4) Department of Gastroenterology, Fukushima Medical University Aizu
27 Medical Center, Aizuwakamatsu, Fukushima, Japan. 5) Department of Surgical Oncology, the
28 University of Texas MD Anderson Cancer Center, Houston, Texas, USA. 6) Department of
29 Bioengineering, Rice University, Houston, Texas, USA.
30
31
32
33
34
35
36
37
38
39
40
41
42
43

44 **Corresponding author**
45

46
47 Manoop S. Bhutani, MD, FASGE, FACG, FACP, AGAF
48

49
50 Professor of Medicine, Experimental Diagnostic Imaging and Biomedical Engineering
51

52
53 Director of Endoscopic Research and Development, Department of Gastroenterology,
54 Hepatology and Nutrition-Unit 1466, The University of Texas MD Anderson Cancer Center,
55
56 1515 Holcombe Boulevard, Houston, Texas, 77030-4009, USA.
57
58
59
60
61
62
63
64
65

manoop.bhutani@mdanderson.org

Author Contributions

Rei Suzuki Study conception and design, acquisition of data, analysis and interpretation of the data, drafting of the article, critical revision of the article for important intellectual content, final approval of the article.

Manoop S Bhutani Study conception and design, analysis and interpretation of the data, drafting of the article, critical revision of the article for important intellectual content, final approval of the article.

Dongsuk Shin Study conception and design, analysis and interpretation of the data, drafting of the article, critical revision of the article for important intellectual content, final approval of the article.

Atsushi Irisawa Drafting of the article, critical revision of the article for important intellectual content, final approval of the article.

Jason B. Fleming Drafting of the article, critical revision of the article for important intellectual content, final approval of the article.

Rebecca Richards-Kortum

Drafting of the article, critical revision of the article for important intellectual content, final approval of the article.

Hiromasa Ohira Study conception and design Drafting of the article, critical revision of the article for important intellectual content, final approval of the article.

Abstract

Background: Laparoscopic and natural orifice transluminal endoscopic surgery techniques can diagnose peritoneal findings that suggest tumor cell dissemination. However, they have not been incorporated into routine practice, mainly owing to their complexity. To develop a minimally invasive endoscopic technique for the diagnosis of peritoneal findings, we conducted feasibility study using an acute swine model. **Methods:** This study involved 6 domestic pigs. Trans-gastric access to the peritoneal cavity was performed utilizing an endoscopic ultrasound fine needle aspiration (EUS-FNA) technique. After dilation of the needle hole with a biliary dilatation catheter and balloon, a small-caliber scope was inserted into the peritoneal cavity. Peritoneal images were obtained with the scope and a high-resolution microendoscope (HRME). Main outcome measurements were technical feasibility and time needed to access the peritoneal cavity. **Results:** Direct visualization of the peritoneum was successful in all 6 pigs and gained access to the gross appearance of the peritoneal cavity. HRME imaging with topical contrast agent also obtained reasonable quality images representing nuclei of the peritoneal mesothelium. Average operation time from the initiation of EUS-FNA to acquiring peritoneal images was 26.5 minutes (range 15–40 minutes). Autopsy found no damage to the adjacent organs, and stomach wall defects were tightly closed with hemostasis clips. **Conclusions:** Endoscopic ultrasound-assisted direct peritoneal visualization with small-caliber scope is technically feasible. HRME may assist in the diagnosis of findings on the peritoneum.

Key words: Natural Orifice Transluminal Endoscopic Surgery (NOTES); Peritoneoscopy; Cancer Staging; Tumor Implant; Endoscopic Ultrasound-Guided Fine Needle Aspiration (EUS-FNA).

1
2
3
4
5
6
7
8
9
10
11
12
13
14
15
16
17
18
19
20
21
22
23
24
25
26
27
28
29
30
31
32
33
34
35
36
37
38
39
40
41
42
43
44
45
46
47
48
49
50
51
52
53
54
55
56
57
58
59
60
61
62
63
64
65

Introduction

Accurate preoperative staging is essential to determine the appropriate treatment strategy in cancer patients. Cross sectional imaging studies, such as computed tomography, and endoscopic ultrasound (EUS) have been widely accepted in clinical practice as a method for pre-operative staging.^{1, 2} However, it remains difficult to detect small metastatic tumor implants on the peritoneum or liver surface even with these state-of-art imaging modalities. Preoperative laparoscopy has been utilized in the staging of various types of cancers and proven to be more accurate for decisions of resectability than other cross-sectional imaging studies and EUS. However, it has not been widely accepted owing to a lack of validated studies and its complexity for this purpose (e.g., requirements for general anesthesia and operating room).³⁻⁷

To overcome the limitations of existing laparoscopic techniques, natural orifice transluminal endoscopic surgery (NOTES) has been recently developed. This new endoscopic technique utilizes natural orifices (e.g., stomach, colon) as access routes to the peritoneal cavity and enables diagnostic and therapeutic procedures with less physiological insult.⁸⁻¹⁰ Recently, several studies have used a standard endoscope in animal models as well as humans to demonstrate this technique for peritoneal exploration (NOTES–peritoneoscopy).¹¹⁻¹³ The results suggest that this novel technique has diagnostic ability to detect minute peritoneal findings equal to that of laparoscopy and has potential application outside the operating room. Although these results are promising, various issues remain to be resolved before there can be widespread application in the daily clinical setting.

One of the most pressing issues in NOTES–peritoneoscopy is the need for reliable transluminal defect closure in order to prevent peritoneal bacterial contamination and severe infection.^{14, 15} To date, various attempts have been made with specially designed devices or

1
2
3
4
5 special techniques.¹⁶⁻¹⁹ We hypothesize that there will be less technical difficulty and chance of
6 bacterial contamination using NOTES–peritoneoscopy with smaller transluminal defects than
7
8 with conventional NOTES techniques.
9

10
11
12
13 In this current study, we demonstrate the technical feasibility of direct peritoneal
14
15 visualization with a commercially available 10 Fr small-caliber scope under EUS guidance.
16
17 Using this method, transluminal defects can be <1 cm in size and readily closed with hemostatic
18
19 clips. We also utilized high-resolution micro-endoscopy (HRME) as a potential auxiliary
20
21 diagnostic tool for peritoneal findings.
22
23
24
25
26
27
28
29
30
31
32
33
34
35
36
37
38
39
40
41
42
43
44
45
46
47
48
49

50 **Material and Methods**

51
52
53 The study was conducted at the animal facility of The University of Texas MD Anderson
54
55 Cancer Center after approval was obtained from the Animal Care and Use Committee. Six male
56
57 domestic pigs weighing between 40 and 50 kg were used. Pigs were deprived of food for 24
58
59 hours before the procedure. Pre-anesthesia medications consisted of intra-muscular injection of
60
61
62
63
64
65

1
2
3
4
5 ketamine (22–33 mg/kg) and acepromazine (0.22–1.1 mg/kg). General anesthesia was
6
7 achieved with isoflurane (1–3% to up to effective dose) and propofol (12 mg/kg/hour). All
8
9 procedures were performed with swine in the left lateral position. Pulse oximetry and
10
11 electrocardiography findings were monitored continuously during the procedures.
12
13
14
15
16
17

18 **Endoscopic devices**

19
20
21 All procedures were performed with a commercially available upper endoscope (GIF-
22
23 160; Olympus, Center Valley, PA) and an endoscopic ultrasound (GF-UC140P-AL5; Olympus).
24
25 An optic fiber with a 10 Fr access and delivery catheter (SpyGlass Direct Visualization System
26
27 and SpyScope; Boston Scientific, Natick, MA) was utilized to obtain the peritoneal cavity images.
28
29
30
31
32
33

34 **High-resolution microendoscopy system**

35
36
37 A recently developed HRME system was also utilized to obtain images of cellular
38
39 morphology and tissue architecture in situ and in real time.^{20, 21} Detailed information regarding
40
41 system assembly and techniques in imaging acquisition has been described previously. Briefly,
42
43 a fluorescent contrast agent (Proflavine, Sigma-Aldrich, St. Louis, MO) was applied topically to
44
45 the targeted tissue to stain nuclei and then a probe placed in contact with the tissue. The HRME
46
47 used here has 4.4- μm spatial resolution and a 720 μm diameter field of view and displays
48
49 images at 12 frames per second in real time. Use of a probe with a 330 μm field of view allows
50
51 passage through a 19-gauge aspiration needle (Expect, Boston Scientific).
52
53
54
55
56
57
58
59

60 **Endoscopic techniques**

61
62
63
64
65

1
2
3
4
5 The entire stomach contents were removed with the upper endoscope during observation. In the
6 next step, endoscopic ultrasound (EUS) was utilized to visualize adjacent organs as well as
7 blood vessels to avoid damage during the procedure. Subsequently, stomach wall puncture was
8 performed with the same method using EUS-guided fine needle aspiration (EUS-FNA) with a
9 19-gauge EUS-FNA needle (Figure 1A).

10
11
12 A 0.035-inch flexible tip guidewire was then inserted into the peritoneal cavity through
13 the EUS-FNA needle lumen with or without fluoroscopic guidance. Along the guidewire, the
14 stomach wall defect was enlarged with a biliary catheter and then a 4-8 mm biliary dilatation
15 balloon (Figure 1B-D). After EUS scope withdrawal, the SpyGlass system deployed within the
16 SpyScope was introduced into the peritoneal cavity over the guidewire under upper endoscope
17 observation (Figure 1E and 1F).

18
19
20 The peritoneal cavity was examined with SpyGlass and HRME through the working
21 channel of the SpyScope. To provide a sufficient space for observation in the peritoneal cavity,
22 sterile saline was infused through the irrigation channels of Spyscope. The biopsy specimen
23 was obtained from the peritoneum with a biopsy forceps (SpyBite, Boston Scientific). At the end
24 of the procedure, SpyGlass was withdrawn and the stomach wall defect was closed with 1 or 2
25 hemostatic clips (Resolution Clip, Boston Scientific).

26
27
28 In the first 3 pigs, fluoroscopy was used with a contrast agent to confirm that the needle
29 tip was positioned in the peritoneal cavity. For the latter 3 pigs, we performed the entire
30 procedure without fluoroscopic guidance to simulate whether this technique can be performed in
31 a standard endoscopic room without fluoroscopy. Instead of fluoroscopic guidance, successful
32 access to the peritoneal cavity was confirmed with EUS. All 6 pigs were euthanized immediately
33 after the procedures.

34
35
36
37
38
39
40
41
42
43
44
45
46
47
48
49
50
51
52
53
54
55
56
57
58
59
60
61
62
63
64
65

Objectives

We aimed to evaluate the technical feasibility of EUS-assisted direct peritoneal visualization utilizing the SpyGlass. As an outcome measure, procedure times between the initiation of EUS-FNA to create the stomach wall hole and acquisition of the peritoneal cavity images were measured in all experiments. Additionally, the efficacy of stomach defect closure was also evaluated at autopsy. Adverse effects and any damage to vascular structures or adjacent organs were also evaluated at autopsy.

Results

We successfully performed EUS-assisted trans-gastric direct peritoneal visualization with a 10 Fr small-caliber scope in all 6 pigs. No significant acute adverse events occurred during any of the procedures, including creating a stomach wall defect with EUS-FNA needle, dilatation of the hole with dilatation catheter and balloon, SpyScope insertion into the peritoneal cavity, and visualization of the peritoneum even without fluoroscopic guidance.

SpyGlass could obtain gross appearance of the peritoneum with reasonable quality image. HRME imaging following topical contrast agent application also could obtain images representing the nuclei of the peritoneal cells covering the small intestine (Figure 2). Additionally, small biopsy forceps could selectively obtain a specimen from the peritoneum at the same point where HRME obtained its image (Figure 3). After withdrawal of the SpyScope from the peritoneal cavity, 1 or 2 hemostasis clips were deployed to close the stomach wall defect (Figure 4A). Autopsy revealed that the defect was closed tightly enough to prevent air leakage from inflated stomach on gross inspection (Figure 4B). Average operation time between the initiation of EUS-FNA and acquiring peritoneal images was 26.5 minutes (range 15– 40 minutes). Consistent with a rapid learning curve, the average operation time was shorter in the latter 3 pigs without fluoroscopic guidance (19.6 minutes) than in the first 3 pigs with fluoroscopic guidance (33.3 minutes). Autopsy identified no bleeding or damage to the adjacent organs.

Discussion

Our pilot study demonstrates the technical feasibility of EUS-assisted direct peritoneal visualization with a 10 Fr small-caliber scope in a swine model. As we hypothesized, the <1 cm stomach wall defect can be closed tightly with commercially available hemostasis clips without any special techniques. Additionally, HRME allowed us to obtain reasonable quality images of the peritoneum that can assist in the diagnosis of peritoneal findings.

There are several ways to diagnose peritoneal findings, which can change treatment strategy regarding resectability of disease in cancer patients. Cross-sectional imaging modalities (e.g., computed tomography, magnetic resonance imaging, and positron emission topography) can detect lesions on the peritoneum. However, it has been consistently reported that these state-of-art cross-sectional imaging modalities are falsely negative in up to one third of patients.⁵ On the other hand, several invasive procedures (e.g., open laparotomy, laparoscopy and NOTES–peritoneoscopy) can explore within the peritoneal cavity and may have the ability to detect and obtain specimens from small metastatic tumor implants. Compared with conventional open laparotomy, laparoscopic techniques utilizing specially designed devices make a smaller incision on the external body surface and require less invasive manipulation. These techniques have various benefits for patients, including less pain and a shorter hospital stay.

NOTES is an endoscopic technique that requires no external incision and which can potentially perform diagnostic and therapeutic procedures that have previously required laparoscopy.^{9,10} Currently, NOTES procedures utilize a conventional upper endoscope or a two-channel scope 10 mm in diameter or more. Consequently, this procedure usually requires a transluminal defect that may be up to 20 mm in some cases and has a chance of bacterial

1
2
3
4
5 contamination via luminal organs (e.g., colon, stomach).^{13, 15, 22} To date, how to close the
6
7 NOTES transluminal defect lying in the deep part of the body in a secure, reliable, and safe
8
9 manner is still under debate. We believe that our concept, direct peritoneal visualization with a
10
11 smaller caliber scope, may offer an advance in NOTES–peritoneoscopy because our results
12
13 show the defect can be readily closed with standard devices and technique. In addition, we
14
15 surmise that this procedure can be performed along with other endoscopic procedures for
16
17 cancer diagnosis or staging, because the additional procedural time to access the peritoneal
18
19 cavity can be less than 20 minutes.
20
21
22

23
24 Several limitations in study design and device specifications should be addressed in the
25
26 further studies that are necessary to refine this approach. Animal survival studies should be
27
28 conducted to verify long-term safety. Evaluation of the orientational ability of this procedure in
29
30 detecting certain points of interest in comparison with a standard technique (e.g., laparoscopy)
31
32 is needed. Given the design of the SpyGlass system for pancreatobiliary diseases, its
33
34 specifications are not sufficient to perform peritoneoscopy at this time. Further developments
35
36 are required especially in its pixilation to obtain clearer images, and scope stiffness and
37
38 adequate angulation of the scope tip which can enable us to manipulate the catheter smoothly
39
40 within in the peritoneal cavity.
41
42
43
44

45 The HRME has been developed quite recently and its potential to aid in the diagnosis of
46
47 gastrointestinal neoplasms has been explored.^{20, 21, 23, 24} Although histopathological diagnosis is
48
49 the standard method for definite diagnosis, the ability of this device to visualize cellular
50
51 morphology and tissue architecture in real time may help us to diagnose target lesions in cases
52
53 in which biopsy sampling is difficult to obtain or hard to interpret. Considering the small size of
54
55 the specimens obtained in this study, this technique may be ancillary to other diagnostic
56
57 methods. We believe that this low-cost portable system (less than \$3,500 to build) can be a
58
59
60
61
62
63
64
65

1
2
3
4
5 reasonable choice for this purpose. Further study is required to evaluate characteristics of
6
7 normal, benign, and malignant lesions of the peritoneum using the HRME.
8
9

10 In conclusion, EUS-assisted trans-gastric direct peritoneal visualization with a small-
11 caliber scope is technically feasible. Furthermore, HRME imaging with topical contrast agent
12 application may assist in the histological diagnosis of the peritoneal findings. Survival studies
13 with control groups and more improvement in devices are needed to demonstrate the true value
14 of this technique.
15
16
17
18
19
20
21
22
23
24
25

26 **Acknowledgement**

27
28 We are grateful to Dr. Agatha Borne, DVM, PhD and the staff of Veterinary Medicine and
29 Surgery as well as the John S. Dunn Center for Radiological Sciences for their help and support
30 of this project.
31
32
33
34
35
36
37
38
39

40 **DISCLOSURE**

41
42 Dr. Bhutani is supported by Boston Scientific Investigator-Sponsored Research Program. Dr.
43 Suzuki is supported by a research grant from the Japanese Foundation for Research and
44 Promotion of Endoscopy. Dr. Richards-Kortum is supported by NCI Cancer Center Support
45 Grant (CA016672) and NIH grant 5R01 EB007594 and holds minority ownership of Remicalm,
46 LLC as a scientific advisor. The endoscopic equipment was provided by Olympus Corporation of
47 the America to MD Anderson Cancer Center for endoscopic research by any investigator. Dr.
48 Shin, Dr. Irisawa, Dr. Ohira and Dr. Fleming have no conflict of interest or financial ties to
49 disclose relevant to this study. Supported by NCI Cancer Center Support Grant (CA016672).
50
51
52
53
54
55
56
57
58
59
60
61
62
63
64
65

Figure legends

Figure 1. Endoscopic techniques. **A**, A stomach defect was created with an endoscopic ultrasound-guide fine needle aspiration technique. **B, C, D**, The defect was dilated with biliary catheter and balloon under fluoroscopic guidance. **E**, A small-caliber scope was inserted into the peritoneal cavity. **F**, The peritoneum was visualized.

Figure 2. HRME imaging of the peritoneum. White dots represent nuclei of the peritoneal mesothelium which are stained with the fluorescent contrast agent.

Figure 3. Biopsy specimen obtained from the peritoneum (magnification $\times 100$).

Figure 4. The stomach defect closure. **A**, A hemostatic clip was deployed to close the defect with upperendoscope. **B**, Autopsy revealed that the defect was closed tightly enough to prevent any leakage (arrow).

REFERENCES

1. Freeny PC, Traverso LW, Ryan JA. Diagnosis and staging of pancreatic adenocarcinoma with dynamic computed tomography. *Am J Surg* 1993;165:600-6.
2. Saftoiu A, Vilmann P. Role of endoscopic ultrasound in the diagnosis and staging of pancreatic cancer. *J Clin Ultrasound* 2009;37:1-17.
3. Blackshaw GR, Barry JD, Edwards P, et al. Laparoscopy significantly improves the perceived preoperative stage of gastric cancer. *Gastric Cancer* 2003;6:225-9.
4. Callery MP, Chang KJ, Fishman EK, et al. Pretreatment assessment of resectable and borderline resectable pancreatic cancer: expert consensus statement. *Ann Surg Oncol* 2009;16:1727-33.
5. Liu RC, Traverso LW. Diagnostic laparoscopy improves staging of pancreatic cancer deemed locally unresectable by computed tomography. *Surg Endosc* 2005;19:638-42.
6. Shoup M, Winston C, Brennan MF, et al. Is there a role for staging laparoscopy in patients with locally advanced, unresectable pancreatic adenocarcinoma? *J Gastrointest Surg* 2004;8:1068-71.
7. Maire F, Sauvanet A, Trivin F, et al. Staging of pancreatic head adenocarcinoma with spiral CT and endoscopic ultrasonography: an indirect evaluation of the usefulness of laparoscopy. *Pancreatology* 2004;4:436-40.
8. Marescaux J, Dallemagne B, Perretta S, et al. Surgery without scars: report of transluminal cholecystectomy in a human being. *Arch Surg* 2007;142:823-6; discussion 826-7.
9. Palanivelu C, Rajan PS, Rangarajan M, et al. Transvaginal endoscopic appendectomy in humans: a unique approach to NOTES--world's first report. *Surg Endosc* 2008;22:1343-7.

- 1
2
3
4
5
6
7
8
9
10
11
12
13
14
15
16
17
18
19
20
21
22
23
24
25
26
27
28
29
30
31
32
33
34
35
36
37
38
39
40
41
42
43
44
45
46
47
48
49
50
51
52
53
54
55
56
57
58
59
60
61
62
63
64
65
10. Whiteford MH, Denk PM, Swanstrom LL. Feasibility of radical sigmoid colectomy performed as natural orifice transluminal endoscopic surgery (NOTES) using transanal endoscopic microsurgery. *Surg Endosc* 2007;21:1870-4.
11. Voermans RP, Sheppard B, van Berge Henegouwen MI, et al. Comparison of Transgastric NOTES and laparoscopic peritoneoscopy for detection of peritoneal metastases. *Ann Surg* 2009;250:255-9.
12. Voermans RP, van Berge Henegouwen MI, Bemelman WA, et al. Feasibility of transgastric and transcolonic natural orifice transluminal endoscopic surgery peritoneoscopy combined with intraperitoneal EUS. *Gastrointest Endosc* 2009;69:e61-7.
13. Nikfarjam M, McGee MF, Trunzo JA, et al. Transgastric natural-orifice transluminal endoscopic surgery peritoneoscopy in humans: a pilot study in efficacy and gastrotomy site selection by using a hybrid technique. *Gastrointest Endosc* 2010;72:279-83.
14. Narula VK, Happel LC, Volt K, et al. Transgastric endoscopic peritoneoscopy does not require decontamination of the stomach in humans. *Surg Endosc* 2009;23:1331-6.
15. McGee MF, Marks JM, Onders RP, et al. Infectious implications in the porcine model of natural orifice transluminal endoscopic surgery (NOTES) with PEG-tube closure: a quantitative bacteriologic study. *Gastrointest Endosc* 2008;68:310-8.
16. McGee MF, Marks JM, Jin J, et al. Complete endoscopic closure of gastric defects using a full-thickness tissue plicating device. *J Gastrointest Surg* 2008;12:38-45.
17. McGee MF, Marks JM, Onders RP, et al. Complete endoscopic closure of gastrotomy after natural orifice transluminal endoscopic surgery using the NDO Plicator. *Surg Endosc* 2008;22:214-20.
18. Meireles OR, Kantsevov SV, Assumpcao LR, et al. Reliable gastric closure after natural orifice transluminal endoscopic surgery (NOTES) using a novel automated flexible stapling device. *Surg Endosc* 2008;22:1609-13.

- 1
2
3
4
5
6 19. Saftoiu A, Bhutani MS, Vilmann P, et al. Feasibility study of EUS-NOTES as a novel
7 approach for pancreatic cancer staging and therapy: an international collaborative study.
8 Hepatogastroenterology 2013;60:180-6.
9
- 10
11 20. Pierce M, Yu D, Richards-Kortum R. High-resolution fiber-optic microendoscopy for in
12 situ cellular imaging. J Vis Exp 2011.
13
- 14
15 21. Regunathan R, Woo J, Pierce MC, et al. Feasibility and preliminary accuracy of high-
16 resolution imaging of the liver and pancreas using FNA compatible microendoscopy
17 (with video). Gastrointest Endosc 2012;76:293-300.
18
19
- 20
21 22. Lomanto D, Chua HC, Myat MM, et al. Microbiological contamination during transgastric
23 and transvaginal endoscopic techniques. J Laparoendosc Adv Surg Tech A
24 2009;19:465-9.
25
26
- 27
28 23. Chang SS, Shukla R, Polydorides A, et al. High resolution microendoscopy for
29 classification of colorectal polyps Endoscopy 2013;45:553-559.
30
31
- 32
33 24. Vila PM, Kingsley MJ, Polydorides AD, et al. Accuracy and interrater reliability for the
34 diagnosis of Barrett's neoplasia among users of a novel, portable high-resolution
35 microendoscope. Dis Esophagus 2014;27:55-62.
36
37
38
39
40
41
42
43
44
45
46
47
48
49
50
51
52
53
54
55
56
57
58
59
60
61
62
63
64
65

Figure1A
[Click here to download high resolution image](#)

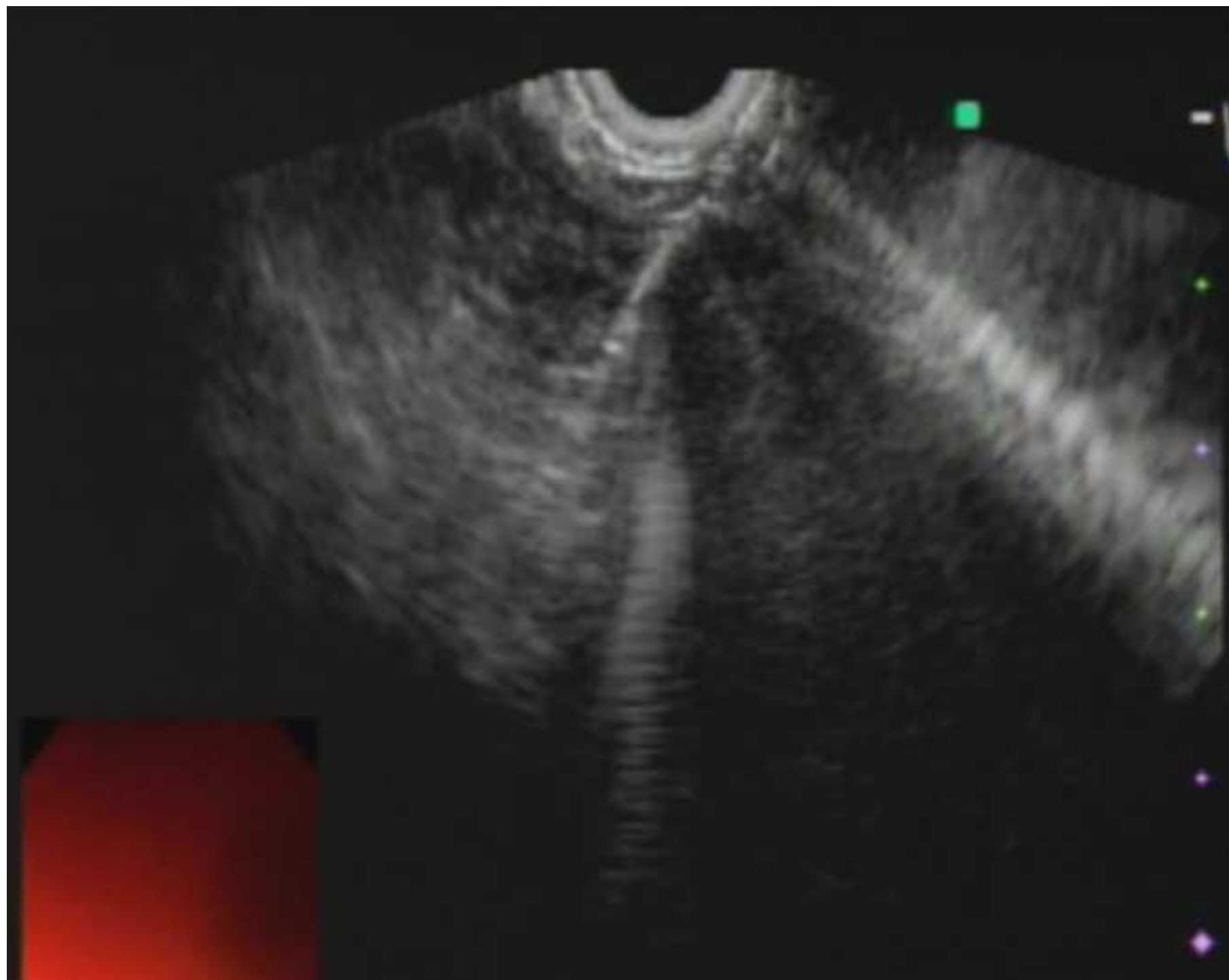


Figure 1B

[Click here to download high resolution image](#)

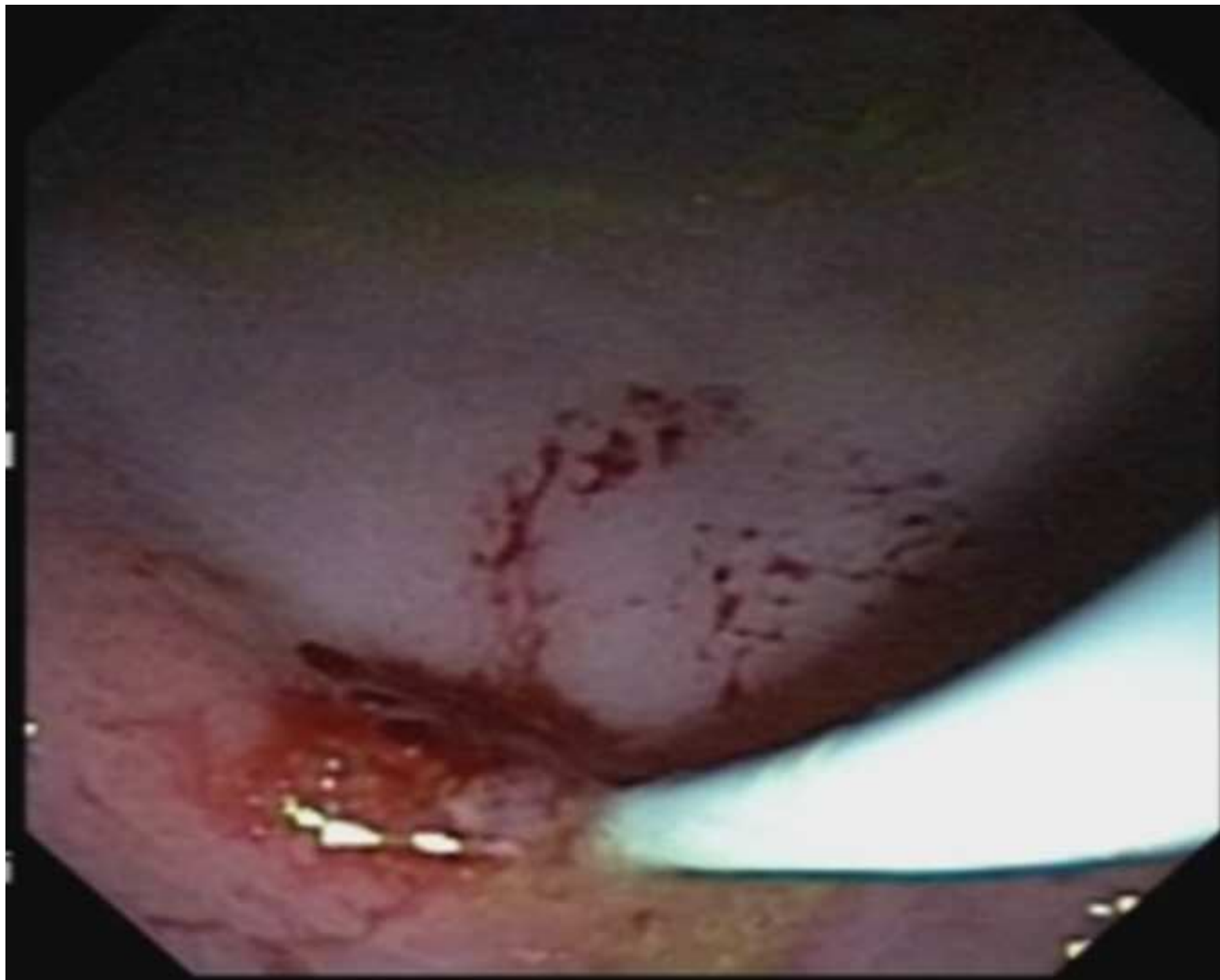

Figure 1C

[Click here to download high resolution image](#)

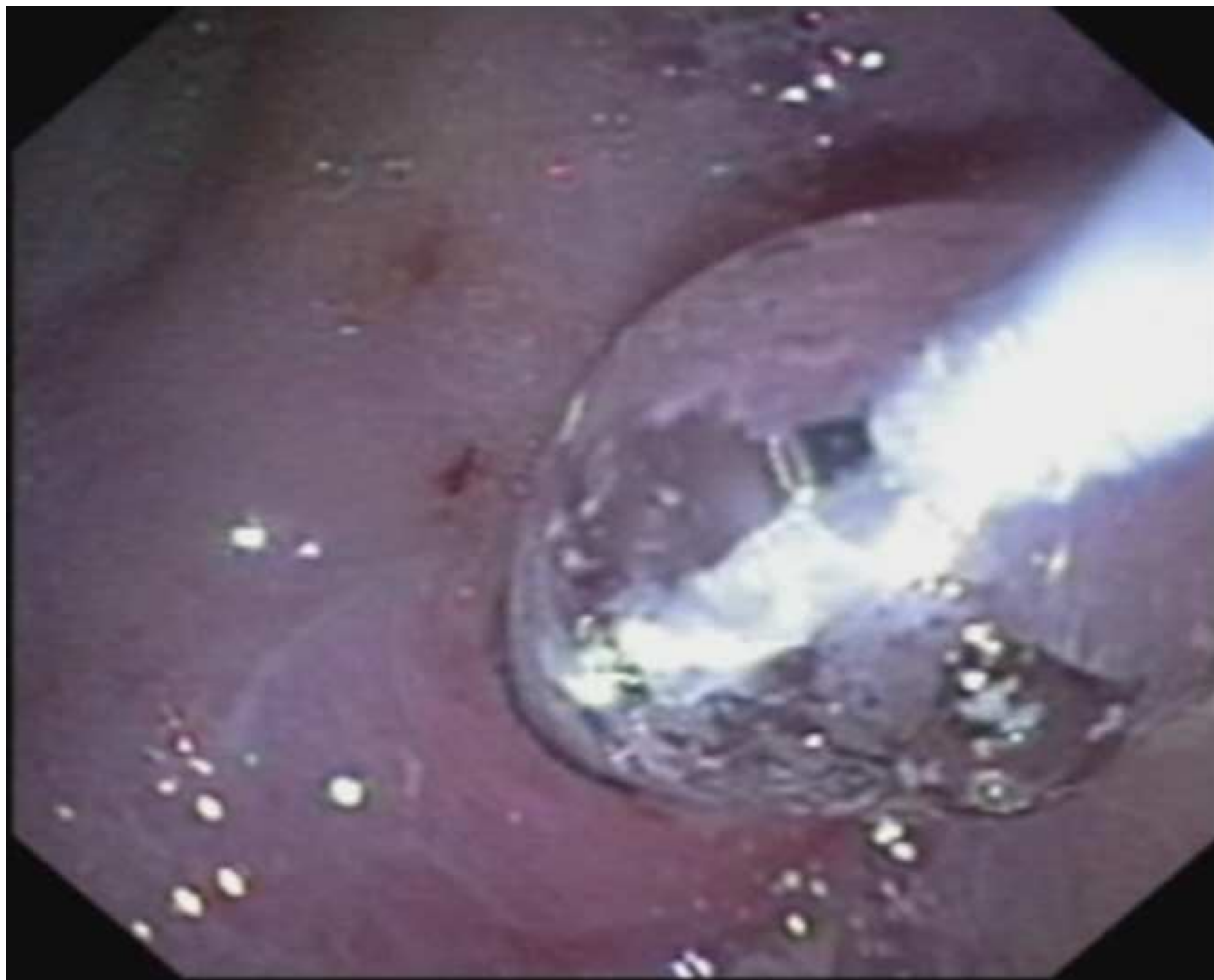

Figure 1D
[Click here to download high resolution image](#)

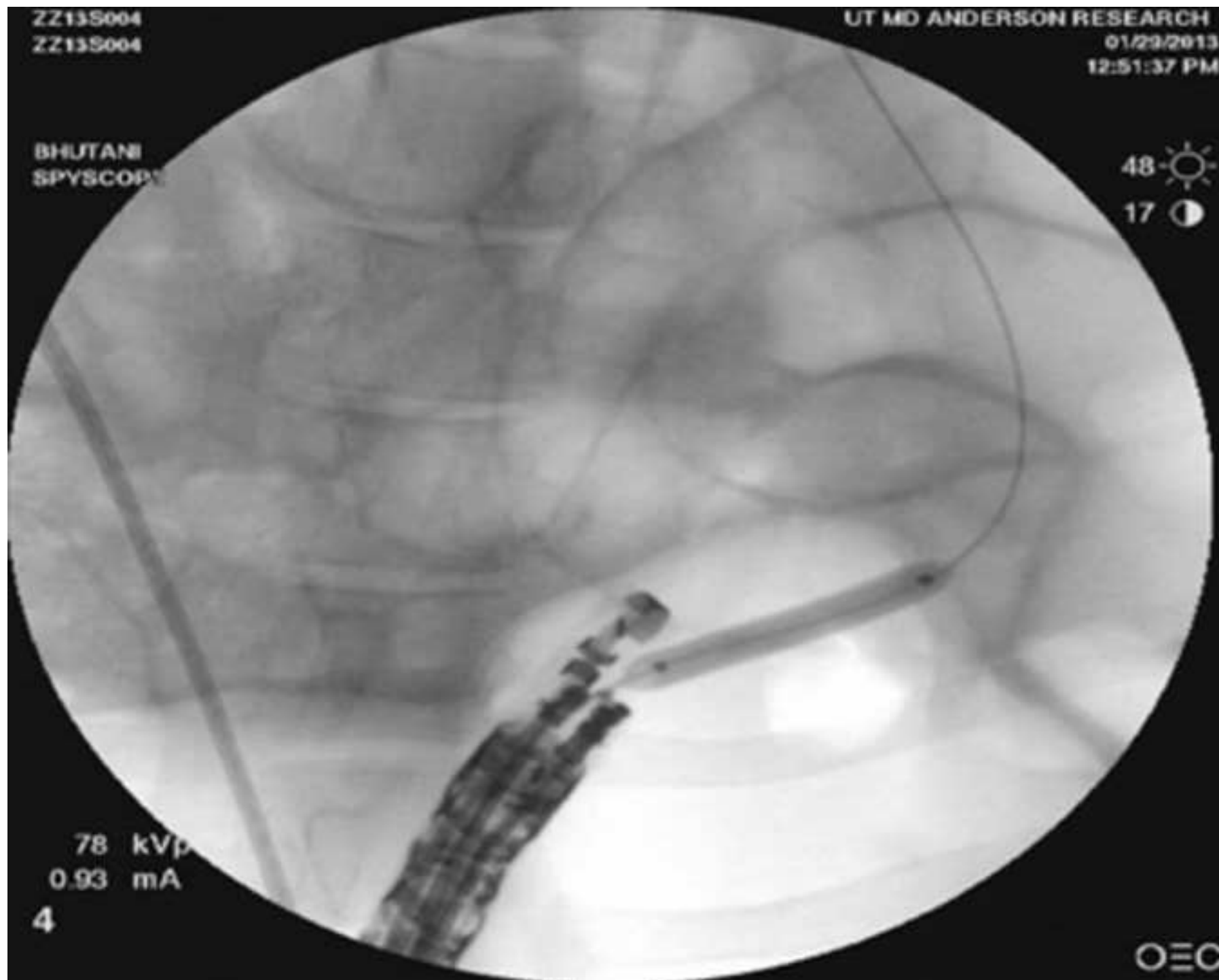


Figure 1E
[Click here to download high resolution image](#)

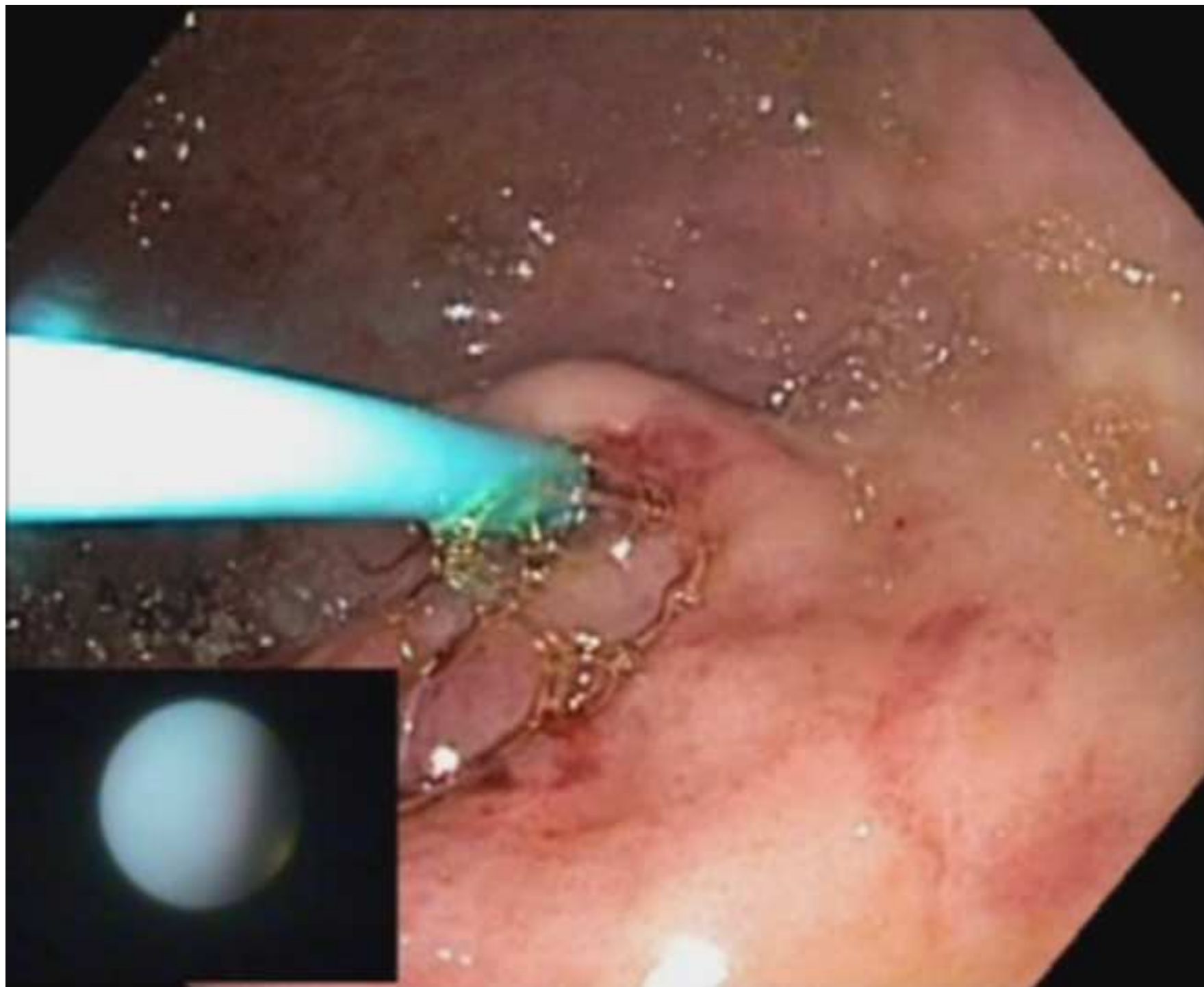

Figure 1F

[Click here to download high resolution image](#)

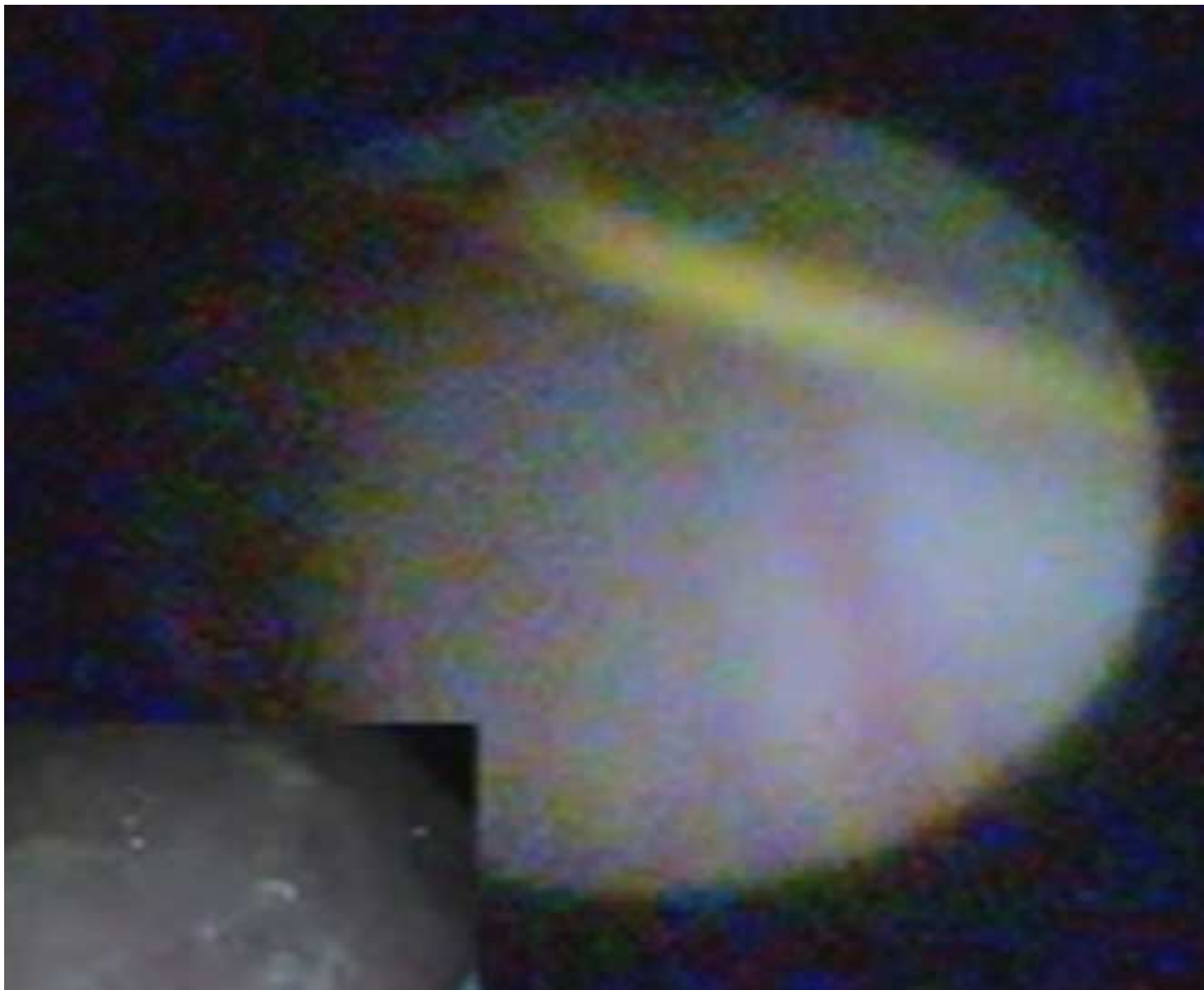


Figure 2
[Click here to download high resolution image](#)

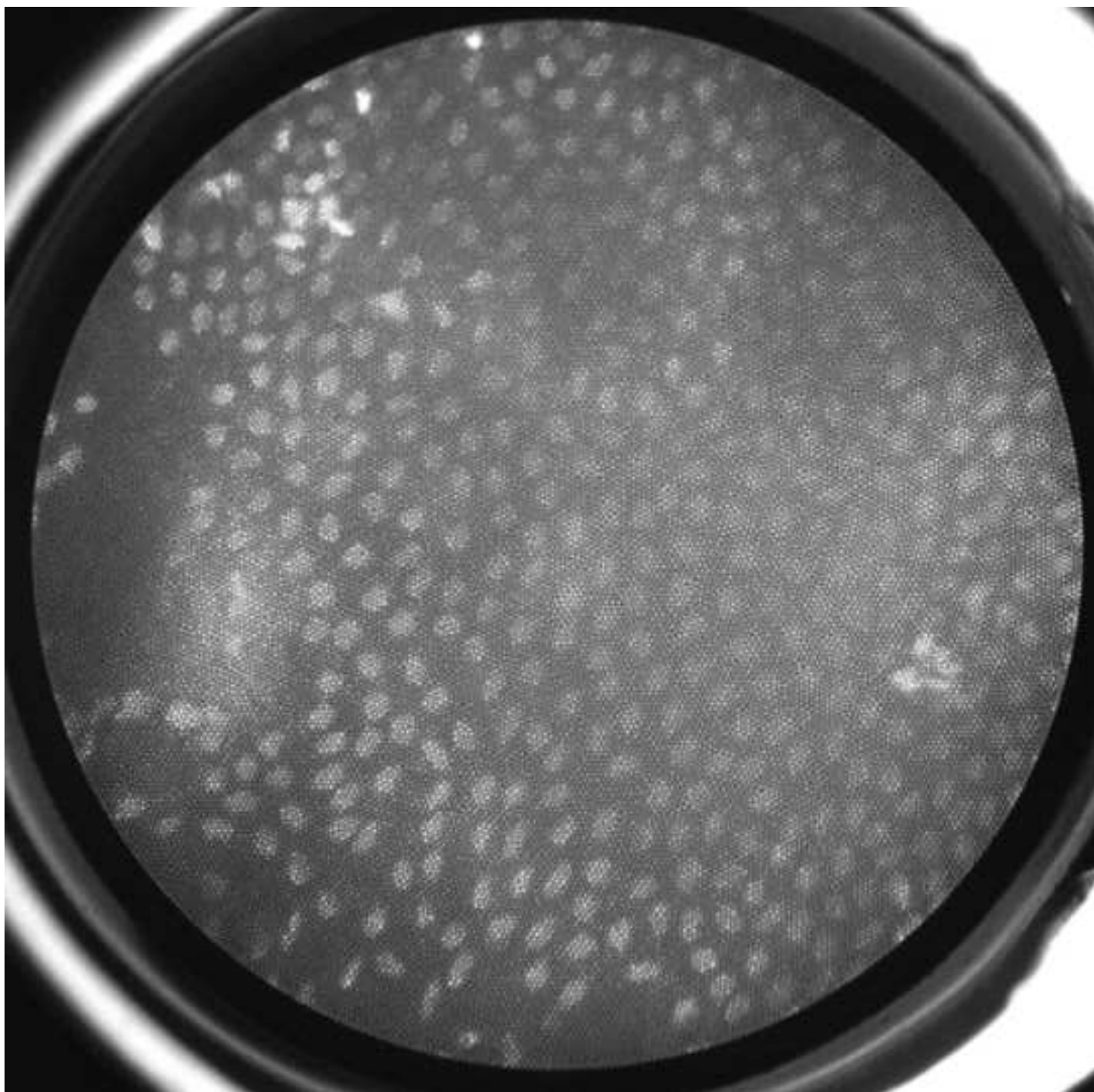


Figure 3
[Click here to download high resolution image](#)

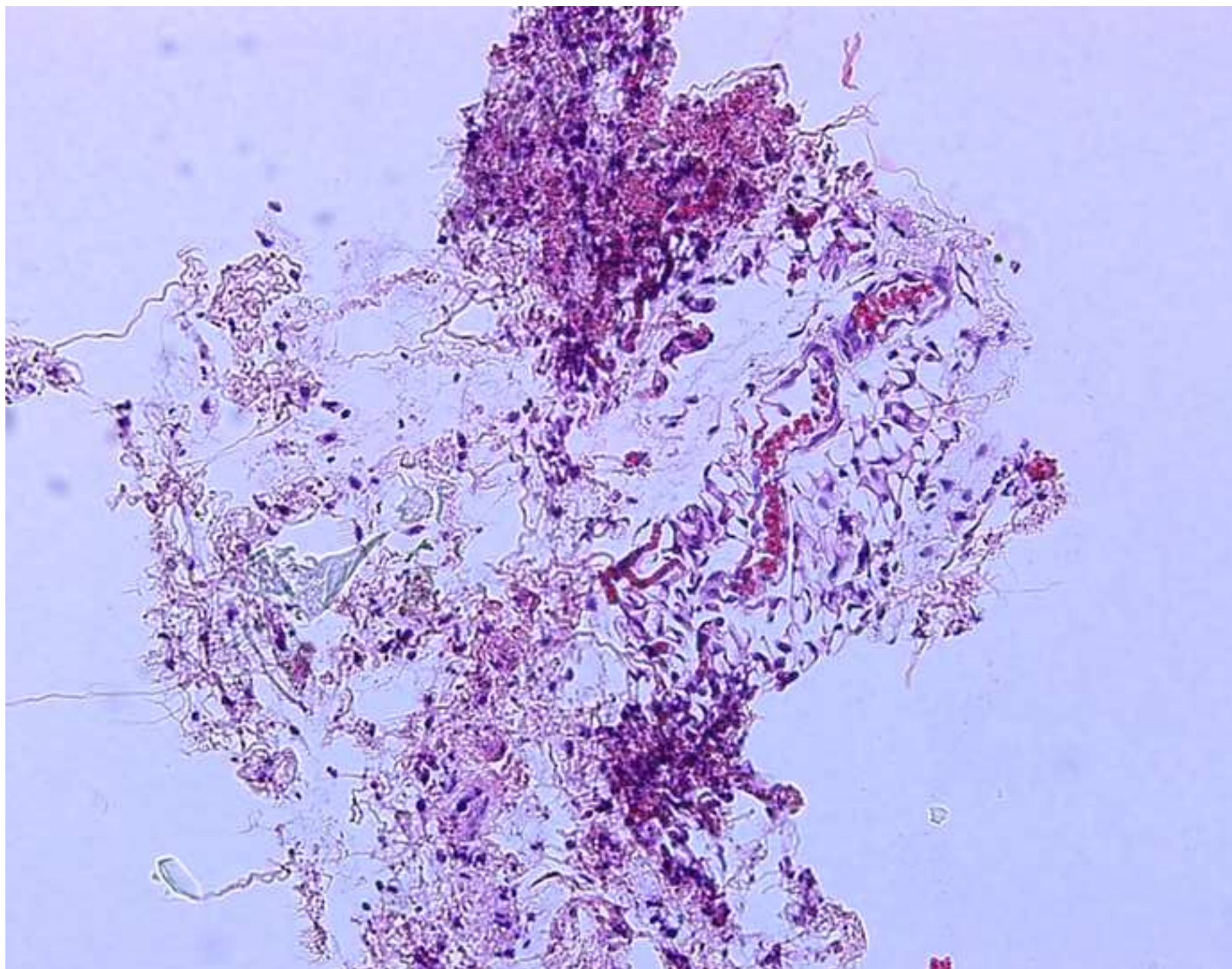


Figure 4A
[Click here to download high resolution image](#)

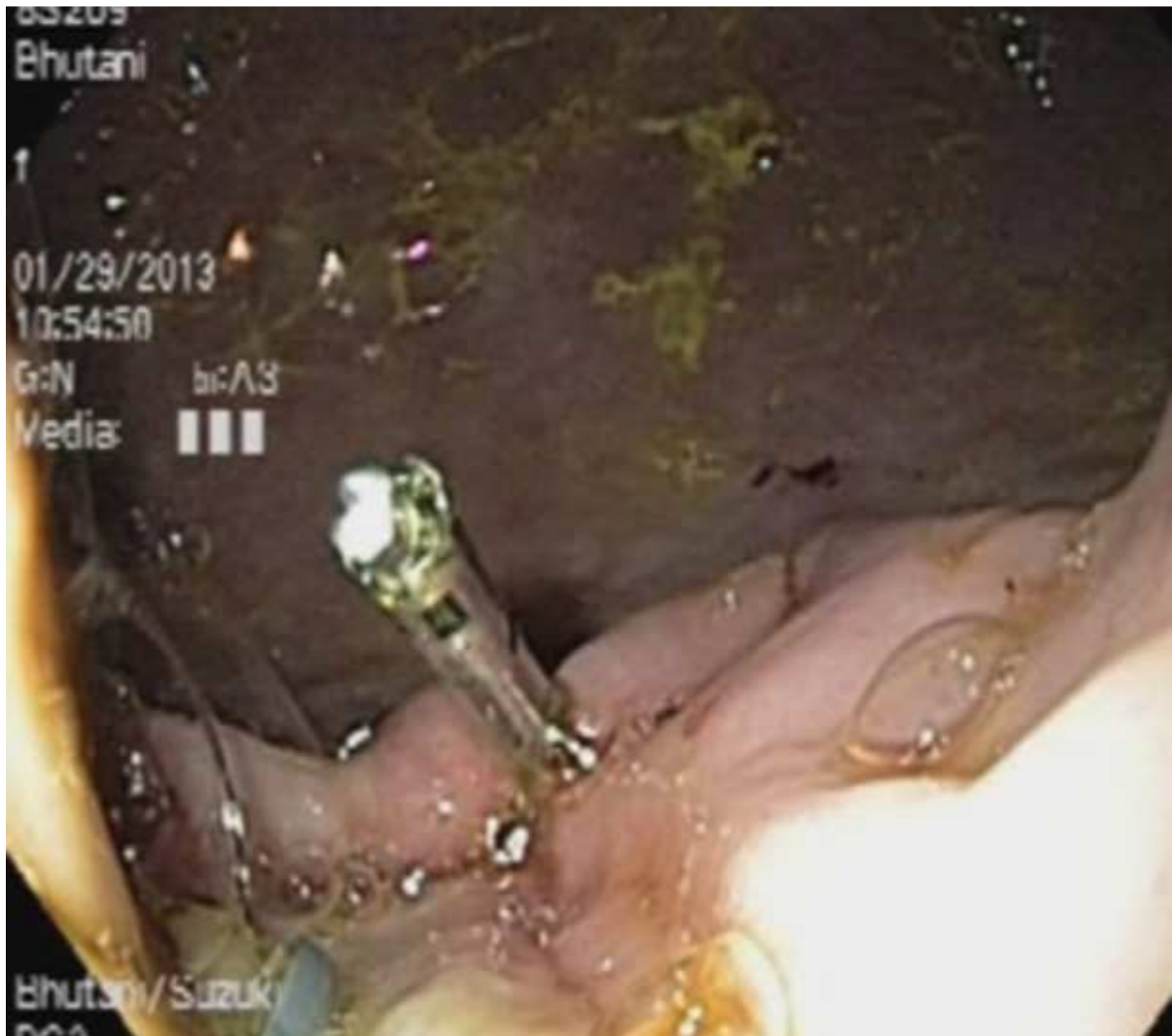

Figure 4B
[Click here to download high resolution image](#)

