Title	Surgical treatment options for septic non-union of the tibia: two staged operation, Flow-through anastomosis of FVFG, and continuous local intraarterial infusion of heparin
Author(s)	Kawakami, Ryoichi; Ejiri, Soichi; Hakozaki, Michiyuki; Hatashita, Satoshi; Sasaki, Nobuyuki; Kobayashi, Yoshitaka; Takahashi, Yoko; Konno, Shin-Ichi
Citation	Fukushima Journal of Medical Science. 62(2): 83-89
Issue Date	2016
URL	http://ir.fmu.ac.jp/dspace/handle/123456789/532
Rights	© 2016 The Fukushima Society of Medical Science
DOI	10.5387/fms.2016-5
Text Version	publisher

Fukushima J. Med. Sci.,
Vol. 62, No. 2, 2016

[Original Article]

Surgical treatment options for septic non-union of the tibia : two staged operation, Flow-through anastomosis of FVFG, and continuous local intraarterial infusion of heparin

Ryoichi Kawakami, Soichi Ejiri, Michiyuki Hakozaki, Satoshi Hatashita, Nobuyuki Sasaki, Yoshitaka Kobayashi, Yoko Takahashi and Shin-ichi Konno

Department of Orthopaedic Surgery, School of Medicine, Fukushima Medical University School of Medicine, Fukushima, Japan

(Received May 12, 2016, accepted June 1, 2016)

Abstract

Background : The treatment of septic non-union of the tibia is a challenging area. The objective of this clinical study was to improve the treatment outcomes in patients with a highly active infection by the three strategies consisting of a two-staged operation, a flow-through technique for vascular anastomosis of a free vascularized fibular graft (FVFG), and continuous local intra-arterial infusion of heparin.

Patients & Method : Five patients with septic non-union of the tibia who were treated with an FVFG (mean age : 52.8 years) were enrolled. The mean postoperative follow-up period was 47.2 months, and the mean length of the bone defect was 111 mm. A two-staged operation, in which polymethylmethacrylate (PMMA) beads containing antibiotics were inserted into a bone defect followed by bone reconstruction performed with an FVFG later. Vascular anastomosis was performed with the flow-through technique in all patients. Immediately after FVFG, heparin was continuously infused through a femoral arterial catheter for 1 week.

Result : Bone union was confirmed an average of 18.8 weeks after-surgery in all patients without reoperation for thrombus.

Conclusion : Our attempt to apply the strategies appears to be a viable treatment option for septic non-union of the tibia.

Key words : FVFG, flow-through anastomosis, septic non-union, tibia, heparin

Introduction

For the treatment of extensive bone defects resulting from septic non-union of the tibia, a free vascularized fibular graft (FVFG)[1-7] has been frequently used and is considered a successful technique. This technique is an excellent therapeutic strategy that allows the surgeon to simultaneously treat extensive bone defects and poor soft tissue conditions, such as scarred skin, fistulae, and skin ulcers due to multiple operations after infection or trauma. However, treatment of septic non-union of the tibia, even with an FVFG, involves issues such as relapse of infection[1-9], difficulty in finding suitable recipient vessels[10], and a high incidence of thrombus formation[7,11-14]. In order to overcome these three issues, we have devised a novel surgical treatment using three strategies to treat septic non-union of the tibia with an FVFG and we have achieved favorable treatment outcomes. Here, we report this treatment along with the details of a representative case.

Materials and Methods

This study included a total of five patients with posttraumatic septic non-union of the tibia was op-

Corresponding author : Ryoichi Kawakami E-mail : ryo-1-k@fmu.ac.jp
https://www.jstage.jst.go.jp/browse/fms http://www.fmu.ac.jp/home/lib/F-igaku/

erated at our hospital between 2005 and 2012. All of patients were treated surgically FVFG technique with flow-through anastomosis. The mean postoperative follow-up period was 47.2 months (ranged, 23 months to 62 months). The patients included four men and one woman, and most of the individuals were aged between 40 and 49 years.

The mean length of the bone defect in the patients was 111 mm (range, 90-130 mm).

All patients with pus exudation from a fistula were diagnosed with active infection, and treatment involving a two-stage strategy was planned. In the first surgery, sequestrum was debrided, and the curetted bone defect was filled with polymethylmethacrylate (PMMA) beads containing antibiotics to which the pathogenic bacteria responsible for the infection were sensitive. As planned, preparations were made after 3 to 6 weeks for transplantation of the FVFG from the healthy limb to the affected lower leg. In all the patients, angiography (two patients) or computed tomography (CT) angiography (three patients) was performed before the second definitive surgery to assess the recipient vessels. Three of the five patients had only one major blood vessel in the lower leg, termed as a "one-artery-leg". In all of the patients, flow-through vascular anastomosis was performed. First, the proximal open ends of the anterior or posterior tibial artery and veins were anastomosed to the fibular artery and veins in an end-to-end fashion. After the proximal ends of the arteries and veins were anastomosed, outflow of blood from the distal end of the fibular artery was confirmed. Thereafter, the distal ends of the fibular artery and veins were anastomosed to the distal ends of the anterior or posterior tibial artery and veins in an end-to-end fashion (Fig. 1).

In all of the patients, large monitoring flaps were prepared to cover soft tissue defects following surgical debridement, and all the vascular anastomotic sites were completely covered with the flaps. For preparing the monitoring flaps in all the patients, the cutaneous perforating branch from the fibular artery was identified, and the intermuscular septum containing the perforating branch between the fibular and soleus muscles was harvested with the tissue graft and the flap over the entire length of the flap. Postoperative monitoring involved observing the appearance of the monitoring flaps.

In the all patients, the following techniques were performed : screw fixation of the FVFG in three patients, fixation of a plate in one patient, and screw fixation of the FVFG using an external fixator in one patient. In all the patients, heparin (5,000 U/day) was continuously injected intra-arterially through a trans-arterial catheter (25 G) to the ipsilateral femoral artery for 1 week (Table 1). We dissolved 5,000 heparin units in 100 milliliters of salines and injected it at 5 ml of speed per hour. We stopped infusion of heparin without tapering. After having passed more than four hours, we remove a catheter. Bone union was assessed based on the

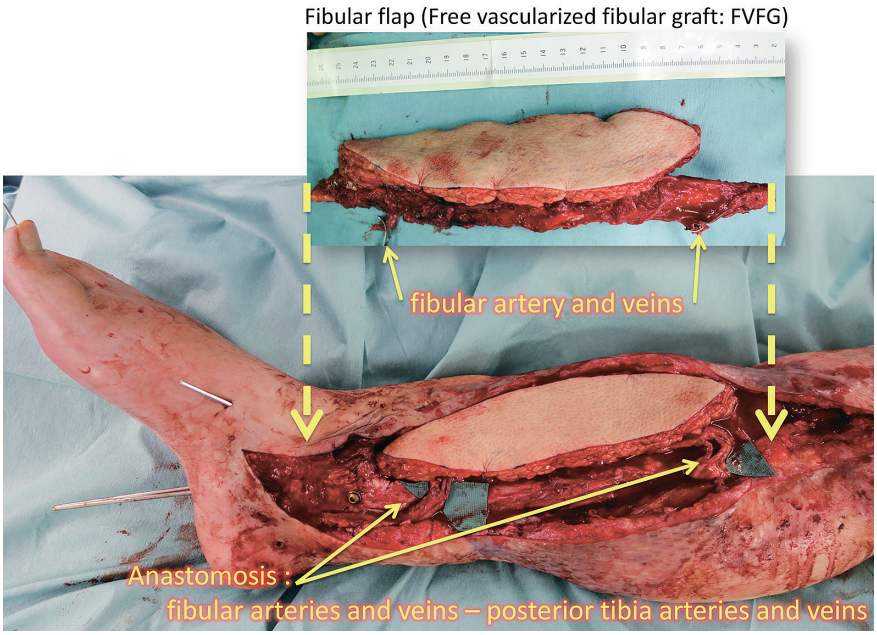

Fig.1. Intraoperative photograph of Case 1. The long pedicle FVFG by flow-through anastomosis was completed. Notably, the surgical field of anastomosis was superficial.

Table 1. Summary of Patients

Case	Age (years/sex)	Bony defect (mm)	Wound Skin	Vascularity : CT angiography	Recipient vessels	flap size (mm)	Bone fixation	Management before FVFG	Complication
1	36/F	96	Extensive Scarring	TP	TP	200×40	plate & screw	PMMA beads (other hospital)	none
2	64/M	112	Discharging sinus Extensive Scarring	TP	TP	250×40	plate & screw temporary EX	PMMA beads VAF flap	none
3	42/M	90	Discharging sinus Extensive Scarring	TP, TA	TP	230×50	plate & screw temporary EX	PMMA beads VAF flap	DM
4	74/M	127	Extensive Scarring	TA	TA	170×40	plate & screw	PMMA beads (other hospital)	DM
5	48/M	130	Extensive Scarring	TP, TA, Pero	TA	160×40	EX	PMMA beads (other hospital)	none

TP, Posterior tibia artery ; TA, Anterior tibia artery ; Pero, Peroneal artery FVFG, free vascularized fibular graft ; EX., external fixator ; PMMA, polymethylmethacrylate ; DM, diabetes mellitus ; VAF flap, Veno-accompanying artery fasciocutaneous flap

following clinical and radiologic criteria[15,17] 1) cortical bridging of at least 3 cortex bone ; 2) bone union of the grafted fibula into the tibia ; 3) stability of the fracture site ; and 4) no pain on gait.

All the procedures followed were in accord with the Standards of the Committee on Human Experimentation of the institution in which the experiments were done or in accord with the Helsinki Declaration of 1975.

Results

We followed up all the patients receiving an FVFG. During the first 2 weeks after FVFG, neither congestion nor ischemia of the monitoring flap was observed in any of the patients, and revision surgery was not needed. Donor site morbidity was observed in two patients. In one of them, split-thickness skin grafting was performed 2 weeks after FVFG, for the skin problem of the donor site (delayed wound healing and skin necrosis). In two patients, resection of the toe flexor tendon was performed 3 months after the FVFG due to mallet toe deformity of donor site. Bone union was confirmed on plain radiographs at an average of 18.8 weeks (range, 16-22 weeks). During the follow-up period, neither stress fracture nor relapse of infection was observed in all of the patients (Table 2).

Report of representative case

Case 1

The patient was a 36-year-old woman without any medical complications. The middle to distal part of her right lower leg was fractured due to a motorcycle accident (Gustillo type 3A). Open reduction and internal fixation were performed at another hospital, and a deep infection of her surgical wounds developed ; the internal fixation of the fracture site was removed. Debridement surgery was performed nine times. Since pus exudation from the fistulas was still noted at 6 months after the removal of the fixation, she was referred to our hospital (Fig. 2a).

Angiography revealed only one patent posterior tibial artery in the affected lower leg (Fig. 2b). A 230-mm FVFG was harvested with a large monitoring flap (200 × 40 mm) from the contralateral lower leg and fixed to the tibia with cortical screws. The

Table 2. Results of free vascularized fibular graft

Cases	Bony union (week)	Post-op. complication	Donor site morbidity	Further management	Observation period (months)
1	16	none	none	none	52
2	17	none	claw toe, delayed heeling	tendon cut, STSG	49
3	18	none	none	none	50
4	22	ankle equinus	claw toe	tendon cut	23
5	21	none	none	none	62

STSG, split thickness skin graft

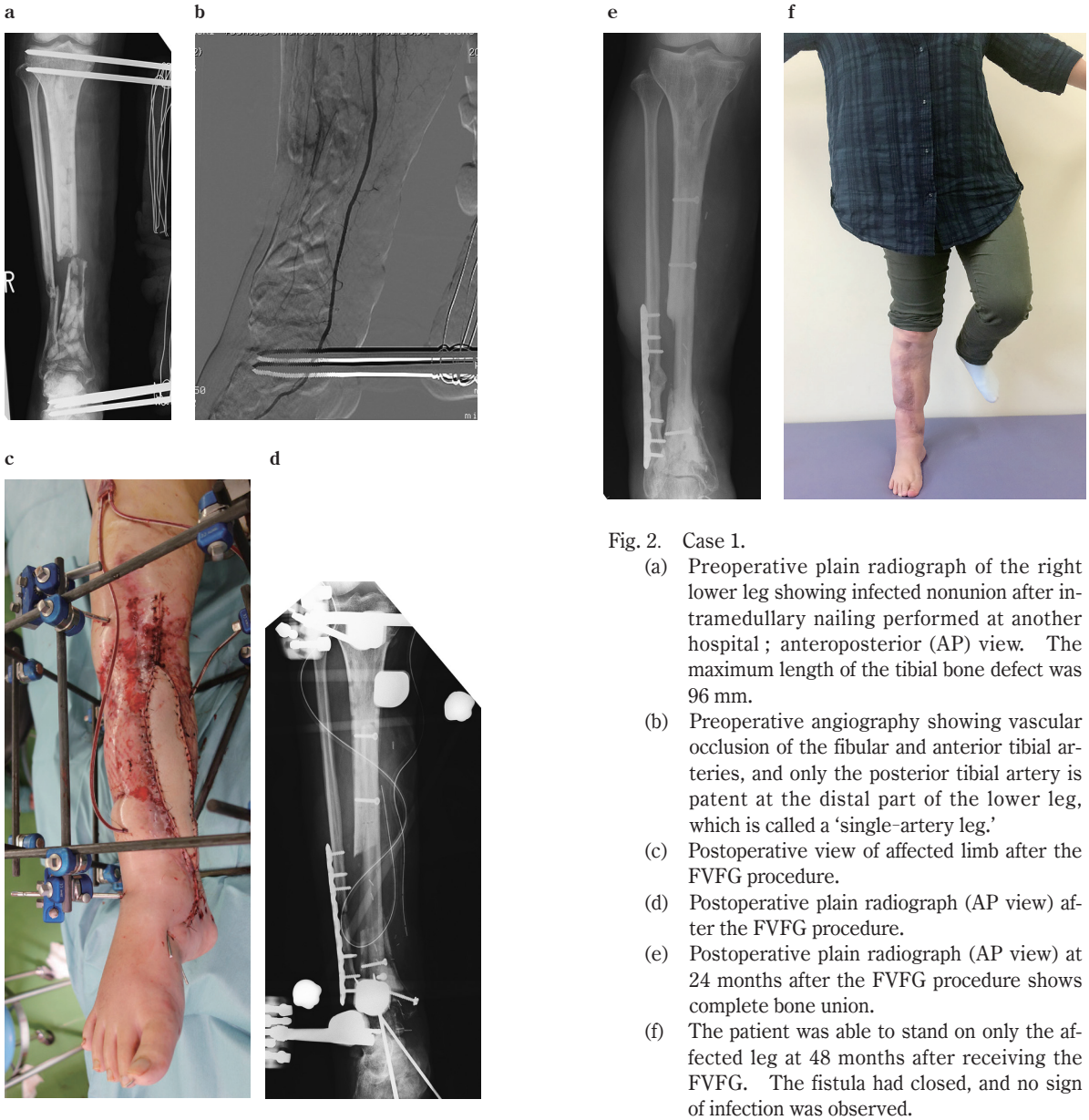

Fig. 2. Case 1.
(a) Preoperative plain radiograph of the right lower leg showing infected nonunion after intramedullary nailing performed at another hospital ; anteroposterior (AP) view. The maximum length of the tibial bone defect was 96 mm.
(b) Preoperative angiography showing vascular occlusion of the fibular and anterior tibial arteries, and only the posterior tibial artery is patent at the distal part of the lower leg, which is called a 'single-artery leg.'
(c) Postoperative view of affected limb after the FVFG procedure.
(d) Postoperative plain radiograph (AP view) after the FVFG procedure.
(e) Postoperative plain radiograph (AP view) at 24 months after the FVFG procedure shows complete bone union.
(f) The patient was able to stand on only the affected leg at 48 months after receiving the FVFG. The fistula had closed, and no sign of infection was observed.

flow-through anastomosis was then performed as described above (Fig. 1). After the surgery, the color of the monitoring flap remained good, and the flap did not show any sign of congestion or ischemia (Fig. 2cd).

The patient started walking with a patella-tendon bearing brace. Because bone union was observed on plain radiographs obtained 4 months after the surgery, the patient was allowed to walk with full weight-bearing. Twenty-four months after the final surgery, plain radiographs revealed complete bone union (Fig. 2e). The patient's function was excellent and she did not complain of pain, and neither stress fracture nor relapse of the infection had been observed at 52 months after the final surgery (Fig. 2f).

Discussion

The lower legs are the most challenging area for tissue grafting with microsurgical techniques[7], because of high relapse rate of infection[1-9], difficulty in finding suitable recipient vessels[10], and a high incidence of thrombus formation[7,11-14]. The approach reported here achieved favorable treatment outcomes by separately dealing with these problems.

First, when an septic non-union accompanied by extensive bone defects is treated, relapse of postoperative infection is inevitable. Previous reports have indicated that the rate of infection relapse rarely reaches 0%[1-9]. It is controversial whether septic non-union should be treated with debridement and

bone/soft tissue reconstruction in one stage or with a two-staged operation. In the two-staged procedure, debridement and soft tissue reconstruction only are first performed simultaneously with the filling of the curetted bone defect with cement beads/blocks that contain antibiotics. Reconstruction of the bone is then performed in the second stage after the sterilization. One review showed that the rate of infection relapse was slightly lower after the two-staged operation[18], and some surgeons actively support this observation[8,19]. However, planning two-staged operations in all patients means that the advantage of FVFG, which allows simultaneous reconstruction of an extensive bone and soft tissue defect in one operation, is not exploited. Thus, we regarded patients with fistulae continuously discharging pus on the lower leg as those who had active infected non-unions and who should be treated by the two-staged operation ; selecting such patients allowed us to better control infection.

Second, for the "one-artery leg", the vessel anastomosis with the end-to-side technique is reported to be clinically superior[20]. However, the problems involved with the end-to-side technique for the lower limb include the presence of damaged vessels due to fibrillization caused by trauma or spreading infection[21,22] and vascular anastomosis at an extremely deep site[10,23]. While scarred or fibrotic tissue is avoided, healthy vessels are searched for in the proximal part in many cases[24]. When the popliteal area is operated on, surgical maneuvers are performed at an extremely deep site. Uncertain vascular anastomosis under a difficult situation may result in thrombus formation. Verhelle *et al*.[10] proposed an approach to overcome these difficulties by using the end-to-side technique with a vein graft. We thought that if patent healthy recipient vessels are identified by preoperative angiography or CT angiography, and are transected and anastomosed using the flow-through technique, then the surgeon may avoid searching for a recipient vessel with good blood flow during the operation. This would allow vascular anastomosis at a superficial surgical site while avoiding the scarred lesion and simultaneously ensuring adequate blood flow in both the recipient tissue and the affected limb (figure 1). Soutar *et al*.[25] first reported a flow-through flap using a radial forearm flap, followed by a report of clinical cases using an anterolateral thigh flap by Koshima *et al*.[26,27] Since then, the use of a flow-through flap has been a well-known reconstruction technique that allows revascularization and free grafting, and there are many reports of clinical success[28-30]. Regarding the high success rate with the flow-through flap, Koshima *et al*. reported that compared to end-to-side anastomosis, the flow-through flap provides more physiological and increased blood flow[27]. Furthermore, Bullocks *et al*.[31] account for the superiority of a flow-through flap by suggesting that even when the blood flow is occluded in the distal part from the flow-through flap, the flap itself is autoregulated as with an arteriovenous fistula and regulates blood flow in the flap and the affected limb.

Regarding the issue of which technique is superior, the end-to-end or end-to-side technique, it seems that no clear differences in rates of vascular patency have been revealed by either experimental rat models or clinical cases[32-34]. With respect to the flow-through technique, Miyamoto *et al*.[35], using rat models, reported that the rates of vascular patency are slightly higher in the flow-through models than in the end-to-side models.

Meanwhile, there may be conflicting reports stating that transecting healthy vessels to use as recipient vessels and performing multiple anastomoses may compromise the blood flow in the affected limb. However, according to the findings from actual cases of vascular anastomosis, end-to-end anastomosis was easily and successfully performed because of the following reasons : the technique was performed at a superficial surgical site ; the selected vessels were healthy ; and the discrepancy ratios of the vascular diameter were extremely low, ranging from 1 to 1.5. In our approach, because healthy major vessels are transected at the middle portion and used as recipient vessels, adequately long recipient vessels can be obtained for anastomosis to the donor fibular artery and vein (Fig. 1). Although the reconstructed vessels meander, they curve loosely and a surgeon can freely position them ; in the present study, no kinking of the vessels was observed. To our knowledge, flow-through anastomosis of FVFG has only been reported a short pedicle reconstruction of tibia case[36] and a jaw reconstruction case[37]. We were unable to find any report of reconstruction of major vessels in the lower leg by using FVFG with long pedicles from the fibular artery and vein, as was attempted here.

Third, the success rate of free grafting to the lower leg is lower than that of grafting to other parts because the rate of thrombus formation after grafting is high due to various reasons[7,11-13,22,38]. Originally, adjuvant therapy with heparin infusion from an implanted arterial catheter was reported as salvage therapy after thrombus formation in free grafting[39]. In response to this, Saito *et al*. reported continuous

trans-arterial infusion of heparin as adjuvant therapy after resection and reconstruction of malignant tumors in the lower leg[40]. We expected that because the lower legs are prone to thrombus formation, better outcomes could be achieved by initiating adjuvant therapy immediately after the operation. According to previous reports, the daily dose of heparin for continuous trans-arterial infusion varies from 2,000 to 10,000 U[40-42], and there is no consensus view. Yajima *et al.*[4] reported results showing that the rates of thrombus formation are higher in patients with septic non-union of lower extremity than in those undergoing reconstruction after tumor resection. Thus, we treated patients with heparin at a daily dose of 5,000 U, which was slightly higher than that described in the report by Saito *et al.*[40] Because thrombus formation, as well as excessive bleeding from the surgical sites, was not observed in this preliminary study, this dose seemed to be adequate, though the sample size was only five.

Conclusion

When five patients with posttraumatic septic non-union of the tibia were treated with an FVFG, we employed three strategies : i) a two-staged operation ; ii) a flow-through anastomosis to conserve blood flow in the major vessels in the lower leg ; and iii) continuous heparin infusion through an implanted arterial catheter. In all patients, the postoperative course was uneventful without any sign of congestion or ischemia, as shown by the monitored flaps, and bone union was achieved. For extensive bone reconstruction using FVFG for patients with septic non-union of the tibia, our approach is a viable treatment option.

Funding : None
Conflicts of interest : None declared

References

1. Taylor GI, Miller GD, Ham FJ. The free vascularized bone graft. A clinical extension of microvascular techniques. Plast Reconstr Surg, **55** : 533-544, 1975.
2. Levin LS. Vascularized fibula graft for the traumatically induced long-bone defect. J Am Acad Orthop Surg, **14** : S175-S176, 2006.
3. Minami A, Usui M, Ogino T, *et al*. Simultaneous reconstruction of bone and skin defects by free fibular graft with a skin flap. Microsurgery, **7** : 38-45, 1986.
4. Yajima H, Kobata Y, Shigematsu K, *et al*. Vascularized fibular grafting in the treatment of methicillin-resistant Staphylococcus aureus osteomyelitis and infected nonunion. J Reconstr Microsurg, **20** : 13-20, 2004.
5. Takami H, Doi T, Takahashi S, *et al*. Reconstruction of a large tibial defect with a free vascularized fibular graft. Arch Orthop Trauma Surg, **102** : 203-205, 1984.
6. Arai K, Toh S, Tsubo K, *et al*. Complications of vascularized fibula graft for reconstruction of long bones. Plast Reconstr Surg, **109** : 2301-2306, 2002.
7. Levin S, Baumeister S. Flaps and Reconstructive Surgery. In : Wei F, Mardini S, editors. Lower extremity. Edinburg : Saunders Elsevier ; 2009. p 63.
8. Dinh P, Hutchinson BK, Zalavras C, *et al*. Reconstruction of osteomyelitis defects. Semin Plast Surg, **23**(2) : 108-118, 2009.
9. Struijs PA, Poolman RW, Bhandari M. Infected nonunion of the long bones. J Orthop Trauma, **21**(7) : 507-511, 2007.
10. Verhelle NA, Heymans O. How to deal with difficult microsurgical end-to-side anastomoses. Microsurgery, **25**(3) : 203-208, 2005.
11. Xipoleas G, Levine E, Silver L, *et al*. A survey of microvascular protocols for lower extremity free tissue transfer II : postoperative care. Ann Plast Surg, **61** : 280-284, 2008.
12. Benacquista T, Kasabian AK, Karp NS. The fate of lower extremities with failed free flaps. Plast Reconstr Surg, **98** : 834-840, 1996.
13. Basheer MH, Wilson SM, Lewis H, *et al*. Microvascular free tissue transfer in reconstruction of the lower limb. J Plast Reconstr Aesthet Surg, **61** : 525-528, 2008.
14. Khouri RK, Shaw WW. Reconstruction of the lower extremity with microvascular free flaps : a 10-year experience with 304 consecutive cases. J Trauma, **29**(8) : 1086-1094, 1989.
15. Trabulsy PP, Kerley SM, Hoffman WY. A prospective study of early soft tissue coverage of grade IIIB tibial fractures. J Trauma, **36** : 661-668, 1994.
16. Keating JF, O'Brien PI, Blachut PA, *et al*. Reamed interlocking intramedullary nailing of open fractures of the tibia. Clin Orthop Relat Res, **338** : 182-191, 1997.
17. Wood MB, Cooney WB 3rd, Irons GB Jr. Skeletal reconstruction by vascularized bone transfer : indications and results. Mayo Clin Proc, **60** : 729-734, 1985.
18. Struijs PA, Poolman RW, Bhandari M. Infected nonunion of the long bones. J Orthop Trauma, **21**(7) : 507-511, 2007. Review.
19. Beris AE, Lykissas MG, Korompilias AV, *et al*.

Vascularized fibula transfer for lower limb reconstruction. Microsurgery, **31**(3) : 205-211, 2011.
20. Godina M, Arnez ZM, Lister GD. Preferential use of the posterior approach to blood vessels of the lower leg in microvascular surgery. Plast Reconstr Surg, **88** : 287-291, 1991.
21. Acland RD. Refinements in lower extremity free flap surgery. Clin Plast Surg, **17** : 733-744, 1990.
22. Culliford AT 4th, Spector J, Blank A, *et al*. The fate of lower extremities with failed free flaps : a single institution's experience over 25 years. Ann Plast Surg, **59**(1) : 18-21, 2007.
23. Amr SM, El-Mofty AO, Amin SN. Anterior versus posterior approach in reconstruction of infected nonunion of the tibia using the vascularized fibular graft : potentialities and limitations. Microsurgery, **22** : 91-107, 2002.
24. McKee NH. Operative complications and the management of intraoperative flow failure. Microsurgery, **14**(3) : 158-161, 1993.
25. Soutar DS, Scheker LR, Tanner NS, *et al*. The radial forearm flap : a versatile method for intra-oral reconstruction. Br J Plast Surg, **36** : 1-8, 1983.
26. Koshima I, Fujitsu M, Ushio S, *et al*. Flow-through anterior thigh flaps with a short pedicle for reconstruction of lower leg and foot defects. Plast Reconstr Surg, **115** : 155-162, 2005.
27. Koshima I, Nanba Y, Tsutsui T, *et al*. New anterolateral thigh perforator flap with a short pedicle for reconstruction of defects in the upper extremities. Ann Plast Surg, **51** : 30-36, 2003.
28. Kim TG, Kim IK, Kim YH, *et al*. Reconstruction of lower extremity complex wounds with combined free tissue transfer using the anterolateral thigh flap as a link. Microsurgery, **32** : 575-579, 2012.
29. Wong CH, Ong YS, Wei FC. The anterolateral thigh — Vastus lateralis conjoint flap for complex defects of the lower limb. J Plast Reconstr Aesthet Surg, **65** : 235-239, 2012.
30. Tseng WS, Chen HC, Hung J, *et al*. "Flow-through" type free flap for revascularization and simultaneous coverage of a nearly complete amputation of the foot : case report and literature review. J Trauma, **48** : 773-776, 2000.
31. Bullocks J, Naik B, Lee E, *et al*. Flow-through flaps : a review of current knowledge and a novel classification system. Microsurgery, **26** : 439-449, 2006.
32. Albertengo JB, Rodriguez A, Buncke HJ, *et al*. A comparative study of flap survival rates in end-to-end and end-to-side microvascular anastomosis. Plast Reconstr Surg, **67**(2) : 194-199, 1981.
33. Frodel JL, Trachy R, Cummings CW. End-to-end and end-to-side microvascular anastomoses : a comparative study. Microsurgery, **7**(3) : 117-123, 1986.
34. Dotson RJ, Bishop AT, Wood MB, *et al*. End-to-end versus end-to-side arterial anastomosis patency in microvascular surgery.
35. Miyamoto S, Okazaki M, Ohura N, *et al*. Comparative study of different combinations of microvascular anastomoses in a rat model : end-to-end, end-to-side, and flow-through anastomosis. Plast Reconstr Surg, **122** : 449-455, 2008.
36. Miyamoto S, Kayano S, Umezawa H *et al*. Flow-through fibula flap using soleus branch as distal runoff : a case report. Microsurgery, **33** : 60-62, 2013.
37. Nişanci M, Selçuk I, Duman H. Flow-through use of the osteomusculocutaneous free fibular flap. Ann Plast Surg, **48** : 435-438, 2002.
38. Hidalgo DA, Disa JJ, Cordeiro PG, *et al*. A review of 716 consecutive free flaps for oncologic surgical defects : refinement in donor-site selection and technique. Plast Reconstr Surg, **102** : 722-732, 1998.
39. May JW Jr, Rothkopf DM. Salvage of a failing microvascular free muscle flap by direct continuous intravascular infusion of heparin : a case report. Plast Reconstr Surg, **83**(6) : 1045-1048, 1989.
40. Saito A, Sawaizumi M, Imai T, *et al*. Continuous local intraarterial infusion of anticoagulants for microvascular free tissue transfer in primary reconstruction of the lower limb following resection of sarcoma. Microsurgery, **30** : 376-379, 2010.
41. Fukui A, Maeda M, Sempuku T, *et al*. Continuous local intra-arterial infusion of anticoagulants for digit replantation and treatment of damaged arteries. J Reconstr Microsurg, **5**(2) : 127-136, 1989.
42. Maeda M, Fukui A, Tamai S, *et al*. Continuous local intra-arterial infusion of antithrombotic agents for replantation (comparison with intravenous infusion). Br J Plast Surg, **44**(7) : 520-525, 1991.