Title	Surgical treatment for infected long bone defects after limb-threatening trauma: application of locked plate and autogenous cancellous bone graft
Author(s)	Kawakami, Ryoichi; Konno, Shin-Ichi; Ejiri, Soichi; Hatashita, Satoshi
Citation	Fukushima Journal of Medical Science. 61(2): 141-148
Issue Date	2015
URL	http://ir.fmu.ac.jp/dspace/handle/123456789/492
Rights	© 2015 The Fukushima Society of Medical Science
DOI	10.5387/fms.2015-17
Text Version	publisher

Fukushima J. Med. Sci.,
Vol. 61, No. 2, 2015

[Original Article]

SURGICAL TREATMENT FOR INFECTED LONG BONE DEFECTS AFTER LIMB-THREATENING TRAUMA : APPLICATION OF LOCKED PLATE AND AUTOGENOUS CANCELLOUS BONE GRAFT

RYOICHI KAWAKAMI, SHIN-ICHI KONNO, SOICHI EJIRI and SATOSHI HATASHITA

Department of orthopaediac surgery, Fukushima Medical University School of Medicine, Fukushima, Japan

(Received June 30, 2015, accepted August 3, 2015)

Abstract

Background : Treatment strategies for bone defects include free bone grafting, distraction osteogenesis, and vascularized bone grafting. Because bone defect morphology is often irregular, selecting treatment strategies may be difficult. With the Masquelet technique, a fracture site is bridged and fixed with a locking plate after treating deep infection with antibiotic-containing cement, and a free cancellous bone-graft is concomitantly placed into the defects. This procedure avoids excessive bone resection.

Methods : We studied 6 patients who underwent surgical treatment for deep infection occurring after extremity trauma (2004 through 2009). Ages at surgery ranged from 29 to 59 years (largest age group : 30 s). Mean follow-up was 50.7 months (minimum/maximum : 36/72 months). One patient had complete amputation of the upper extremity, 3 open forearm fractures, 1 closed supracondylar femur fracture, and 1 open tibia fracture.

In all patients, bone defects were filled with antibiotic-containing cement beads after infected site debridement. If bacterial culture of infected sites during curettage was positive, surgery was repeated to refill bone defects with antibiotic-containing cement beads. After confirmation of negative bacterial culture, osteosynthesis was performed, in which bone defects were bridged and fixed with locking plates. Concomitantly, crushed cancellous bone grafts harvested from the autogenous ilium was placed in the bone defects.

Results : Time from bone grafting and plate fixation to bone union was at least 3 and at most 6 months, 4 months on average. Infection relapsed in one patient with methicillin-resistant *Staphylococcus aureus*, necessitating vascularized fibular grafting which achieved bone union. No patients showed implant loosening or breakage or infection relapse after the last surgery during follow-up.

Conclusion : The advantage of cancellous bone grafting include applicability to relatively large bone defects, simple surgical procedure, bone graft adjustability to bone defect morphology, rapid bone graft revascularization resulting in high resistance to infection, and excellent osteogenesis.

Key words : infected bone, reconstruction, Masquelet technique, trauma

INTRODUCTION

In cases complicated by deep infection after limb-threatening injury, a bone defect may occur as a result of debridement. Operative procedures often adopted for such bone defects are free cortical/cancellous bone grafting in cases with a narrow defect, free vascularized bone grafting if the defect is segmental, affecting a range of 50 mm or more, and lengthening by callus destruction in cases with bone defects of intermediate sizes (20-50 mm)[1-7]. According to previous reports, the time needed for

Corresponding author : Ryoichi Kawakami E-mail : ryo-1-k@fmu.ac.jp
https://www.jstage.jst.go.jp/browse/fms http://www.fmu.ac.jp/home/lib/F-igaku/

bone union after treatment of deep infection accompanied by defects of long bones of the extremities is 6-10 months after vascularized fibular grafting[1,2], about 5 months after callus lengthening[3,4], and 7-10 months after free bone grafting[5,6,8]. However, when vascularized bone grafting or lengthening by callus destruction is planned, it is not common for surgeons to encounter difficulty in selecting the optimal method of bone grafting because such bone defects are morphologically diverse[1,3,6]. If the fractured area is bridged and fixed with a locking plate and free cancellous bone is grafted into the space, it may be possible to achieve firm and flexible fixation and thereby good reconstruction of the bone defect.

With the Masquelet technique[9], a fracture site is bridged and fixed with a locking plate after treating deep infection with antibiotic-containing cement, and a free cancellous bone-graft is concomitantly placed into the bone defect. And fix with a locking plate, the fracture site has with angler stability, and fixed strength increases. This procedure avoids excessive bone resection.

In 6 cases with bone defects (20-80 mm) due to deep infection secondary to injury of the extremities, we carried out grafting of crushed free cancellous bone into the irregularly-shaped bone defects by employing a locking plate. We present the results of this treatment method.

PATIENTS AND METHODS

This study involved 6 patients undergoing surgery between 2004 and 2009 for deep infections which developed after surgical treatment of extremity injuries. Ages at the time of surgery ranged from 29 to 59 years. The mean follow-up period was 50.7 months (range, 36-72 months).

The extremity injuries included complete upper arm amputation (1 case), open forearm fracture (Gustilo type IIIB) (3 cases), closed femoral supracondylar fracture (1 case), and open fracture of the tibia (Gustilo type IIIB) (1 case) (Table 1).

The diagnosis of deep infection was based on local signs of infection at the injured site, histopathological tests of resected bone tissue, and bacterial culture. In all cases, debridement of the infected area was carried out, and the bone defect was filled with cement beads containing antimicrobial drugs. In all 6 cases, preoperative X-rays revealed loosening of the internal fixation materials during the first operation, and this loosening was confirmed during debridement. In 4 cases, external fixation was additionally applied after debridement. If bacterial culture of tissue obtained from the infected area during curettage was positive, the bone defect was again filled with cement beads containing antimicrobial drugs. Bone reconstruction surgery was carried out after a few weeks (mean : 2.5 weeks) confirming that the bacterial culture of the infected area had become negative once. For the operation, we employed a locking plate for the bone defect and performed fixation with a bridging plate technique. Subsequently, grafting of crushed cancellous bone, obtained from the patient's own iliac bone, was carried out.

During this study, the following were investigated and/or analyzed : (1) initial treatment, (2) form and length of the bone defect (we measured maximum length and the smallest length of bone defect on plain X-rays), (3) pathogen(s) causing infection, (4) duration from final surgery to bone union, (5) complications and additional surgery, and (6) postoperative complication with the implant. Bone union was evaluated on plain X-rays. Assessments were made by 3 experienced orthopedic surgeons not directly involved in management of our cases. If assessments initially differed among these 3 specialists, the time considered by all 3 to be when bone union occurred was adopted for data analysis.

Table 1. Cases

case	Age/Sex	Follow up period (months)	Cause of injury	Site of trauma	Gustilo classification
1	35/male	48	MVA*1	Open forearm fracture	Type IIIB
2	49/male	36	IA*2	Amputation of upper arm	Amputation
3	59/female	48	IA	Open lower leg fracture	Type IIIB
4	29/male	44	MVA	Open forearm fracture	Type IIIA
5	54/male	56	MVA	Femur fracture	Closed
6	59/male	72	IA	Open forearm fracture	Type IIIB

*1 MVA : motor vehicle accident
*2 IA : industrial accident

RESULTS (Table 2)

1. *Initial treatment*

Surgery was carried out on all 6 patients. The initial operation was intramedullary nailing in 1 case, plate fixation in 2, wire fixation in 2, and external fixation in 1. Soft tissue repair was achieved using a free groin flap, anterolateral thigh flap, or free latissimus dorsi musculocutaneous flap, in 1 case each. In 1 case undergoing complete traumatic amputation of the forearm, replantation was carried out.

2. *Bone defect form*

The bone defect was segmental in 5 cases and non-segmental in 1. Bone defect lengths ranged from 20 to 80 mm. The stump of the bone defect after curettage and sequestrum debridement was irregularly shaped in all cases. Loosening of the internal fixation implants was noted during debridement in all cases.

3. *Pathogen(s) causing infection*

Mixed infection with *E. cloacae* and *P. mirabilis*, *methicillin-resistant S. aureus* (MRSA) infection, mixed infection with *S. capitis* and *A. hydrophila*, mixed infection with *Phialophora* species and *Fusarium* species, infection with *S. epidermidis*, and infection with *S. aureus* were seen in 1 case each.

4. *Duration until bone union*

Except one case of FVFG, the length of time from surgery (bone grafting and plate fixation) to bone union ranged from 3 to 6 months (mean, 4 months). One FVFG case achieved bony union after 4 months from the final surgery. In all cases, bone union was finally confirmed on plain X-ray.

5. *Additional surgery*

The infection relapsed in 1 case (the case with MRSA infection). This patient received a free vascularized fibular grafting, resulting in bone union. A patient with complete upper arm amputation and replantation underwent reconstruction of elbow flexion function (with functioning pedicled latissimus dorsi muscle transfer) and wrist arthrodesis. Mobilization was performed for 1 patient with knee and ankle joint contracture. Of the 2 patients with subcutaneous protrusion of the internal fixation materials, 1 received plate removal and the other underwent K-wire removal. During follow-up after the final surgery, none of our patients showed relapse of infection and caused implant loosening and breakage.

REPRESENTATIVE CASES

Case 1

A 35-year-old man with an open fracture of the left forearm (Gustilo Type IIIB). This patient was in a traffic accident while driving a car. He was thrown out from the car and sustained injury. On the day of the injury, wound debridement and temporary fixation of the fractured site with K-wire were performed (Fig. 1-a, b).

One week later, plate fixation of the fractured site and closure of the open fracture with a free groin

Table 2. Details of the cases

Case	Initial treatment	Bone defect type/length	Identified bacteria	Period of deep infection	Times of debridement surgery	Period to Bone uion	Complications (after bone graft)	Additional surgery	Complication of LCP*1
1	Plate fix. Free groin flap	Segmental 35-65 mm	S. capitis A. hydrophila	5 months	2	3 months	Addhasion of extensors	Tenolysis	None
2	Plate fix. Replantation	Segmental 35 mm	E. cloacae P. mirabilis	3 months	2	3 months	None	Functional LD*2 taransfer Arthrodesis of wrist	None
3	Extanal fixation Free LD*2 flap	Segmental 20-40 mm	S. epidermidis	3 months	2	4 months	Discomfort of subcutaneous wire	Wire removal	None
4	Extanal fixation Plate fixation	Segmental 20-40 mm	MRSA	8 months	5	6 months	Infection (after bone graft)	FVFG*3	None
5	Intramedurary nail (other hospital)	Non segmental 25-80 mm	S. aureus	2 years	1	4 months	Discomfort of subcutaneous LCP	Plate removal	Discomfort
6	Pinning Free ALT*4 flap	Segmental 21-30 mm	Phialophora fusarium	4 months	2	3 months	Addhasion of extensors	Tenolysis	None

*1 LCP : locking plate, *2 LD : latissimus dorsi, *3 FVFG : Free Vascularized Fibular Graft, *4 ALT : Antero Lateral Thigh

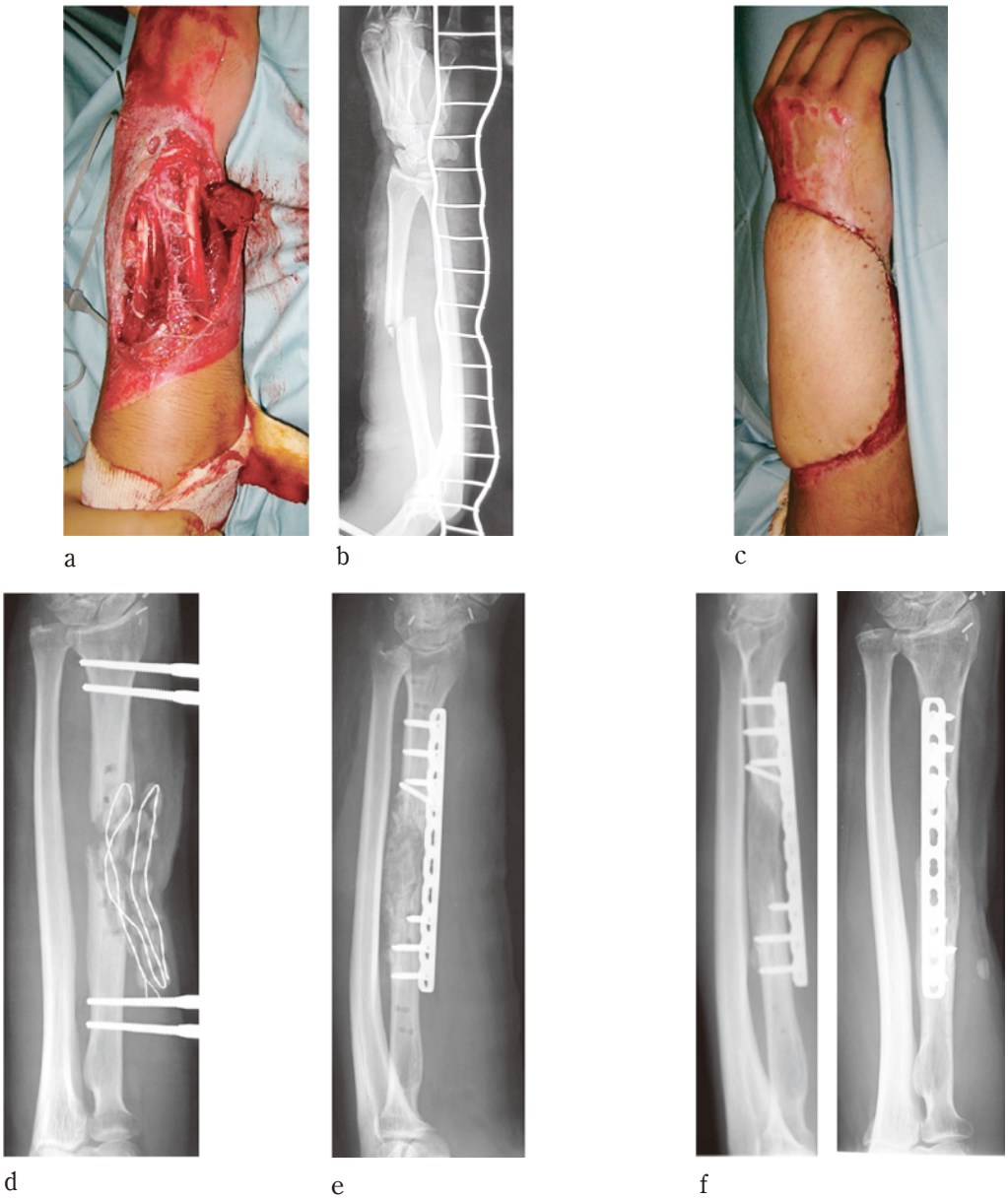

Fig. 1. case 1. 35 yesrs old male, open forearm fracture.
a : 1st. day of injury, Gustilo classification type IIIB.
Debridement and repair of extensor was performed.
b : 1st. day of inury, plane X ray film.
c : 1 week after injury, free groin flap was performed.
d : 1 month after injury, we diagnognosed deep infection.
Loosened plate was removed, and dead space was filled with cement beads containing antimicrobial drugs.
e : 5th. months after injury, bone defect range was 35-65 mm.
Bridging plate fixation and cancellous bone grafting was performed.
f : 2 years after injury, bony union was achived.

flap were performed (Fig. 1-c). One month after the injury, deep wound infection was diagnosed. At that time, the screws inserted during the first operation was also discovered to have loosened. The screws was thus removed, followed by debridement of the fractured site, filling with cement beads containing antimicrobial drugs, and external fixation (Fig. 1-d). The session of curettage and exchange of cement beads containing antimicrobial drugs was repeated twice, and the final bone defect size was 35-65 mm. Five months after the injury, internal fixation with a locking plate and autologous cancellous bone grafting were performed (Fig. 1-e). Bone union was confirmed 3 months after surgery. Plain

X-rays taken at 48 months after the injury showed bone union to be well maintained (Fig. 1-f).

Case 2

A 48-year-old man with complete traumatic upper arm amputation.

The patient had been caught in a chicken feces stirrer, resulting in complete amputation of his upper arm (Fig. 2-a). The amputated arm was replanted the same day. Deep infection developed 1 month after the injury. For this reason, plate removal and filling with cement beads containing antimicrobial drugs were carried out. External fixation was simultaneously performed (Fig. 2-b). At 3 months postoperatively, after 2 sessions of curettage, the bone defect was segmental and 35 mm in length. At that time, bridging plate fixation with a locking plate and autologous cancellous bone grafting were carried out. Six months after surgery (3 months after cancellous bone grafting), bone union was judged to have been achieved (Fig. 2-c, d). Two weeks later, elbow flexion function was reconstructed with functioning pedicled latissimus dorsi muscle transfer. Six months after surgery, the patient was able to use the hand of the affected arm for auxiliary functions. Protective sensation of the palm was restored (Chen's criteria III) (Fig. 2-e).

Case 3

A 56-year-old woman presented with an open fracture of the lower leg. Her leg had been caught in the blades of a power cultivator, resulting in the fracture (Fig. 3-a). On the day of this injury, the blades were removed, and the injured area was filled with cement beads containing antimicrobial drugs. External fixation was simultaneously performed. Later, the soft tissue of the lower leg gradually necrotized.

Six weeks after the injury, the site was again filled with cement beads containing antimicrobial drugs (Fig. 3-b), accompanied by free latissimus dorsi musculocutaneous flap grafting and removal of the loosened device for external fixation (Fig. 3-c). Two months after the injury, the final bone defect was 20-40 mm (segmental). bridging plate fixation with a locking plate and autologous cancellous bone grafting were performed (Fig. 3-d). Bone union was confirmed 4 months after bone grafting. Four months after surgery, the patient had regained the abilities to walk unassisted and do farm work (Fig. 3-d, e). 2 years after injury, bony union was achieved well (Fig. 3f).

DISCUSSION

Requirements which would ideally be satisfied in patients undergoing bone grafting are reported to be as follows[10,11] :

1. Presence of blood circulation through the recipient site ;
2. The recipient site is in contact with the bone graft plane, allowing bone conduction ;
3. Firm fixation of the bone graft ;
4. Bone graft placement within infection-free

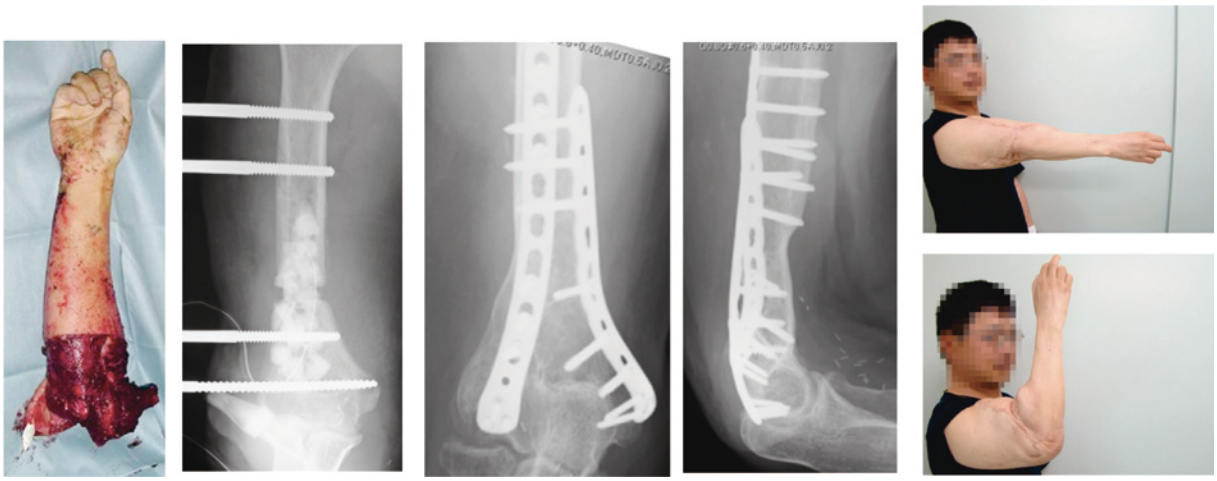

Fig. 2. case 2. 48 years old, male Amputation of upper arm.
a : 1st. day of injury, replantation was performed.
b : one month after injury, we diagnognosed deep infection.
Loosened plate was removed, and dead space was filled with cement beads containing antimicrobial drugs.
c, d : 6 months after injury (4 months after plate fixation and bone grafting).
e : 3 years after injury.

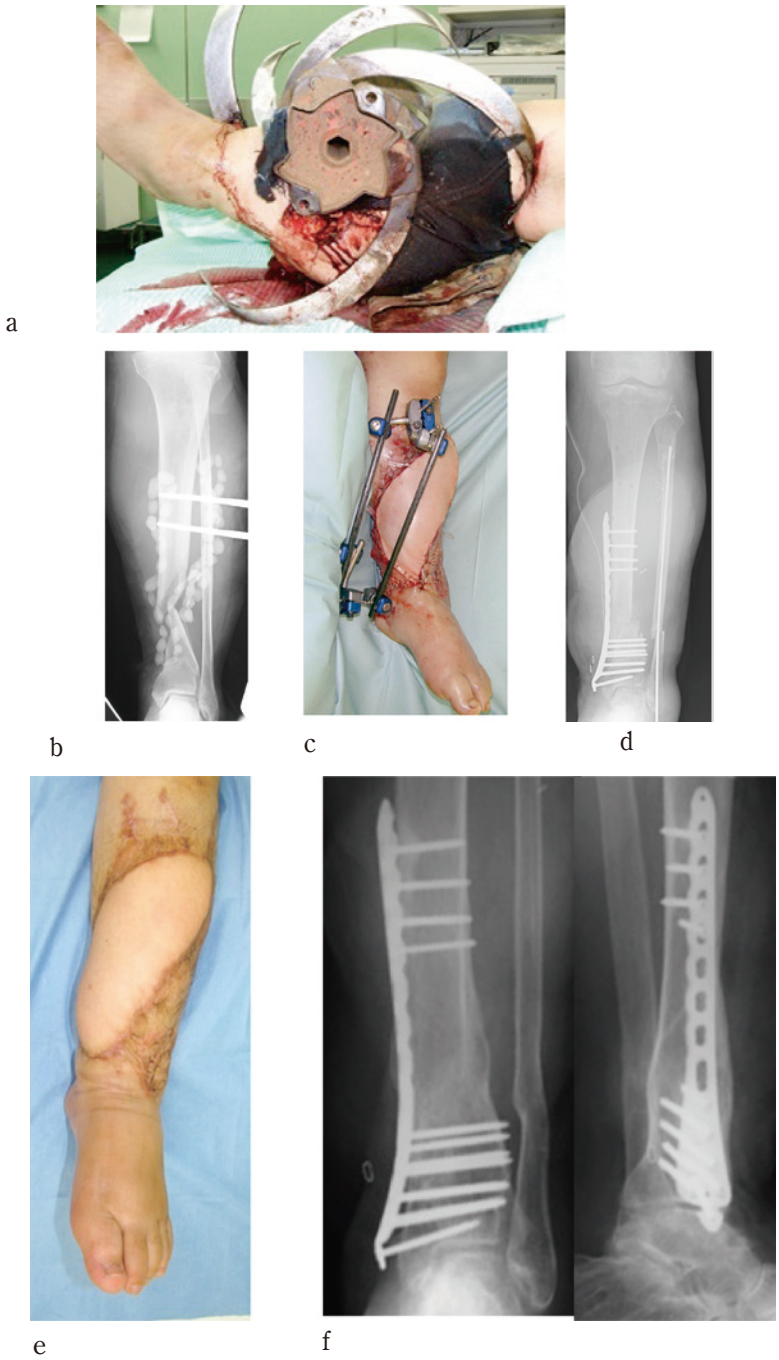

Fig. 3. case 3. 56 years old female, Open fracture of lower leg.
a : 1st. day of injury, A blade of rotary tiller penetrated her lower leg.
b : 2 weeks after injury.
c : 6 weeks after injury, free latismus dorsi MC flap was performed.
d : 2 months after injury, bridging plate fixation and cancellous bone grafting was performed.
e : 2 years after injury.
f : 2 years after injury, bony union was achieved.

tissue ; and

5. Adequate care to ensure preservation of viable cells during surgery.

When bone defects arising from deep infection secondary to extremity injuries are treated, the following measures are essential : (1) curettage of the lesion and stabilization of the infection to achieve bone union, (2) reconstruction of soft tissue and firm fixation with a bridging plate technique, and (3) bone grafting into the bone defect. In all 6 of our present

cases, the bone defect after curettage of the lesion was at least 30 mm in size. In such cases, it reportedly takes 7-10 months to achieve bone union after cancellous bone grafting[5,6,8]. In the present study, our technique was shown to shorten the time needed for bone union to 4 months. If curettage of the lesion is performed while checking blood flow through the bone marrow, the bone stump at the recipient site often assumes an irregular form. If the bone defect has an irregular shape, excessive trimming of the bone stump is unavoidable when performing vascularized bone graft grafting or callus lengthening. If the bone stump is irregularly shaped in cases with normal soft tissue around the lesion or in those who have undergone soft tissue reconstruction, like our present cases, cancellous bone grafting makes excessive bone resection unnecessary and simplifies the operation. We believe that cancellous bone grafting is indicated in such cases.

When treatment involves crushed cancellous bone grafting, according to one case report, success can be achieved when the segmental bone defect is between 20 mm and 80 mm in length[12]. There is also a report indicating that in cases with extensive segmental bone defects of the tibia and soft tissue damage, treatment is possible with free latissimus dorsi muscle grafting and cancellous bone grafting, without requiring the use of a free vascularized fibula graft[13]. In all of these studies, a conventional type plate was employed. In accordance with these reports, we recently attempted to treat bone defects, accompanied by infection, by means of cancellous bone grafting and fixation with a locking plate.

Cancellous bone grafting is advantageous in that it can be used for relatively extensive bone defects, requires only simple operative manipulations, allows the bone graft to easily be matched to the shape of the bone defect, re-vascularization of the bone graft is rapid, resistance to infection is high, and ossifying potential is high[11]. Its disadvantage is lower strength than cortical bone. Cancellous bone grafting often requires concomitant use of a bridging plate technique. Ring et al used a plate with 9-10 holes and no locking mechanism[12]. We used a locking plate as a bridging plate. The use of a locking plate is advantageous in that it maintains blood flow through the periosteum around the curettage lesion and firmer fixation is achieved than with the conventional plate[14-17]. However, several reports have discussed inappropriate uses of locking plates or cases with cut-out or plate breakage when the plate was used as the proximal segment of the osteoporotic humerus or for the treatment of fractures involving prosthetic joints[18,19]. We performed surgery using the AO system[20] for bridging plate technique with a locking plate in a way that assured relative stabilization of the fractured site, taking care to select a long plate and to avoid using a screw in the vicinity of the bone defect. We believe that these precautions enabled us to successfully employ the locking plate in our patients, none of whom experienced plate breakage. Henceforth, these patients will be followed for longer periods of time.

CONCLUSION

1) We treated deep infection after injury of the extremities in 6 cases.
2) Bone union was achieved in 5 cases by means of internal fixation with a locking plate and cancellous bone grafting into the bone defect (20-80 mm), with the time needed for bone union being as short as 4 months after grafting.
3) With this treatment technique, none of our patients suffered breakage of the locking plate.

We have received no funds for the investigation or treatment of the cases reported herein.

REFERENCE

1. Cavadas PC, Landin L, Ibanez J, Nthumba P. Reconstruction of major traumatic segmental bone defects of the tibia with vascularized bone transfers. Plastic and Reconstructive Surgery, **125** : 215, 2010.
2. Yajima H, Kobata Y, Shigematsu K, Kawamura K, Tamai S, Takakura Y. Vascularized fibular grafting in the treatment of methicillin-resistant staphylococcus aureus osteomyelitis and infected nonunion. J Reconstr Microsurg, **20**(1) : 13-20, 2004.
3. Barbarossa V, Matkovic BR, Vucic N, Bielen M, Gluhinic M. Treatment of osteomyelitis and infected non-union of the femur by a modified ilizarov technique : follow up study. Croat Med J, **42** : 634-641, 2001.
4. Manini L, Chadha M, Vishwanath J, Kapoor S, Mehtani A, Dhaon BK. The ilizarov method in infected nonunion of fractures. Injury, Int. Care Injured, **31** : 509-517, 2000.
5. Chin-en Chen, Jih-Yang Ko, Jun-wen Wang. Infection after intramedullary nailing of the femur. Journal of trauma, **55**(2) : 338-344, 2003.
6. Phillip B Schottle, Clement ML Werner, Charles E Dumont. Two-stage reconstruction with free vascularized soft tissue transfer and conventional bone

graft for infected nonunions of the tibia. Acta Orthopaedica, **76**(6) : 878-883, 2005.
7. Wu CC. Single-stage surgical treatment of infected non union of the distal tibia. J Orthop Trauma, **25**(3) : 156-161, 2011.
8. Nicoll EA. The treatment of gaps in long bones by cancellous insert grafts. J Bone Joint Surg, **38B(1)** : 70-82, 1956.
9. Masquelet AC, Fitoussi F, Beque T, Muller GP. Reconstruction of the long bones by induced membrane and spongy autograft. Ann Chir Plast Esthet, **45**(3) : 346-353, 2000.
10. Cutting CB, McCarthy JG, Knize DK. Repair and grafting bone. Plastic Surgery. 1st. ed. W.B. Saunders Co, Philadelphia ; 617-624, 1990.
11. Harii K, Hata I. Kotuishoku saikinn no shinpo. p. 5-6, Kokuseido. co, 1995.
12. Ring D, Allende C, Jafarnia K, Allende BT, Jupiter JB. Ununited diaphyseal forearm fractures with segmental defects : plate fixation and autogenous cancellous bone-grafting. J bone joint Surg Am, **86** : 2440-2445, 2004.
13. Christian EP, Bosse MJ, Robb G. Reconstruction of large diaphyseal defects, without free fibular transfer, in Grade tibial fractures. J Bone Surg Am, **71** : 994-1004, 1989.
14. Egol KA, Kubiak EK, Fulkerson E, Kummer FJ, Koval KJ. Biomechanics of locked plates and screws. J Orthop Trauma, **18** : 488-493, 2004.
15. Fulkerson E, Egol KA, Kubiak EN, Liporace F, Kummer FJ, Koval KJ. Fixation of diaphyseal fractures with a segmental defect : a biomechanical comparison of locked and conventional plating techniques. J Tauma, **60** : 830-835, 2006.
16. Snow M, Thompson G, Turner PG. A mechanical comparison of the locking compression plate (LCP) and the low contact-dynamic compression plate (DCP) in an osteoporotic bone model. J Orthop Trauma, **22** : 121-125, 2008.
17. Lutz Claues. Biomecanical principles and mechanobiologic aspects of flexible and locked plating. J Orthop Trauma, **25**(2) supplement, 2010.
18. Owsley KC, Gorczyca JT. Displacement/screw cutout after open reduction and locked plate fixation of humeral fractures. J Bone Joint Surg Am, **90** : 233-240, 2008.
19. Strauss EJ, Schwarzkopf R, Kummer F, Egol KA. The current status of locked plating : the good, the bad, and the ugly. J Orthop Trauma, **22** : 479-486, 2008.
20. Rudi TP, Murphy WM. AO hou kossetsu chiryou. p. 170-175, 580-583, Igakushoin, 2003.