Title	Ultrasonographic assessment of the flexor pronator muscles as a dynamic stabilizer of the elbow against valgus force
Author(s)	Otoshi, Kenichi; Kikuchi, Shinichi; Shishido, Hiroaki; Konno, Shinichi
Citation	Fukushima Journal of Medical Science. 60(2): 123-128
Issue Date	2014
URL	http://ir.fmu.ac.jp/dspace/handle/123456789/425
Rights	© 2014 The Fukushima Society of Medical Science
DOI	10.5387/fms.2014-7
Text Version	publisher

Fukushima J. Med. Sci.,
Vol. 60, No. 2, 2014

[Original Article]

ULTRASONOGRAPHIC ASSESSMENT OF THE FLEXOR PRONATOR MUSCLES AS A DYNAMIC STABILIZER OF THE ELBOW AGAINST VALGUS FORCE

KENICHI OTOSHI, SHINICHI KIKUCHI, HIROAKI SHISHIDO and SHINICHI KONNO

Department of Orthopaedic Surgery, Fukushima Medical University School of Medicine

(Received February 6, 2014, accepted June 13, 2014)

Abstract : Flexor pronator muscles (FPMs) play a key role in stabilizing the elbow joint against valgus forces. However, no studies have investigated the in vivo kinematics of FPMs against these forces on the elbow. This study aimed to clarify the in vivo contribution of each FPM as a dynamic stabilizer in a clinical situation.

Twelve healthy volunteers participated in this study. Verbal informed consent was obtained from all subjects. The elbow was flexed to 90 degrees, and the forearm was placed in the neutral position. Manual valgus stress was applied to the elbow joint until maximal shoulder external rotation was achieved. The width of the ulnohumeral joint space and the ulnar shift of the sublime tubercle were measured before and after isometric contraction of FPMs using ultrasonography.

The horizontal distances were decreased 1.1±0.6 mm after forearm pronation, 0.6±0.5 mm after wrist palmar flexion, 0.1±0.4 mm after wrist ulnar flexion, and 0.2±0.5 mm after finger flexion. Significant changes were observed during forearm pronation, wrist palmar flexion, and finger flexion but not during wrist ulnar flexion ($p<0.05$). The sublime tubercle was significantly shifted 0.5±0.1 mm medially after forearm pronation, 0.2±0.1 mm medially after wrist palmar flexion, and 0.1±0.1 mm laterally after wrist ulnar flexion and finger flexion ($p<0.05$). The FPMs, especially the pronator teres and the flexor carpi radialis, function as dynamic stabilizers against elbow valgus stress. The results of this study may be useful in developing injury prevention and rehabilitation strategies for throwing injuries of the elbow.

Key words : Flexor pronator muscles, Ultrasonography, dynamic stabilizer, elbow valgus stress

INTRODUCTION

During the throwing motion, the tensile load on the medial ulnar collateral ligament (MUCL) has been estimated to exceed its failure strength[1,5,14]. These tremendous repetitive valgus forces may lead to failure of the MUCL over time. According to these reports, dynamic muscle contraction of flexor pronator muscles (FPMs) plays a key role in stabilizing the elbow joint against valgus forces. Several anatomical, electromyographic, and cadaveric biomechanical studies have demonstrated the contribution of FPMs against elbow valgus stress[2,3,6-10,12,13]. However, there has been no evidence to suggest that FPMs actually contribute to elbow stability in a clinical situation because no study has yet investigated the in vivo kinematics of the elbow joint where each FPM is contracted actively against elbow valgus forces. The purpose of this study is to clarify the in vivo contribution of each FPM as dynamic stabilizers in a clinical situation using ultrasonography.

MATERIALS AND METHODS

Twelve healthy adult volunteers participated in this study. Informed consent was verbally obtained from all subjects. Their age ranged from 24 to 39 years (mean, 30.1±4.6 years). All subjects were

Corresponding author : Kenichi Otoshi MD, PhD E-mail : kootoshi@fmu.ac.jp
https://www.jstage.jst.go.jp/browse/fms http://www.fmu.ac.jp/home/lib/F-igaku/

Fig. 1. Subjects are placed supine on the table with the elbow in 90 degrees of flexion and the forearm in 90 degrees of supination. Manual elbow valgus stress is applied until the shoulder is in maximal external rotation, taking care not to cause discomfort or pain for the subject.

men in order to mimic the condition of an adult male baseball player. Both elbow joints were examined in this study. None of the subjects had previous injuries or surgeries on the elbow joint. The medial aspect of the elbow was assessed using an ultrasonographic device (HD-11 ; Philips, Andover, MA). Subjects were placed supine on the table with the shoulder in 90 degrees of abduction. The elbow was flexed 90 degrees, and the forearm was in placed in the neutral position (Fig. 1)[11]. A linear transducer (L12-5, 12 MHz) was placed on the medial aspect of the elbow to obtain an image that included the top of the medial epicondyle (MEC), the anterior bundle of MUCL (AOL), and the sublime tubercle (ST) (Fig. 2). The outline of the ulnar collateral ligament was assumed to be a horizontal line, and the ulnohumeral joint space was observed as a non-echoic space between the distal-medial corner of the trochlea and the proximal edge of the ST.

While viewing the ultrasonographic image, the examiner held the subject's hand and applied manual valgus stress to the elbow joint until the shoulder was in maximally external rotation, taking care not to cause discomfort or pain for the subject. While maintaining the valgus stress, the horizontal and vertical distances between the distal-medial corner of the trochlea and the proximal edge of the ST were measured. The horizontal distance indicated the width of the ulnohumeral joint space, and the vertical distance indicated the medial shift of the ST. If the proximal edge of the ST was located medially when compared with the distal-medial corner of the

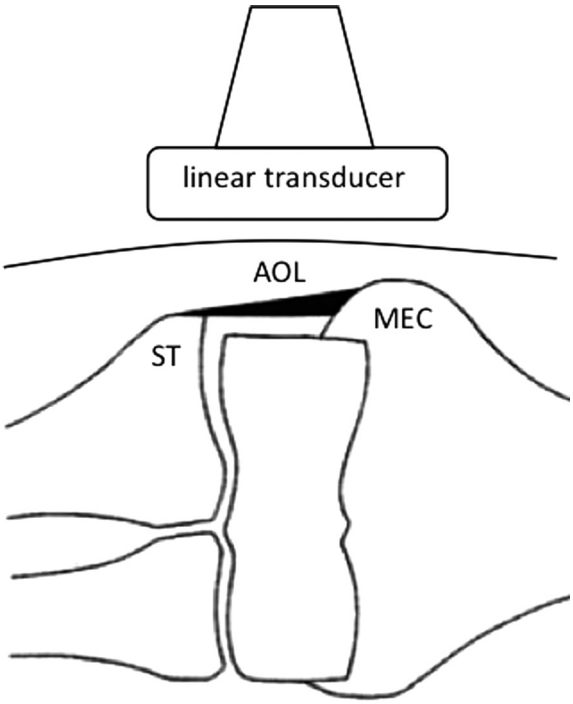

Fig. 2. A linear transducer was placed on the medial aspect of the elbow to obtain an image that included the top of the MEC, AOL, and ST. (MEC : medial epicondyle, AOL : anterior oblique ligament, ST : sublime tubercle)

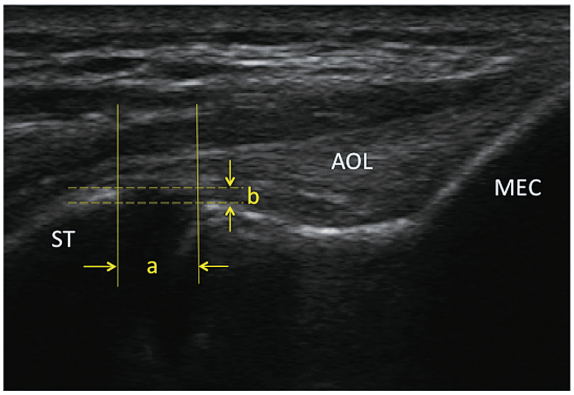

Fig. 3. The top of the MEC, the AOL, and the ST are obtained. The outline of the ulnar collateral ligament is assumed to be a horizontal line. The (a) width and (b) medial deviation of the medial ulnohumeral joint space is examined using ultrasonography before and after isometric contraction of FPMs. (MEC : medial epicondyle, AOL : anterior oblique ligament, ST : sublime tubercle)

trochlea, the vertical distance was expressed as a positive value (Fig. 3). Then, the examiner applied a resistance force on the subject in order to produce isometric contraction of the FPMs. Isometric forearm pronation, wrist palmar flexion, wrist ulnar flexion, and finger flexion were examined with a constant valgus stress to the elbow. The horizontal

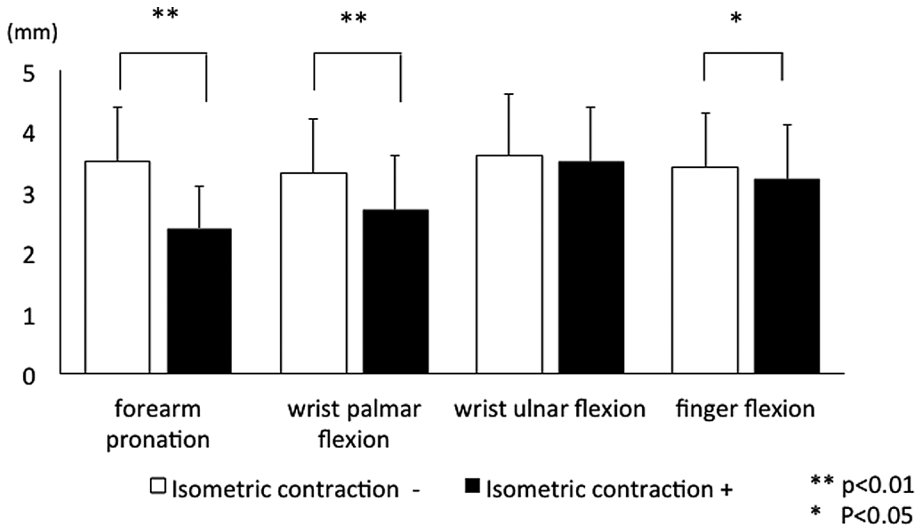

Fig. 4. The horizontal distance is decreased 1.1±0.6 mm after forearm pronation, 0.6±0.5 mm after wrist palmar flexion, 0.1±0.4 mm after wrist ulnar flexion, and 0.2±0.5 mm after finger flexion. The joint space is significantly decreased after isometric contraction of forearm pronation, wrist palmar flexion, and finger flexion.

and vertical distances were measured again, and the changes in the distances before and after isometric contraction of the FPMs were calculated. Each examination was repeated 3 times, and the average value was obtained. The paired *t*-test was used for statistical analysis to evaluate the change of these distances. A *p*-value <0.05 was considered significant. Intra-observer reliability of each measurement was 0.78 to 0.93. The ethical committee of our institute approved this study.

RESULTS

Horizontal distance

The average horizontal distance before isometric contraction of the FPMs was 3.5±0.1 mm. The horizontal distance decreased by 1.1±0.6 mm after forearm pronation, 0.6±0.5 mm after wrist palmar flexion, 0.1±0.4 mm after wrist ulnar flexion, and 0.2±0.5 mm after finger flexion. Significant changes were observed in forearm pronation ($p<0.01$), wrist palmar flexion ($p<0.01$), and finger flexion ($p<0.05$) but not in wrist ulnar flexion (Fig. 4). The percentage of joint space decrease was 29.4%, 15.9%, 0.1%, and 6.4%, respectively (Table 1).

Table 1.

Motion	% of joint space narrowing
Forearm pronation (PT)	29.4%**
Wrist palmar flexion (FCR)	15.9%**
Wrist ulnar flexion (FCU)	0.1%
Finger flexion (FDS)	6.4%*

**$p<0.01$, *$p<0.05$

Vertical distance (the ulnar shift of the ST)

The average vertical distance before isometric contraction of the FPMs was 0.2±0.1 mm. The ST shifted medially after forearm pronation and wrist palmar flexion, whereas it shifted laterally after wrist ulnar flexion and finger flexion. The amount of change was 0.5±0.1 mm after forearm pronation, 0.2±0.1 mm after wrist palmar flexion, 0.1±0.1 mm after wrist ulnar flexion, and 0.1±0.1 mm after finger flexion. Significant changes were observed in all of the maneuvers ($p<0.05$) (Fig. 5).

The change of the ulnohumeral joint space before and after isometric contraction of the FPMs in the typical case was shown in Fig. 6. The width of the ulnohumeral joint space was widened and the sublime tubercle shifted laterally when valgus stress was applied to the elbow without isometric contraction of FPMs. After isometric contraction of the pronator teres (PT), the width of the ulnohumeral joint space was decreased and the sublime tubercle was shifted medially.

DISCUSSION

Several anatomical and cadaveric biomechanical studies have described the importance of FPMs, especially the flexor carpi ulnaris (FCU) and the flexor digitorum superficialis (FDS), for elbow valgus stability[2,8-10,13]. In an anatomical study, Davidson *et al.*[2] stated that the FCU and FDS were the predomi-

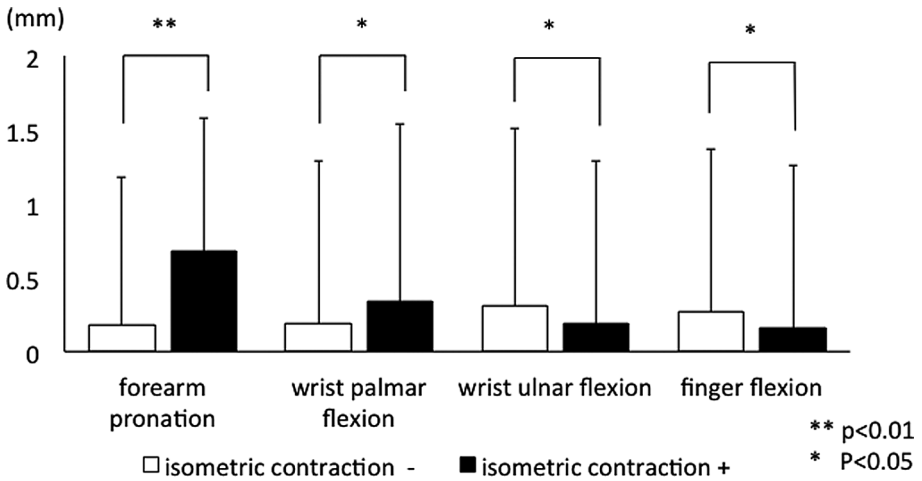

Fig. 5. The sublime tubercle shifts medially after forearm pronation and wrist palmar flexion, whereas it shifts laterally after wrist ulnar flexion and finger flexion. The amount of change is 0.5±0.1 mm after forearm pronation, 0.2±0.1 mm after wrist palmar flexion, 0.1±0.1 mm after wrist ulnar flexion, and 0.1±0.1 mm after finger flexion. Significant changes are observed in all of the maneuvers.

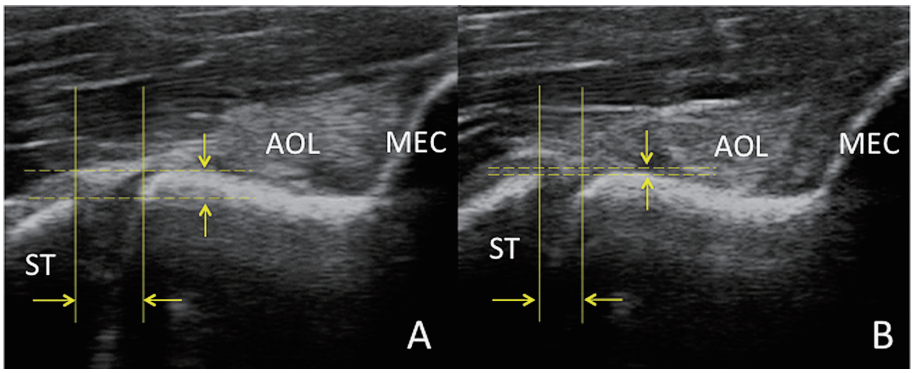

Fig. 6. The change in the ulnohumeral joint space before and after isometric contraction of the FPMs in the typical case is shown in this figure. The width of ulnohumeral joint space is widened and the sublime tubercle shifted laterally under application of valgus stress to the elbow without isometric contraction of FPMs (A). After isometric contraction of PT, the width of the ulnohumeral joint space is decreased and sublime tubercle is shifted medially (B). (MEC : medial epicondyle, AOL : anterior oblique ligament, ST : sublime tubercle)

nant musculotendinous units because of their position directly over the MUCL in the elbow flexion position. Recently, Otoshi *et al.*[9] described that the upper part of the PT ulnar head was attached directly to the medial epicondyle via a thickened joint capsule just anterior to the AOL in all specimens and suggested that muscle activation of the PT directly increases the strain on the medial joint capsule via the humeral branch of the ulnar head.

In a cadaveric biomechanical study, Udall *et al.*[13] reported that the FDS is the biggest contributor among the FPMs, and other biomechanical studies[8,10] demonstrated that the FCU is the primary stabilizer for achieving elbow valgus stability. Several electromyographic studies have shown that the FPMs originating on the MEC, such as the PT, the flexor carpi radialis (FCR), the FDS, and the FCU, demonstrated very high activity during the late cocking and acceleration phases[3,6,7,12]. Glousman *et al.*[6] stated that the PT had decreased activity in pitchers with MUCL insufficiency, and Hamilton *et al.*[7] reported that there was an increase in activation of the extensor supinator muscles and a decrease in FPM activation in injured pitchers during the acceleration phase.

The maximum valgus force is applied across the elbow during the cocking and acceleration phases of throwing, with peak force generated immediately before ball release[4]. During the acceleration phase, the forearm is gradually pronated, and the wrist and finger flexors are in eccentric contraction. These results suggested that the forearm pronators, wrist flexors, and finger flexors might stabilize the elbow against valgus forces, especially at the ball re-

lease. Our dynamic ultrasonographic study demonstrated that the medial ulnohumeral joint space was significantly reduced by isometric forearm pronation, wrist palmar flexion, and finger flexion, whereas there was no significant change after isometric wrist ulnar flexion. Furthermore, the ST was significantly shifted medially by isometric forearm pronation and wrist palmar flexion, whereas isometric finger flexion and wrist ulnar flexion demonstrated an adverse effect. Since the lateral shift of the ST has been suggested an increase in elbow valgus laxity[11], medial shift of ST would indicate the effect of FPMs against valgus stress. The largest effect was observed by forearm pronation in both the horizontal and vertical directions. According to these results, the PT, which is considered a main forearm pronator, and the FCR, which is considered a main wrist palmar flexor, may function as main dynamic stabilizers against valgus stress and PT may be the biggest contributor among the FPMs.

There are several limitations of this study. First, the manual valgus load applied to the elbow may have been different for each specimen and with each test. The examiner applied the maximum manual valgus stress to each subject ; the subjects did not experience shoulder or elbow pain during the examination. In order to minimize the inter-subject and the intra-subject variability, the amount of change before and after isometric contraction was measured during each test. However, the manual load and the arm position may not have been kept constant during the examination. It would be better to use a device capable of measuring the amount of valgus load, such as a hand dynamometer. Furthermore, it was difficult to distinguish the action of each muscle clearly. We regarded the action of the PT, FCR, FCU, and FDS as the forearm pronator, wrist flexor, wrist ulnar flexor, and finger flexor, respectively. However, these actions may involve several muscles, especially the FCR and the FCU, which both act as wrist flexors. To distinguish which FPMs are activated, electromyographic monitoring of each muscle should be performed during the examination.

In conclusion, this ultrasonographic in vivo dynamic study suggests that the PT and FCR function as dynamic stabilizers against elbow valgus stress, whereas the FCU has a lesser contribution. The information obtained from the present study may be useful in developing effective strategies for injury prevention and rehabilitation. Further in vivo dynamic studies should be conducted to clarify the exact function of FPMs as dynamic stabilizers of the elbow joint.

CONFLICT OF INTEREST

The authors, their immediate families, and any research foundations with which they are affiliated have not received any financial payments or other benefits from any commercial entity related to the subject of this article.

ETHICS

This work was approved by the ethical committee of Fukushima Medical University School of Medicine (No 1352).

REFERENCES

1. Ahmad CS, Lee TQ, ElAttache NS. Biomechanical evaluation of a new ulnar collateral ligament reconstruction technique with interference screw fixation. Am J Sports Med, **31** : 332-337, 2003.
2. Davidson PA, Pink M, Perry J, Jobe FW. Functional anatomy of the flexor pronator muscle group in relation to the medial collateral ligament of the elbow. Am J Sports Med, **23** : 245-250, 1995.
3. DiGiovine MM, Jobe FW, Pink M, Perry J. An electromyographic analysis of the upper extremity in pitching. J Shoulder Elbow Surg, **1** : 15-25, 1992.
4. Feltner M, Dapena J. Dynamics of the shoulder and elbow joint of the throwing arm during baseball pitch. Int J Sports Biomech, **2** : 235-259, 1986.
5. Fleisig GS, Andrews JR, Dilman CJ, Escamilla RF. Kinetics of baseball pitching with implications about injury mechanism. Am J Sports Med, **23** : 233-239, 1995.
6. Glousman RE, Barron J, Jobe FW, Perry J, Pink M. An electromyographic analysis of the elbow in normal and injured pitchers with medial collateral ligament insufficiency. Am J Sports Med, **20** : 311-317, 1992.
7. Hamilton CD, Glousman RE, Jobe FW, Brault J, Pink M, Perry J. Dynamic stability of the elbow : electromyographic analysis of the flexor pronator group and the extensor group in pitchers with valgus instability. J Shoulder Elbow Surg, **5** : 347-354, 1996.
8. Lin F, Kohli N, Perlmutter S, Lim D, Nuber GW, Makhsous M. Muscle contribution to elbow joint valgus stability. J Shoulder Elbow Surg, **16** : 795-802, 2007. doi.10.1016/j.jse.2007.03.024
9. Otoshi K, Kikuchi S, Shishido H, Konno S. The proximal origins of the flexor–pronator muscles and their role in the dynamic stabilization of the el-

bow joint : an anatomical study. Surg Radiol Anat, Jul 25, 2013 doi:10.1007/s00276-013-1168-3 [Epub ahead of print]
10. Park MC, Ahmad C. Dynamic contributions of the flexor-pronator mass to elbow valgus stability. J Bone Joint Surg Am, **86**A : 2268-2274, 2004.
11. Sasaki J, Takahara M, Ogino T, Kashiwa H, Ishigaki D, Kanauchi Y. Ultrasonographic assessment of the ulnar collateral ligament and medial elbow laxity in college baseball players. J Bone Joint Surg Am, **84**A : 525-531, 2002.
12. Sisto DJ, Jobe FW, Moynes DR, Antonelli DJ. An electromyographic analysis of the elbow in pitching. Am J Sports Med, **15** : 260-263, 1987.
13. Udall JH, Fitzpatrick MJ, McGarry MH, Leba TB, Lee TQ. Effects of flexor-pronator muscle loading on valgus stability of the elbow with an intact, stretched, and resected medial ulnar collateral ligament. J Shoulder Elbow Surg, **18** : 773-778, 2009. doi:10.1016/j.jse.2009.03.008.
14. Werner S, Fleisig GS, Dillman C, Andrews JR. Biomechanics of the elbow during baseball pitching. J Orthop Sports Phys Ther, **17** : 274-278, 1993.