福島県立医科大学 学術機関リポジトリ

FUKUSHIMA MEDICAL UNIVERSITY

Title	Uterine artery embolization for uterine arteriovenous malformation is associated with placental abnormalities in the subsequent pregnancy: two cases report
Author(s)	Soeda, Shu; Kyozuka, Hyo; Suzuki, Satoshi; Yasuda, Shun; Nomura, Yasuhisa; Fujimori, Keiya
Citation	Fukushima Journal of Medical Science. 60(1): 86-90
Issue Date	2014-08-08
URL	http://ir.fmu.ac.jp/dspace/handle/123456789/408
Rights	© 2014 The Fukushima Society of Medical Science
DOI	10.5387/fms.2013-13
Text Version	publisher

This document is downloaded at: 2024-05-01T21:56:24Z

Fukushima Medical University

Fukushima J. Med. Sci.,
Vol. 60, No. 1, 2014

[Case Report]

UTERINE ARTERY EMBOLIZATION FOR UTERINE ARTERIOVENOUS MALFORMATION IS ASSOCIATED WITH PLACENTAL ABNORMALITIES IN THE SUBSEQUENT PREGNANCY: TWO CASES REPORT

SHU SOEDA, HYO KYOZUKA, SATOSHI SUZUKI, SHUN YASUDA, YASUHISA NOMURA and KEIYA FUJIMORI

Department of Obstetrics and Gynecology, Fukushima Medical University School of Medicine, 1 Hikarigaoka, Fukushima City, Fukushima 960-1295, Japan

(Received July 5, 2013, accepted December 4, 2013)

Abstract : Uterine arteriovenous malformation (AVM) is generally associated with uterine trauma such as dilatation and curettage, therapeutic abortion, uterine surgery and uterine malignant tumors[1]. Uterine artery embolization (UAE) is performed on patients with uterine AVM who have desire for future pregnancy[2]. Some successful pregnancies were reported after UAE for uterine AVM[5,6], however complication during pregnancy has not been described clearly. We herein for the first time report two cases of successful pregnancy and spontaneous delivery after UAE for uterine AVM who had placenta accreta and placental abruption respectively. Although successful pregnancy is possible after UAE for AVM, placenta abnormalities have to be considered during pregnancy and after delivery.

Key words : Uterine arteriovenous malformation, uterine artery embolization, pregnancy, placenta accreta, placental abruption

INTRODUCTION

UAE has become an important treatment option for hemorrhage of obstetric and gynecological diseases. AVMs arising from the uterus are rare but often exhibit massive hemorrhage. To treat AVM with massive hemorrhage in patients who desire future fertility, UAE is the first choice. UAE for uterine AVM is generally safe but its effect on future pregnancy remains unknown. We herein report two cases of successful pregnancy and spontaneous delivery after UAE for uterine AVM, both of which suffered from placenta accreta and abruption placenta respectively during pregnancy.

CASE REPORT

Case 1

A 34-year-old woman, gravida 1 para 0 was admitted to another hospital due to an episode of vaginal hemorrhage. Her previous medical history included a termination of pregnancy by prostaglandin without undergoing curettage. Blood transfusion was twice performed because of recurrent vaginal hemorrhaging. Vaginal ultrasound and CT angiography revealed an unusual blood flow in the uterine body. The patient was then transferred to our hospital where she was pale on physical examination. Color Doppler transvaginal ultrasound revealed a mosaic pattern of AVM in the myometrium of the anterior wall (Fig. 1A). Due to the recurrent heavy vaginal bleeding, a decision was made to treat an area of AVM with percutaneous embolization. Pelvic digital subtraction angiogra-

Corresponding author : Shu Soeda E-mail : s-soeda@fmu.ac.jp
https://www.jstage.jst.go.jp/browse/fms http://www.fmu.ac.jp/home/lib/F-igaku/

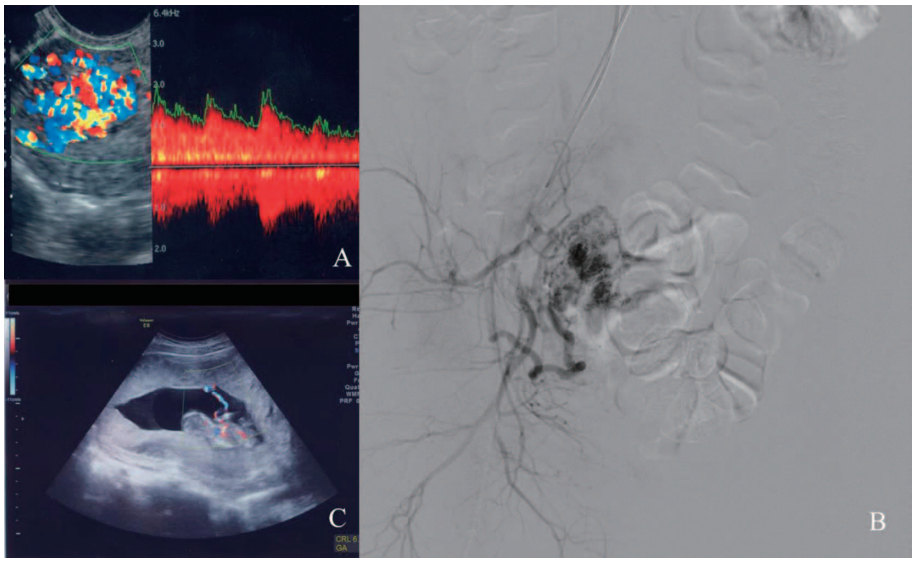

Fig. 1.
A. Color Doppler ultrasound shows turbuleny flow.
B. Flush injection on digital subtraction from right internal iliac artery shows a hypervascular mass in the uterus.
C. Transabdominal ultrasound shows the site of placentation was on the anterior wall of uterus and was the same site to the area of AVM.

phy in the early phase showed an arteriovenous shunt, hypertrophic arterial mass and early drainage into the left lilac vein (Fig. 1B). Bilateral UAE with gelatin sponge was successfully performed and she was discharged from hospital. The patient had an uneventful follow-up. She returned to us following a positive urine pregnancy test at sixth months after embolization. Serial ultrasound examination confirmed appropriate fetal growth. The placentation was in the same site where AVM occurred (Fig. 1C). She went into spontaneous labor at 40 weeks and delivered a 3,402 g infant by vacuum extraction due to the rigidity of the soft birth canal. The placenta was not seen within 30 minutes after delivery and there was increased hemorrhaging from the uterus. An oxytocin was therefore used to achieve uterine contractions. However, the hemorrhage continued, thus the manual removal of the placenta was attempted. Although a small part of the placenta seemed to have placenta accreta, almost the entire placenta was successfully removed. The hemorrhage stopped after this procedure.

Case 2

A 30 year-old woman, gravida 1 and para 1, was referred to our department with profuse vaginal bleeding. She had had a normal spontaneous delivery, however experienced a heavy atonic uterine hemorrhage after the delivery at the previous hospital 1 month prior to the presentation to our hospital. On physical examination she was orthostatic, tachycardic, and pale. Her hemoglobin level fell to 8.7 g/dl from her baseline of 12.5 g/dl. She was transfused with 2 units of packed red blood cells. A serum pregnancy test was negative with normal β-HCG levels. A pelvic ultrasound examination revealed a mass mainly consisting of vessels originating in the anterior uterine myometrium and extending into the endometrial cavity, consistent with an AVM (Fig. 2A). In an attempt to preserve fertility and achieve prompt relief from hemorrhage, the decision was made to treat her with percutaneous embolization. We performed superselective embolization (Fig. 2B) of uterine AVM with gelatin sponge cut by about 1.5 mm. After successful embolization of the AVM, her vaginal hemorrhage was minimal, and she was discharged from hospital the next day. The patient had an uneventful follow-up. She returned to us reporting a positive urine pregnancy test result at the fourth months after embolization. Serial ultrasound examinations confirmed appropriate fetal growth. The site of placentation was on the different site to the area of AVM (Fig. 2C). At 24 weeks gestation she was readmitted to our hospital complaining of uterine contractions. Trans-vaginal ultrasound revealed the shortening of cervical length to 15 mm, and irregular uterine contractions were revealed by maternal fetal monitoring. The patient had no inflammatory signs and cervicovaginal fetal fibronec-

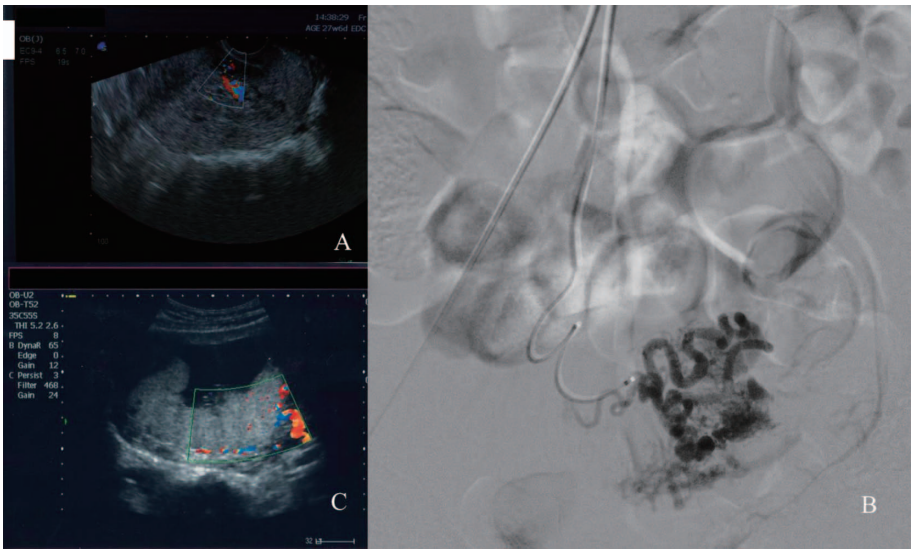

Fig. 2.
A. Color Doppler ultrasound shows a mosaic pattern.
B. Flush injection on digital subtraction from right uterine artery shows a hypervascular mass in the uterus.
C. Transabdominal ultrasound shows the site of placentation was on the posterior wall and was the different site to the area of AVM.

tin was negative. Intravenous ritodrine was administered and she was kept in bed. The therapies could extend the gestational age to 36 weeks. She was then discharged from hospital. At 38 weeks gestation, she visited our hospital complaining of a little vaginal hemorrhage. Uterine examination revealed that the cervix was 1 cm open and ripened. She was readmitted to our department. The night she was admitted, a profuse bright red vaginal hemorrhage occurred and a placental abruption was highly suspected. Bleeding discontinued soon, and the fetal monitoring showed a reassuring pattern. Augmentation by oxytocin was required because of the ripening of her uterine cervix. After 4 hours, a male baby weighing 2,950 g, with Apgar scores of 10/10, was delivered. The placenta was delivered smoothly and the freshly delivered placenta was showing evidence of clinically retroplacental clot, thus we concluded a placental abruption had happened. The uterine contraction was good and any adverse event did not happend.

DISCUSSION

Although uterine AVM is considered a rare and life-threatening entity, descriptions have been limited to isolated case reports and small case series[1–5]. Uterine AVM can be classified as congenital or acquired[2]. Causes of acquired uterine AVM are usually traumatic, resulting from dilation and curettage, therapeutic abortion, uterine surgery, direct uterine trauma and less commonly retained products of conception, trophoblastic disease, choriocarcinoma, or other gynecologic malignancies[1–3]. Methods for diagnosing uterine AVM include ultrasonography, CT, MRI, and angiography[6,7]. Gray-scale ultrasound findings of AVM are multiple anechoic structures with serpentine contours within the myometrium, while the addition of color doppler provides diagnostic sensitivity and a more accurate, noninvasive method of investigation[8]. On color Doppler imaging, AVM typically appears as vascular tangles of tortuous vessels, with high-velocity, low-resistance flow[9]. CT and MRI are very useful in determining the size, extent, and vascularity of AVM and defining the involvement of adjacent organs[10].

Several reports have described that for treatment of AVM, methylergonovine maleate[11], gonadotropin releasing hormone analog[12] and danazol[13] are possible options if the patient has slight bleeding. But when the patient have severe bleeding or the symptom of bleeding is repeated, UAE is first choice[1–4]. UAE has been used for patients with symptomic uterine leiomyoma, and several reports about pregnancy after UAE for symptomatic leiomyatoma have been published[14,15]. The safety of pregnancy after UAE for symptomatic leiomyoma has yet to be clearly proved. But most reports describe that the growth of the fetus was not affected. The main problem is the placental abnormalities such as placenta increta and accreta, increasing of cesarean section, and hemorrhage after deliv-

ery[16]. On the other hand among the patients who underwent UAE for AVM, the evidences of pregnancy after UAE for AVM are much less than those after UAE for leiomyoma. Delotte *et al.*[17] and Vilos *et al.*[18] reviewed total 30 cases of pregnancies following UAE for AVM and they reported that one placental previa happened but case of abruption placenta and placenta increta or accreta did not happened among these cases. The mechanism of placental abnormalities has not been reported in detail but it may be due to damage of the endometrium by UAE for leiomyoma. The potential explanation for abnormal placentation following UAE for leiomyoma is the endometrial ischaemia which would adversely affect the quality of the endometrium and the myometrial deficit left after the expulsion of the infarcted leiomyoma, which occurs in up to 10% of women undergoing UAE for symptomatic uterine leiomyoma[16]. Implantation at such a site could be assumed to be associated with a higher incidence of placenta accreta, particularly if minimal myometrium remains[16]. Direct implantation of a placenta onto a leiomyoma or focal myometrial deficit has been described by two groups in published case reports both of which were diagnosed after unexpected complications occurred during delivery[16]. Hysteroscopy revealed that the endometrium after UAE for symptomatic leiomyoma had a necrotic area, and histological analysis during hysteroscopy showed that about 5% of the endometrium after UAE was hypoproliferative[19]. The much smaller particle size for UAE relates to the non selective embolization and damages not only uterine normal tissue but also adnexa tissue. Thus we used about a 1,500 μm particle of gelatin sponge to reduce the possibility of damage of the endometrium.

This is the first report of placenta accreta and placental abruption after UAE for uterine AVM. The placenta accreta patient could easily have had her placenta removed, but due to atonish bleeding, she needed a blood transfusion. The patient with placenta abruption fortunately had a smooth delivery and fetal monitoring appeared reassuring and vaginal bleeding discontinued. In placenta accreta, the placenta was located where AVM had occurred whereas in placental abruption, the placenta was located where AVM had not occur. We therefore consider the site of placentation has a deep relationship with the cause of abnormal placentation. The endometrium of the AVM site could easily be affected by the embolization than the other sites. The embolization leaves a scar in the endometrium and accelerates the possibility of placenta accrete increta. Moreover, we speculate that if the site of placentation is different from the AVM site, the damaged endometrium due to UAE may become atrophic and cause disruption of the placental attachment and abruption placenta. In our case, especially about the case of abruption placenta, there is possibility that this occured episodically, so we can not conclude exactly that UAE for AVM was the cause of a placental abruption.

In conclusion, UAE is a safe and useful treatment for uterine AVM and several reports have reported that deliveries could be achieved in safe manner after UAE for AVM, however we should pay sufficient attention to the possibility of placental abnormalities such as placenta accrete increta and abruption placenta after UAE for AVM. Accumulation of many cases of the delivery after UAE for AVM is needed.

DISCLOSURE

None of the authors has anything to disclose.

REFERENCES

1. Delaloye JF, Maillard C, Laurini R. Acquired uterine arteriovenous fistulas after choriocarcinoma. A case report. Eur J Gynaecol Oncol, **19** : 453-454, 1998.
2. Vogelzang RL, Nemcek AA Jr, Skrtic Z, Gorrell J, Lurain JR. Uterine arteriovenous malformations : primary treatment with therapeutic embolization. J Vasc Interv Radiol, **2** : 517-522, 1991.
3. Peitsidis P, Manolakos E, Tsekoura V, Kreienberg R, Schwentner L. Uterine arteriovenous malformations induced after diagnostic curettage : a systematic review. Arch Gynecol Obstet, **284** : 1137-1151, 2011.
4. McCormick CC, Kim HS. Successful pregnancy with a full-term vaginal delivery one year after n-butyl cyanoacrylate embolization of a uterine arteriovenous malformation. Cardiovasc Intervent Radiol, **29** : 699-701, 2006.
5. Wang Z, Chen J, Shi H, Zhou K, Sun H, Li X, Pan J, Zhang X, Liu W, Yang N, Jin Z. Efficacy and safety of embolization in iatrogenic traumatic uterine vascular malformations. Clin Radiol, **67** : 541-545, 2012.
6. Grivell RM, Reid KM, Mellor A. Uterine arteriovenous malformations : a review of the current literature. Obstet Gynecol Surv, **60** : 761-767, 2005.
7. Cura M, Martinez N, Cura A, Dalsaso TJ, Elmerhi F. Arteriovenous malformations of the uterus.

Acta Radiol, **50** : 823-829, 2009.
8. Huang MW, Muradali D, Thurston WA, Burns PN, Wilson SR. Uterine arteriovenous malformations : gray-scale and Doppler US features with MR imaging correlation. Radiology, **206** : 115-123, 1998.
9. Timmerman D, Wauters J, Van Calenbergh S, Van Schoubroeck D, Maleux G, Van Den Bosch T, Spitz B. Color Doppler imaging is a valuable tool for the diagnosis and management of uterine vascular malformations. Ultrasound Obstet Gynecol, **21** : 570-577, 2003.
10. Gulati MS, Paul SB, Batra A, Sarma D, Dadhwal V, Nath J. Uterine arteriovenous malformations : the role of intravenous 'dual-phase' CT angiography. Clin Imaging, **24** : 10-14, 2000.
11. Onoyama I, Fukuhara M, Okuma A, *et al.* Successful pregnancy after the noninvasive management of uterine arteriovenous malformation. Acta Obstet Gynecol Scand, **80** : 1148-1149, 2001.
12. Takeuchi K, Yamada T, Iwasa M, *et al.* Successful medical treatment with danazol after failed embolization of uterine arteriovenous malformation. Obstet Gynecol, **102** : 843-844, 2003.
13. Nonaka T, Yahata T, Kashima K, *et al.* Resolution of uterine arteriovenous malformation and successful pregnancy after treatment with a gonadotropin-releasing hormone agonist. Obstet Gynecol, **117** : 452-455, 2011.
14. Walker WJ, McDowell SJ. Pregnancy after uterine artery embolization for leiomyomata : a series of 56 completed pregnancies. Am J Obstet Gynecol, **195** : 1266-1271, 2006.
15. Firouznia K, Ghanaati H, Sanaati M, Jalali AH, Shakiba M. Pregnancy after uterine artery embolization for symptomatic fibroids : a series of 15 pregnancies. AJR Am J Roentgenol, **192** : 1588-1592, 2009.
16. Kitson SJ, Macphail S, Bulmer J. Is pregnancy safe after uterine artery embolisation? BJOG, **119** : 519-521, 2012.
17. Delotte J, Chevallier P, Benoit B, Castillon JM, Bongain A. Pregnancy after embolization therapy for uterine arteriovenous malformation. Fertil Steril, **85** : 228, 2006.
18. Angelos G. Vilos, George A. Vilos, Barbara de Vrijer, Roman Kozak, Basim Abu-Rafea. Fertility and pregnancy outcomes following uterine artery embolization (UAE) for uterine arteriovenous malformation (AVM). Gynecological Surgery, **7** : 401-405, 2010.
19. Mara M, Horak P, Kubinova K, Dundr P, Belsan T, Kuzel D. Hysteroscopy after uterine fibroid embolization : evaluation of intrauterine findings in 127 patients. J Obstet Gynaecol Res, **38** : 823-831, 2012.