Title	Long-term survival after resection of metastases in the lungs and larynx originating from sigmoid colon cancer: report of a case
Author(s)	Terashima, Shinya; Watanabe, Satoshi; Shoji, Mitsuo
Citation	Fukushima Journal of Medical Science. 60(1): 82-85
Issue Date	2014-08-08
URL	http://ir.fmu.ac.jp/dspace/handle/123456789/407
Rights	© 2014 The Fukushima Society of Medical Science
DOI	10.5387/fms.2013-14
Text Version	publisher

Fukushima J. Med. Sci.,
Vol. 60, No. 1, 2014

[Case Report]

LONG-TERM SURVIVAL AFTER RESECTION OF METASTASES IN THE LUNGS AND LARYNX ORIGINATING FROM SIGMOID COLON CANCER : REPORT OF A CASE

SHINYA TERASHIMA, SATOSHI WATANABE and MITSUO SHOJI

Department of Surgery, Fujita General Hospital, 14-1 Sanbongi Tsukanome, Kunimi-machi, Date-gun, Fukushima 969-1751, Japan

(Received August 28, 2013, accepted November 8, 2013)

Abstract : Metastatic neoplasms in the larynx from remote primary tumors are uncommon, and laryngeal metastasis originating from the colorectum is extremely rare. We herein report a case of metastatic laryngeal carcinoma originating from sigmoid colon cancer in a 54-year-old female. Curative partial laryngectomy was performed, and the patient remains alive with a good quality of life and no signs of recurrence seven years and eight months after sigmoidectomy and four years and eight months after partial laryngectomy.

Key words : Colorectal cancer, Larynx, Metastasis

INTRODUCTION

Secondary laryngeal cancers are very rare tumors, with an incidence ranging from 0.09% to 0.4% of all laryngeal neoplasms. Among these lesions, skin melanoma and renal cell carcinoma are the most frequent sites of origin[1]. However, colorectal carcinoma (CRC) metastases to the larynx are extremely rare ; there are only 12 cases of secondary laryngeal tumors originating from CRC.

We herein report a case of sigmoid colon cancer metastasis to the lungs and larynx that was successfully resected and discuss the characteristics of metastatic laryngeal tumors. To our knowledge, this case is the only reported case of long-term survival in a patient with this disease.

CASE REPORT

In November 2005, a 54-year-old Japanese female underwent sigmoidectomy with lymph node dissection under a diagnosis of sigmoid colon cancer. The postoperative TNM classification was Stage IIIB disease (T3N1M0) and histopathological findings were moderately differentiated adenocarcinoma (Fig. 1a). Postoperative adjuvant FOLFOX4 (oxaliplatin plus an infusion of 5-fluorouracil /levofolinate) therapy was administered for 11 cycles. In May 2008, a computed tomography (CT) scan of the thorax showed a 2 cm nodular mass in the right middle lung. Consistent with the CT findings, positron emission tomography (PET) demonstrated high uptake of FDG in the right middle lung. There were no abnormal areas of uptake in either the anastomotic lesion or regional lymph nodes. Therefore, middle lobectomy of the right lung was performed under a diagnosis of lung metastasis. The histopathological findings were well differentiated adenocarcinoma, consistent with a diagnosis of metachronous lung metastasis of sigmoid colon carcinoma (Fig. 1b).

In November 2008, the patient was admitted to our clinic with a 2-week history of hoarseness. On admission, she looked well. Her body temperature, arterial blood pressure and respirations were normal. A physical examination showed no abnormal findings. Laboratory tests were normal, and the carcinoembryonic antigen level was 2.9 μg/L (normal range : <5.0 μg/L).

Laryngoscopy revealed a nodular mass in the right subglottic lesion (Fig. 2). A histological examination of laryngoscopic biopsy specimens

Corresponding author : Shinya Terashima E-mail : stera@rose.ocn.ne.jp
https://www.jstage.jst.go.jp/browse/fms http://www.fmu.ac.jp/home/lib/F-igaku/

a

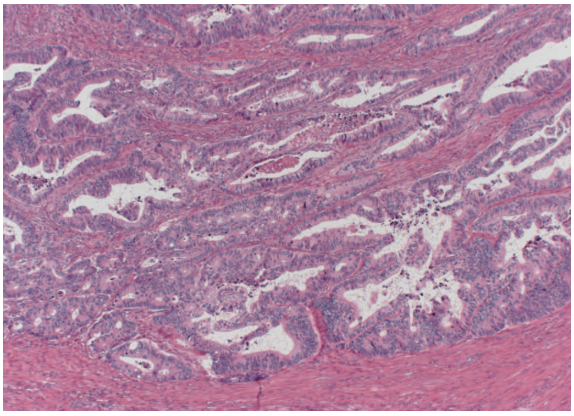

b

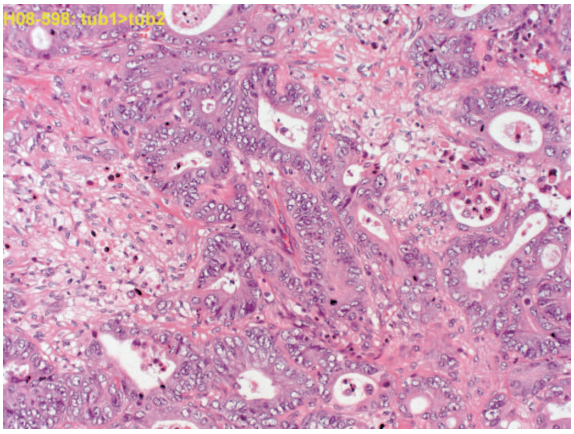

c

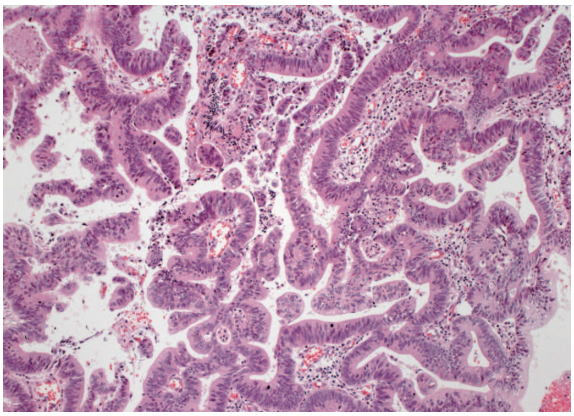

Fig. 1. Microscopic findings of the reseted specimens. a. sigmoid colon, b. lungs, c. laryngeal tumor (H&E, a–c ×10).

revealed suspected metastasis from sigmoidal adenocarcinoma. A further workup did not reveal any other sites of metastatic spread. Therefore, the patient underwent partial laryngectomy at another institution. The pathological specimen exhibited moderately differentiated adenocarcinoma, consistent with a diagnosis of metastasis from sigmoidal adenocarcinoma (Fig. 1c). Additional chemotherapy

Fig. 2.

with S1 was administered at 100 mg/day over six months. The patient remains alive with a good quality of life at seven years and six months after the initial surgery, and four years and six months after partial laryngectomy, respectively. Moreover, posttreatment annual CT scan showed no recurrent disease.

DISCUSSION

Colorectal cancer is a major cause of death worldwide, and its incidence has been increasing over the past 25 years[2-4].

With the increasing use of new radiologic modalities, such as CT, magnetic resonance imaging (MRI) and PET, together with the increasing survival rates of patients with primary colorectal cancer, metastasis is more likely to be diagnosed.

Common metastatic sites for adenocarcinoma of the colon and rectum include the liver and the lungs, whereas metastasis to the larynx is very rare. Metastatic neoplasms in the larynx are unusual, accounting for 0.09% to 0.4% of all laryngeal tumors[1]. On the other hand, Friedmann and Osborn[5] reported that 23.9% of patients with metastasis to the head and neck have laryngeal and/or tracheal diseases at autopsy. The difference in the frequency of this disease in clinical and autopsy cases suggests the possibility that the actual clinical prevalence of laryngeal metastasis has been underestimated.

To the best of our knowledge, only 12 cases, including our case, of metastasis of CRC have been reported in the English language literature (Table 1)[6-15].

Based on the cases with available information, laryngeal metastases have the following characteris-

Table 1. Reported cases of laryngeal metastasis originating from colorectal cancer.

First author[Ref)]	Age (years)/ Sex	Initial presentation	Primary site[a]	TNM G grade	Other distant metastasis	Treatment for laryngeal metastasis	Results
Whicker[6)]	75/M	Hoarseness, Stridor	S	2	Unknown	Radiation	6 months alive
Abemayor[7)]	69/F	Hoarseness, Stridor	T	2	Liver	Tracheostomy, Radiation	Unknown
Cavicchi[8)]	59/F	Dyspnea	Unknown	1	Lung	Radiation	Unknown
Nicolai[9)]	53/F	Dyspnea	R	1	Lung	Laser resection	In a year dead
Nicolai[9)]	58/F	Dyspnea	S	2	Lung	Laser resection, Photocoagulation	20 months alive
Puxeddu[10)]	65/M	Respiratory distress	Unknown	2	Liver	Tracheostomy, Radiation	3 months dead
Hilger[11)]	73/F	Stridor	R	Unknown	Unknown	Extended laryngectomy	15 months dead
Sano[12)]	81/F	Hoaseness, Dyspnea	Unknown	2	Lung, Sacrum	Tracheostomy, Radiation	16 months alive
Ramanathan[13)]	51/M	Hoarseness, Swelling	R	2	Liver, Sacrum	Unknown	Unknown
Marioni[14)]	78/F	Peristomal swelling	S	Unknown	Lung, Thyroid	Total thyroidectomy, Laryngectomy	4 months alive with metastasis
Ta[15)]	60/M	Dyspnea	R	2	Lung	Tracheostomy, Debulking	Unknown
Present case	54/F	Hoarseness	S	2	Lung	Partial laryngectomy	54 months alive

[a] S, sigmoid colon ; R, rectum ; T, transeverse colon.

tics. The mean age of the patients with laryngeal metastasis originating from CRC was 64.7 years (range : 51–81). The 12 reported cases involved 8 females and 4 males. The signs and symptoms of secondary laryngeal neoplasms are similar to those of other malignant laryngeal lesions. The primary site of CRC was the sigmoid colon in 4 cases, rectum in 4 cases, transverse colon in 1 case and unspecified colonic locations in 3 cases. Data for the grading of primary CRC are available for 10 patients : G2 in 8 cases and G1 in 2 cases. Data for other sites of distant metastasis are available for 10 patients : 9 patients had other sites of distant metastasis and 1 patient had isolated laryngeal metastasis. Of the 9 patients with other distant sites of metastasis, metachronous lung metastasis was present in 8 cases and liver metastasis was present in 3 cases before laryngeal metastasis. Although the metastatic mechanism to the larynx is still unknown, metastatic spread can occur via hematogenous and lymphatic route. The route for hematogenous spread via the systemic circulation is the inferior vena cava, right heart, lungs, left heart, aorta, external carotid artery, upper thyroid artery, and upper laryngeal artery[16)]. The vertebral venous plexus has also been implicated in retrograde metastatic spread of colorectal cancer[17)]. The high incidence of lung metastasis in the patients with laryngeal metastasis strongly suggests a metastatic route from the lungs to the larynx.

Since no general rules can be established on how to treat secondary laryngeal tumors due to their rare nature, the treatment approach must be tailored to the individual patient based on the biologic behavior of the primary tumor, the characteristics of the laryngeal lesion, the general condition of the patient and the results of the metastatic workup, which must include CT, PET and bone scintigraphy as long as possible.

A general recommendation, however, can be made that symptomatic and palliative treatment should be administered in patients with multiple metastases, including those in the larynx. Options for intervention include bronchoscopy, direct laryngoscopy with laser excision, and debulking of the laryngeal tumor. Tracheostomy can be performed in patients with significant respiratory distress due to airway obstruction. A reasonable chance for curative treatment can be expected only in patients with solitary laryngeal metastases. Therefore, adjuvant therapy was done only in our present case. The prognosis of patients with laryngeal metastasis is poor because laryngeal involvement is generally observed in terminal patients with other multiple metastases. The longest survival after treatment for laryngeal metastases originating from CRC was

observed in our patient. Curative treatment for laryngeal metastasis of primary CRC with an appropriate adjuvant chemotherapy may prolong the survival of carefully selected patients.

CONCLUSION

While the incidence is low, patients with a history of CRC, lung metastasis and symptoms of hoarseness, dyspnea, dysphonia, and stridor should be evaluated for the possibility of metastasis to the larynx.

A thorough investigation for metastasis to other organs should also be performed.

CONFLICT OF INTEREST STATEMENT

S. Terashima and other co-authors have no conflict of interest.

REFERENCES

1. Ferlito A. Secondary neoplasms. *In* : Ferlito A. Neoplasms of the Larynx. Churchill Livingstone, Edinburgh, 349-360, 1993.
2. Gatta G, Faivre J, Capocaccia R, de Loeon PM, EUROCARE Working Group. Survival of colorectal cancer patients in Europe during the period 1978-1989. Eur J Cancer, **34** : 2176-2183, 1998.
3. LeviF, Lucchini F, Negri E, La Vecchia C. Worldwide patterns of cancer mortality 1990-1994. Eur J Cancer Prev, **8** : 381-400, 1999.
4. Center MM, Jemal A, Ward E. International trends in colorectal cancer incidence rates. Cancer Epidemiol Biomakers Prev, **18** : 1688-1694, 2009.
5. Friedmann I, Osborn DA. Metaststic tumours in the ear, nose, and throat region. J Laryngol Otol, **79** : 576-591, 1965.
6. Whicker JH, Carder GA, Devin KD. Metastasis to the larynx. Report of a case and review of the literature. Arch Otolaryngol, **96** : 182-184, 1972.
7. Abemayor E, Cochran AJ, Calcaterra TC. Metastatic cancer to the larynx. Diagnosis and management. Cancer, **52** : 1944-1948, 1983.
8. Cavicchi O, Farneti G, Occhiuzzi L, Sorrenti G. Laryngeal metastasis from colonic adenocarcinoma. J Laryngol Otol, **104** : 730-732, 1990.
9. Nicolai P, Puxeddu R, Cappiello J, Peretti G, Battocchio S, Facchetti F, Antonelli AR. Metastatic neoplasms to the larynx : report of three cases. Laryngoscope, **106** : 851-856, 1996.
10. Puxeddu R, Pelagatti CL, Ambu R. Colon adenocarcinoma metastatic to the larynx. Eur Arch Otorhinolaryngol, **254** : 353-355, 1997.
11. Hilger AW, Prichard AJ, Jones T. Adenocarcinoma of the larynx-a distant metastasis from a rectal primary. J Laryngol Otol, **112** : 199-201, 1998.
12. Sano D, Matsuda H, Yoshida T, Kimura Y, Tanigaki Y, Mikami Y, Tsukuda M. A case of metastatic colon adenocarcinoma in the larynx. Acta Otolaryngol, **125** : 220-222, 2005.
13. Ramanathan Y, Rajagopalan R, Rahman NA. Laryngeal metastasis from a rectal carcinoma. Ear Nose Throat J, **86** : 685-686, 2007.
14. Marioni G, De Filippis C, Ottaviano G, Lorusso M, Staffieri C, Bernini G, Blandamura S. Laryngeal metastasis from sigmoid colon adenocarcinoma followed by peristomal recurrence. Acta Otolaryngol, **126** : 661-663, 2006.
15. Ta JQ, Kim JY. Rectal adenocarcinoma metastatic to the larynx. Ear Nose Throat J, **90** : E28, 2011.
16. Batsakis JG, Luna MA, Byers RM. Metastases to the larynx. Head Neck Surg, **7** : 458-460, 1985.
17. Vider M, Maruyama Y, Narvaez R. Significance of the vertebral venous (Baston's) plexus in metastatic spread in colorectal carcinoma. Cancer, **40** : 67-71, 1977.