



Title	A case of delayed postoperative bleeding after excision of endometrial polyp using resectoscope in an infertile woman with von Willebrand disease: a case report and literature review
Author(s)	Okoshi, Chihiro; Takahashi, Toshifumi; Fukatsu, Masahiko; Suganuma, Ryota; Ikezoe, Takayuki; Fujimori, Keiya
Citation	Fukushima Journal of Medical Science. 69(3): 197-204
Issue Date	2023
URL	<a href="http://ir.fmu.ac.jp/dspace/handle/123456789/2202">http://ir.fmu.ac.jp/dspace/handle/123456789/2202</a>
Rights	© 2023 The Fukushima Society of Medical Science. This article is licensed under a Creative Commons [Attribution-NonCommercial-ShareAlike 4.0 International] license.
DOI	10.5387/fms.2023-04
Text Version	publisher



## A case of delayed postoperative bleeding after excision of endometrial polyp using resectoscope in an infertile woman with von Willebrand disease : a case report and literature review

Chihiro Okoshi<sup>1)</sup>, Toshifumi Takahashi<sup>2)</sup>, Masahiko Fukatsu<sup>3)</sup>, Ryota Suganuma<sup>1)</sup>,  
Takayuki Ikezoe<sup>3)</sup> and Keiya Fujimori<sup>1)</sup>

<sup>1)</sup>Department of Obstetrics and Gynecology, Fukushima Medical University School of Medicine, Fukushima, Japan, <sup>2)</sup>Fukushima Medical Center for Children and Women, Fukushima Medical University, Fukushima Japan, <sup>3)</sup>Department of Haematology Fukushima Medical University School of Medicine, Fukushima, Japan

(Received February 1, 2023, accepted September 8, 2023)

### Abstract

Von Willebrand disease (VWD) is a bleeding disorder caused by a congenital quantitative reduction, deficiency, or qualitative abnormality of the von Willebrand factor (VWF). Here, we report a case of delayed postoperative bleeding in an infertile woman with endometrial polyps complicated by VWD. The patient was a 39-year-old infertile woman with type 2A VWD. At 38 years of age, she was referred to our hospital for infertility and heavy menstrual bleeding. Hysteroscopy revealed a 15-mm polyp lesion in the uterus. The patient was scheduled for transcervical resection (TCR) of the endometrial polyp. Gonadotropin-releasing hormone agonists were preoperatively administered to prevent menstruation. The VWF-containing concentrate was administered for 3 days according to guidelines. The patient was discharged on postoperative day 3 after confirming the absence of uterine bleeding. Uterine bleeding began on postoperative day 6. The patient was readmitted on postoperative day 7 and treated with VWF-containing concentrate for 5 days, after which hemostasis was confirmed. TCR surgery for endometrial lesions is classified as a minor surgery, and guidelines recommend short-term VWF-containing concentrate replacement. However, it should be kept in mind that only short-term VWF-containing concentrate replacement may cause rebleeding postoperatively.

**Key words :** von Willebrand disease, endometrial polyp, polypectomy, uterine bleeding

### Introduction

Von Willebrand factor (VWF) serves two crucial functions within the hemostatic mechanism : facilitating platelet adhesion and acting as a carrier protein for coagulation factor VIII (FVIII). An insufficient quantity or abnormal quality of VWF can lead to diverse bleeding symptoms<sup>1-3)</sup>. Von Willebrand disease (VWD) is an inherited bleeding disorder resulting from congenital reductions, deficiencies, or abnormalities in the quantity or quality of VWF<sup>1-3)</sup>. The main symptoms are subcutaneous and mucosal

bleeding. In non-pregnant women, it causes abnormal uterine bleeding, heavy and prolonged menstruation, and ovarian bleeding after ovulation<sup>4-6)</sup>. Persistent uterine bleeding or profuse bleeding may also occur after miscarriage or delivery in pregnant women<sup>5,7)</sup>. Thus, VWD significantly reduces the quality of life of women of reproductive age.

Uterine cavity lesions are not only a cause of abnormal uterine bleeding but also of infertility<sup>8)</sup>. Endometrial polyps and submucosal fibroids are examples of endometrial lesions that are associated with abnormal bleeding and infertility. Resec-

Corresponding author : Toshifumi Takahashi E-mail : totakaha@fmu.ac.jp

©2023 The Fukushima Society of Medical Science. This article is licensed under a Creative Commons [Attribution-NonCommercial-ShareAlike 4.0 International] license.  
<https://creativecommons.org/licenses/by-nc-sa/4.0/>

tion of endometrial polyps and submucosal fibroids has been suggested to improve pregnancy rates<sup>8,9</sup>. Resection of uterine cavity lesions in infertile women is performed by hysteroscopy or resectoscopy, and the frequency of postoperative bleeding requiring transfusion or hemostasis has been reported to be 0.16%<sup>10</sup>.

In women with VWD who are undergoing surgery or experiencing abnormal uterine bleeding, the dose and duration of administration of VWF-containing concentrates should be determined based on the type and severity of the surgery or bleeding<sup>7,11,12</sup>. However, there are no specific recommendations for the dose and duration of concentrated preparations containing VWF for surgery of intrauterine cavity lesions.

In the present report, an infertile woman with VWD was found to have endometrial polyps, and endometrial polypectomy was performed using a resectoscope after administration of a VWF-containing concentrate for 3 days to prevent intraoperative and postoperative bleeding.

There have been no reports of delayed postoperative bleeding after the excision of intrauterine lesions in women with VWD, despite guideline-guided bleeding prophylaxis. Here, we report a case of delayed postoperative bleeding in an infertile woman with endometrial polyps complicated by VWD and review literature about similar cases.

### Case report

The patient was a 39-year-old Japanese nulligravida woman. The patient's family history included a father with VWD. At 2 years of age, the patient was diagnosed with VWD type 2A. The patient's medical history included hyperthyroidism, duodenal ulcers, ovarian bleeding, and fibroids. She had regular menstruation and hypermenorrhea. She underwent a transfusion twice due to heavy menstrual bleeding at both 12 (menarche) and 17 years of age. At 36 years of age, the patient underwent laparotomic myomectomy for multiple uterine fibroids.

At 38 years of age, she visited our hospital because of heavy menstruation and desire for a child. The patient was administered VWF-containing plasma-derived FVIII (VWF/pd-FVIII) concentrate (Confact F, KM Biologics, Kumamoto, Japan) to control menstrual bleeding. The patient's height, weight, and body mass index were 158 cm, 66 kg, and 26.4 kg/m<sup>2</sup>, respectively. Blood pressure and pulse were 132/78 mmHg and 90/min. The pa-

tient's blood type was O Rh-positive. The patient was in a good general condition and showed no signs of thyroid gland enlargement. The abdomen of the patient showed scars from laparotomy. A vaginal speculum examination revealed a large amount of uterine bleeding in the vaginal cavity. Internal examination revealed a uterus of a hen's egg size, good mobility, and no palpable bilateral adnexa. Transvaginal ultrasonography revealed blood retention in the uterus. Owing to heavy menstruation, a gonadotropin-releasing hormone (GnRH) agonist (leuprorelin acetate 1.88 mg, ASUKA Pharmaceutical Co., Ltd., Tokyo, Japan) was administered for 6 months.

A basic infertility workup was performed following GnRH agonist administration. Table 1 shows the results of the laboratory examination. Hysterosalpingography revealed bilateral tubal patency. Husband's semen analysis showed no abnormal findings according to World Health Organization 2021 criteria. Subsequently, transvaginal ultrasonography was performed again in the absence of uterine bleeding, and a 15-mm mass was found in the uterus (Fig. 1a). Hysteroscopy revealed a smooth endometrial polyp attached to the posterior uterine wall. Since endometrial polyps, in addition to VWD, may cause heavy menstruation and infertility, the plan was to perform endometrial polypectomy using a resectoscope. Following the hematologist's advice, we decided to administer 2,000 units of VWF/pd-FVIII concentrate on the day of surgery and on the first and second postoperative days. During the waiting period before surgery, GnRH agonist was administered again to prevent the onset of menstruation, with the last dose administered 10 days before surgery.

Preoperative cervical dilation with laminaria rods was not performed in order to avoid poor surgical vision due to uterine bleeding. On the day of the surgery, the patient entered the operating room after receiving 2,000 units of VWF/pd-FVIII concentrate. Under general anesthesia in the lithotripsy position, 100 mL of saline was injected into the bladder, and the uterus was monitored using transabdominal ultrasonography during the operation. The uterine cavity was irrigated using 3% D-sorbitol solution (Uromatic S, Baxter, Tokyo, Japan). The cervix was dilated to Hagar dilator No. 11. A 12° resectoscope (OES Pro resectoscope system; Olympus, Tokyo, Japan) with a loop electrode was inserted. The polyp was attached to the uterine fundus and resected using a loop electrode (Figs. 1b, c). Bleeding at the detached surface (Fig. 1d) necessitated coagulation and hemostasis. The opera-

Table 1. Laboratory examination of the patient at initial visit to our hospital

	Data	Reference range
WBC ( $\mu\text{L}$ )	4,800	3,300-8,600
RBC ( $10^6/\mu\text{L}$ )	5.24	3.86-4.92
Hemoglobin (g/dL)	10.8	11.6-14.8
Hematocrit (%)	35.3	35.1-44.4
MCV (fL)	67.2	83.6-98.2
MCH (pg)	20.5	27.5-33.2
MCHC (g/dL)	30.6	31.7-35.3
Platelets ( $10^3/\mu\text{L}$ )	231	158-348
PT (%)	102.1	70-130
PT-INR	0.99	
APTT (sec)	40.1	26.9-38.1
Fibrinogen (mg/dL)	258	200-400
VIII : C (%)	32.7	70-150
VWF : Ag (%)	24	50-150
VWF : RCo (%)	< 10	60-170
Total protein (g/dL)	7.3	6.6-8.1
Albumin (g/dL)	4.4	4.1-5.1
AST (U/L)	17	13-30
ALT (U/L)	17	7-23
LDH (U/L)	207	124-222
Total bilirubin (mg/dL)	0.5	0.4-1.5
Blood urea nitrogen (mg/dL)	9	8-20
Creatinine (mg/dL)	0.52	0.46-0.79
Na (mmol/L)	142	138-145
K (mmol/L)	3.5	3.6-4.8
Cl (mmol/L)	106	101-108
Fe ( $\mu\text{g/dL}$ )	26	40-188
UIBC ( $\mu\text{g/dL}$ )	373	137-325
Hemoglobin A1c (%)	5.2	4.9-6.0

WBC : white blood cells

RBC : red blood cells

MCV : mean corpuscular volume

MCH : mean corpuscular hemoglobin

MCHC : mean corpuscular hemoglobin concentration

PT : prothrombin time

PT INR : prothrombin time international normalized ratio

APTT : activated partial thromboplastin time

VIII : C : coagulation factor VIII

VWF : Ag : von Willebrand factor antigen

VWF : RCo : von Willebrand factor ristocetin cofactor activity

AST : aspartate aminotransferase

ALT : alanine aminotransferase

LDH : lactate dehydrogenase

UIBC : unsaturated iron binding capacity

tive time was 21 min, and the amount of bleeding was minimal. The amount of 3% D-sorbitol perfusate used was approximately 500 mL, and the difference between the inflow and outflow was almost

zero. Pathological diagnosis confirmed that the resected specimen was an endometrial polyp (Figs. 2a, b, c). On postoperative days 1 and 2, 2,000 units of VWF/pd-FVIII concentrate were used. On postoperative day 3, the patient was discharged from the hospital without uterine bleeding on transvaginal ultrasonography (Fig. 3a). On the day 6 after the surgery, the patient experienced massive genital bleeding. On postoperative day 7, the patient was readmitted to the hospital and transvaginal ultrasonography revealed that the uterus was filled with clots (Fig. 3b), which was attributed to delayed postoperative bleeding. The patient was urgently treated with 2,000 units of VWF/pd-FVIII concentrate for 3 days to stop the bleeding. However, bleeding from the uterus persisted, and anemia progressed; therefore, the dose was increased to 2,500 units of VWF/pd-FVIII concentrate, and hemostasis was achieved on the 11th day after the surgery. The patient was finally discharged 12 days postoperatively. The patient treatment course chart is shown in Fig. 4. Informed consent was obtained from the patient for this case report and patient anonymity was preserved.

## Discussion

VWD is a rare hereditary disease caused by congenital quantitative loss and/or qualitative abnormalities of VWF<sup>5)</sup>. VWD is transmitted mainly by autosomal dominant inheritance and partly by autosomal recessive inheritance<sup>12)</sup>. The frequency of VWD varies depending on the population being studied and the criteria used to diagnose the condition. According to estimates, the overall frequency of VWD is approximately 1% in the general population<sup>13-15)</sup>. However, many VWD cases are asymptomatic and may not be diagnosed. The frequency of VWD presenting with bleeding symptoms is generally low, with some estimates suggesting that it is approximately 1% (1 per 10,000)<sup>2)</sup>. In adolescent women with heavy menstrual bleeding, up to 20% of the causes include coagulation disorders, and 5-36% of those are reported to be VWD<sup>4,16,17)</sup>. Women with type 2A VWD, as in this case, usually develop severe bleeding symptoms, including excessive menstrual bleeding requiring blood transfusions and ovarian bleeding after puberty.

VWD is classified into three categories, Types 1, 2, and 3, based on VWF activity, VWF antigen levels, and multimer formation results<sup>3)</sup>. Type 1 has qualitatively normal but quantitatively decreased VWF, accounting for approximately 70% of the VWD

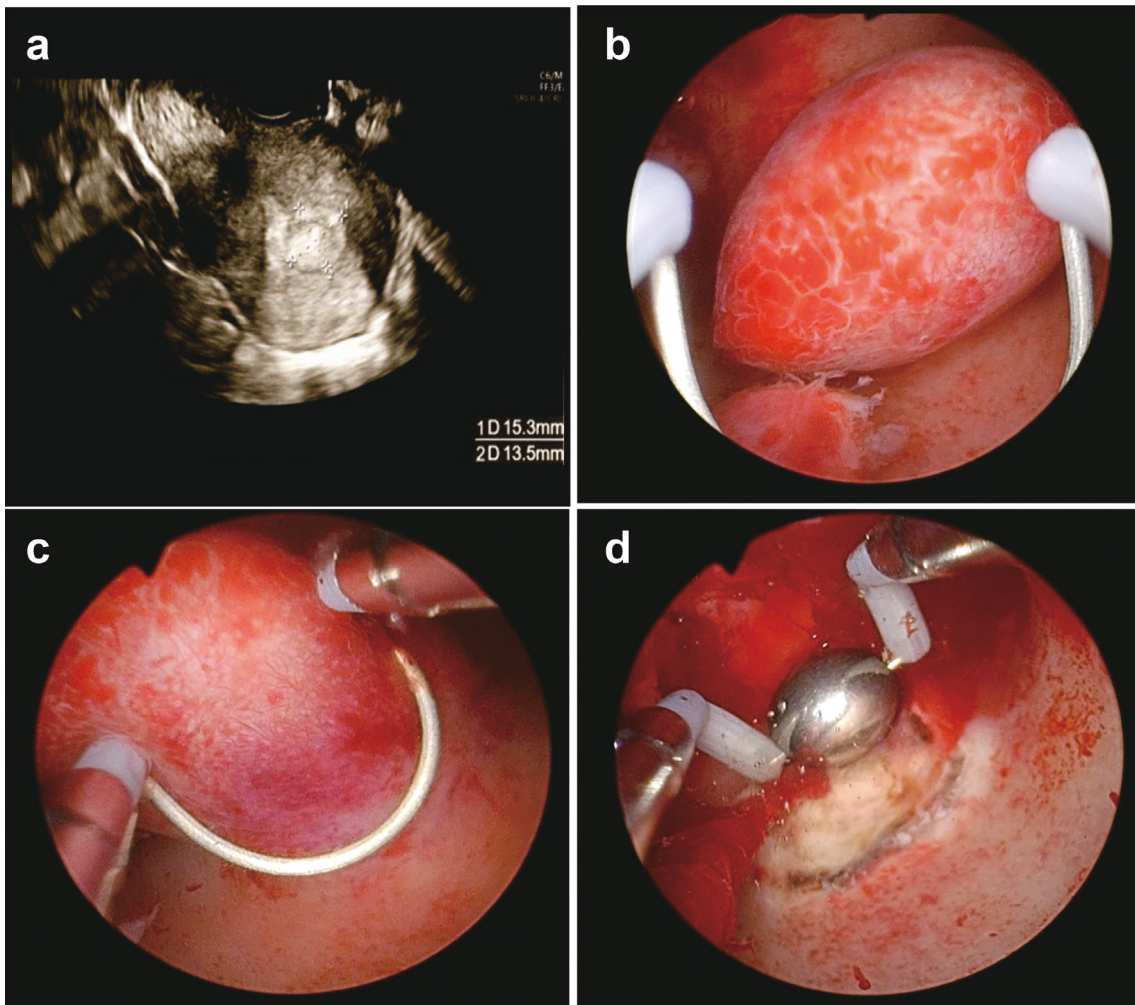


Fig. 1. Transvaginal ultrasonography shows a 15×13 mm hyperechoic lesion of the uterus (a). Photographs of transcervical resection of the endometrial polyp. The endometrial polyp attaches to the posterior wall of the uterus (b, c). Photograph of hemostasis using a ball electrode after endometrial polypectomy by cutting electrode (d).

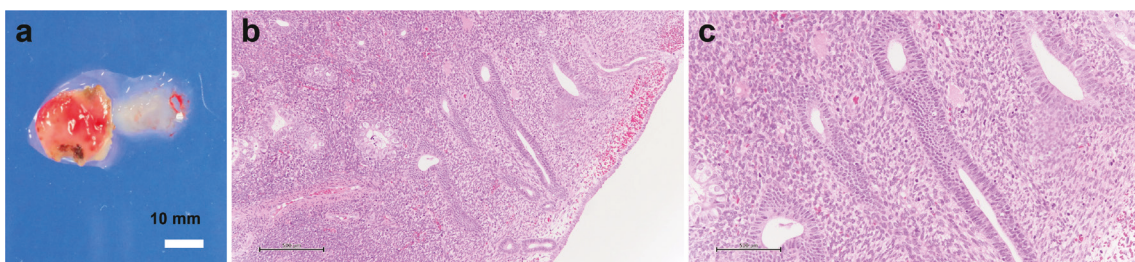


Fig. 2. Macroscopic appearance of resected specimen (a). White bar = 10 mm. Microscopic histology of resected specimen (b : low power magnification, c : high power magnification). Black bar = 500  $\mu$ m.

cases. Type 2 is due to qualitative abnormalities in VWF and accounts for approximately 25% of VWD. These are further classified into four types : 2A, 2B, 2M, and 2N. Type 2A accounts for 10–20% of VWD cases and is the most common Type 2 subtype. The pathophysiology is the consumption of macromolecular multimers due to increased binding of abnormal VWF to platelet glycoprotein 1b. Type

3, although a rare form of VWD, is an autosomal recessive trait of VWF deficiency, which causes severe submucosal, subcutaneous, and intra-articular hemorrhages.

The basis of VWD treatment is hemostasis at the time of bleeding and prophylaxis during hemostasis by correcting the decrease in VWF and Factor VIII. The main therapeutic agents are desmopres-

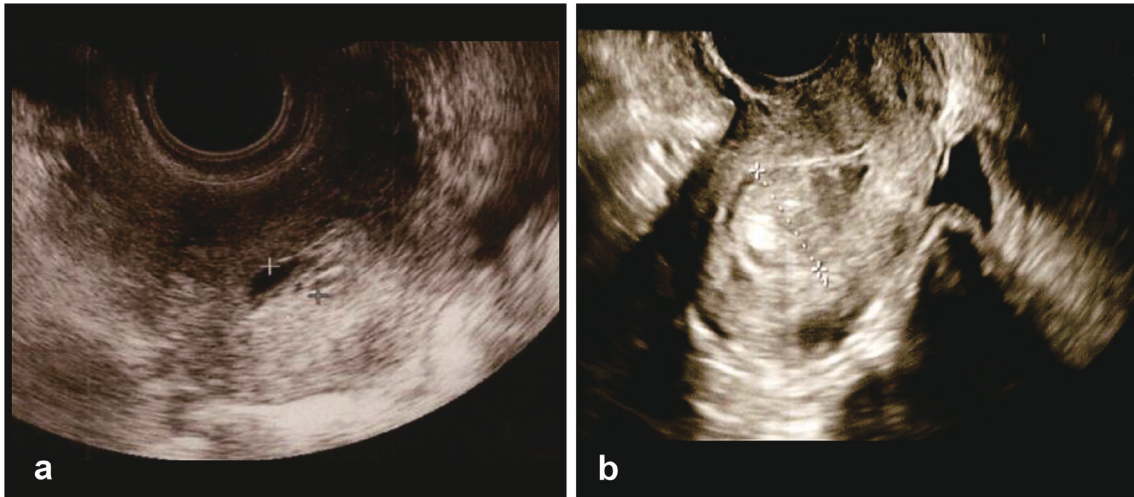


Fig. 3. Photographs of transvaginal ultrasonography after 1 day (a) and 6 days (b) from the transcervical resection of the endometrial polyp. A photograph taken on the sixth postoperative day shows a mass in the uterus that appears to be filled with a clot in the uterus (b).

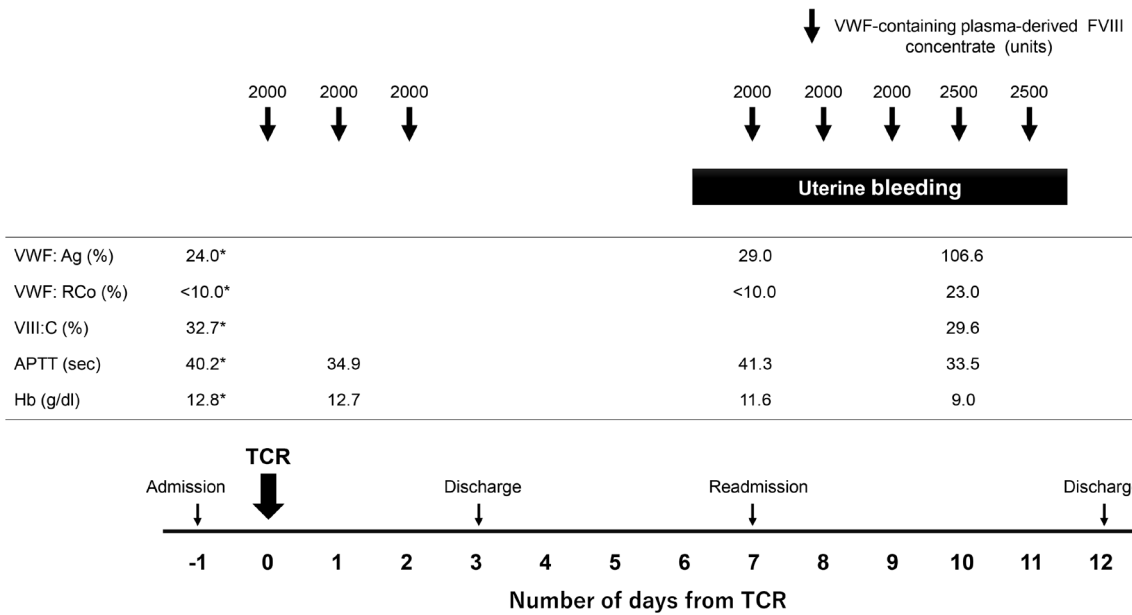


Fig. 4. A schematic clinical treatment course in an infertile woman with endometrial polyp complicated by von Willebrand disease. TCR : transcervical resection, VWF : von Willebrand factor, VWF : Ag : von Willebrand factor antigen, VWF : RCo : von Willebrand factor ristocetin cofactor activity, APTT : activated partial thromboplastin time, Hb : hemoglobin, FVIII : coagulation factor VIII.

sin acetate (DDAVP [1-desamino-8-D-arginine vasopressin]) and VWF-containing concentrate. Tranexamic acid, an antifibrinolytic solvent, is used to treat bleeding from mucous membranes with high fibrinolytic activity or to prevent rebleeding.

DDAVP acts on vasopressin V2 receptors on the membranes of renal collecting tubule cells to exert its antidiuretic effect and is used as a treatment for central diabetes insipidus. It also acts on vasopressin V2 receptors on vascular endothelial cells to promote VWF release from the endothelial cell

membrane<sup>18)</sup>. DDAVP is effective for VWD types 1 and 2 but not for type 3. DDAVP is an option for minor bleeding and minor surgery, although repeated dosing weakens its action<sup>11)</sup>.

Hemorrhage prophylaxis is necessary in patients with VWD who undergo surgery. Unlike DDAVP, VWF-containing concentrates can be used in many VWD patients undergoing surgery. The recommended dosage and duration of administration of VWF-containing concentrates depends on the extent of surgery. However, many criteria are empiri-

cal, and the guidelines do not specifically address surgery for uterine cavity lesions<sup>11,12,19</sup>.

To the best of our knowledge, there have been no case reports of delayed bleeding after hysteroscopic surgery for intrauterine lesions in women with VWD. In this case, the hysteroscopic procedure time was less than 30 min, and it was classified as a minor surgery; however, considering the risk of bleeding, a VWF/pd-FVIII concentrate instead of DDAVP was used for hemorrhage prophylaxis. According to the guidelines, the recommended duration of use of VWF-containing concentrates during minor surgery is 1-5 days, although a longer or shorter period may be considered in each case<sup>11,12,19</sup>. In this case, the VWF/pd-FVIII concentrate was used for 3 days during the perioperative period; however, bleeding from the uterus was observed on postoperative day 6. Although the cause of rebleeding is unknown, additional DDAVP or tranexamic acid may have been required following administration of the VWF/pd-FVIII concentrate after discharge.

Hemostasis for bleeding from the vessel wall consists of the interaction between the vessel endothelium and platelets, and the coagulation cascade. In reproductive-aged women, the hemostatic mechanism for bleeding from the uterine lumen is essentially the same as that for blood vessels in other organs; however, it is controlled by tissue factor (TF) and ovarian steroid hormones<sup>20</sup>. The uterine endometrium undergoes repeated proliferation and shedding during the menstrual cycle, and is classified into proliferative, secretory, and menstrual phases<sup>21</sup>. During the proliferative phase, tissue plasminogen activator (t-PA) in the uterine endometrium, which enhances the fibrinolytic system, is up-regulated by estrogen<sup>20</sup>. During the secretory phase, progesterone increases the expression of TF and plasminogen activator inhibitor (PAI-1), which inhibits the conversion of plasminogen to plasmin in the uterine endometrium. Regulation of the expression of these factors related to hemostasis in the uterine endometrium by ovarian steroid hormones is important not only to prevent menstrual blood clotting but also to maintain pregnancy<sup>20,21</sup>.

The hemostatic mechanism after intrauterine lesion excision is also presumed to be influenced by ovarian hormones. When blood vessels are injured by the removal of intrauterine lesions and blood is exposed to endometrial tissue TF, platelets are activated and cooperate with VWF to aggregate on the vessel wall, resulting in primary hemostasis. A cascade of coagulation factors converts fibrinogen to

fibrin, thereby completing secondary hemostasis. In the present case, the patient received five courses of GnRH agonist treatment before surgery. Although the actual measurement of ovarian steroid hormones was not obtained in this case, estrogen and progesterone levels were likely low because the effects of GnRH agonists usually last for about a month<sup>22</sup>. One possibility for post-operative uterine bleeding in this case could be low levels of ovarian steroid hormones. Low progesterone levels may have resulted in low TF and PAI-1 expression in the endometrium, and secondary hemostasis with coagulation factors may have been inadequate. In addition, the amount of t-PA may have increased in the endometrium and the fibrinolytic activity was enhanced<sup>20,21</sup>. Taken together, delayed hemostasis due to low ovarian steroid hormone levels and high fibrinolysis activity may have contributed to the bleeding on postoperative day 6, despite the use of VWF-containing concentrate to prevent postoperative bleeding in this patient.

During the removal of intrauterine lesions in patients with VWD, a prolonged low estrogen status with preoperative GnRH agonist administration may be a risk factor for postoperative bleeding. For surgery of intrauterine lesions in patients with VWD, it may be better to avoid preoperative administration of hormonal agents or, if administered, agents, such as GnRH antagonists or progestins that lead to a rapid recovery in estrogen levels after administration is discontinued, should be used.

GnRH agonist was used for excessive menstruation due to VWD and as a preoperative medication for endometrial polyps, enabling menstruation cessation and improving the visual field during surgery. However, the use of GnRH agonist is associated with an increase in estrogen around 2 weeks after administration, known as a "flare-up" effect, which may cause irregular genital bleeding. When using GnRH agonists to cease menstruation during chemotherapy for malignant hematologic diseases, concurrent administration of progestin is carried out both to prevent flare-ups and to stop bleeding, with favorable outcomes reported<sup>23</sup>. Considering the risk of irregular bleeding, the currently available oral GnRH antagonist may be suitable for preoperative administration since it does not cause a flare-up. Future studies on preoperative medication before intrauterine surgery in patients with coagulopathy may be warranted.

We prioritized coagulation factor products for postoperative rebleeding, but mechanical compression with an intrauterine balloon is also an op-

tion. It is effective for primary heavy bleeding during hysteroscopic surgery. In the present case, the patient was infertile, which was the reason why we did not choose the intrauterine balloon method of compression for delayed postoperative rebleeding. Because repeated intrauterine manipulation increases the risk of intrauterine adhesions<sup>24)</sup>, medical treatment with the use of coagulation factor preparations was given priority. If bleeding persisted despite the use of coagulation factor preparations, intrauterine balloon compression was the next option. A two-tiered approach using coagulation factor products and mechanical compression is ideal for rebleeding after hysteroscopic surgery in patients with coagulation abnormalities.

In conclusion, when performing resection for intrauterine lesions in women with VWD, there is a risk of rebleeding a few days after surgery, even with bleeding prophylaxis, according to the guidelines. As the hemostatic mechanism of the endometrium is affected by ovarian steroid hormones, delayed postoperative bleeding should be considered when preoperative hormone therapy is used.

## References

- Laffan M, Sathar J, Johnsen JM. Von Willebrand disease : diagnosis and treatment, treatment of women, and genomic approach to diagnosis. *Haemophilia*, **27** : 66-74, 2021.
- Weyand AC, Flood VH. Von Willebrand disease : current status of diagnosis and management. *Hematol Oncol Clin North Am*, **35** : 1085-1101, 2021.
- Harris NS, Pelletier JP, Marin MJ, Winter WE. Von Willebrand factor and disease : a review for laboratory professionals. *Crit Rev Clin Lab Sci*, **59** : 241-256, 2022.
- Deligeoroglou E, Karountzos V. Abnormal uterine bleeding including coagulopathies and other menstrual disorders. *Best Pract Res Clin Obstet Gynaecol*, **48** : 51-61, 2018.
- De Wee EM, Knol HM, Mauser-Bunschoten EP, *et al.* Gynaecological and obstetric bleeding in moderate and severe von Willebrand disease. *Thromb Haemost*, **106** : 885-892, 2011.
- Committee on Adolescent Health C, Committee on Gynecologic P. Committee Opinion No.580 : von Willebrand disease in women. *Obstet Gynecol*, **122** : 1368-1373, 2013.
- Castaman G, James PD. Pregnancy and delivery in women with von Willebrand disease. *Eur J Haematol*, **103** : 73-79, 2019.
- Bosteels J, van Wessel S, Weyers S, *et al.* Hysteroscopy for treating subfertility associated with suspected major uterine cavity abnormalities. *Cochrane Database Syst Rev*, **12** : CD009461, 2018.
- Lieng M, Istre O, Qvigstad E. Treatment of endometrial polyps : a systematic review. *Acta Obstet Gynecol Scand*, **89** : 992-1002, 2010.
- Aas-Eng MK, Langebrekke A, Hudelist G. Complications in operative hysteroscopy - is prevention possible? *Acta Obstet Gynecol Scand*, **96** : 1399-1403, 2017.
- Nichols WL, Hultin MB, James AH, *et al.* von Willebrand disease (VWD) : evidence-based diagnosis and management guidelines, the National Heart, Lung, and Blood Institute (NHLBI) Expert Panel report (USA). *Haemophilia*, **14** : 171-232, 2008.
- James PD, Connell NT, Ameer B, *et al.* ASH ISTH NHF WFH 2021 guidelines on the diagnosis of von Willebrand disease. *Blood Adv*, **5** : 280-300, 2021.
- Pallikadavath S, Watts J, Sandilands AJ, Gay S. An algorithm to assist novices with electrocardiogram interpretation : validation with the Delphi Method. *J Electrocardiol*, **70** : 56-64, 2022.
- Werner EJ, Broxson EH, Tucker EL, Giroux DS, Shults J, Abshire TC. Prevalence of von Willebrand disease in children : a multiethnic study. *J Pediatr*, **123** : 893-898, 1993.
- Bowman M, Hopman WM, Rapson D, Lillicrap D, James P. The prevalence of symptomatic von Willebrand disease in primary care practice. *J Thromb Haemost*, **8** : 213-216, 2010.
- Haamid F, Sass AE, Dietrich JE. Heavy menstrual bleeding in adolescents. *J Pediatr Adolesc Gynecol*, **30** : 335-340, 2017.
- Borzutzky C, Jaffray J. Diagnosis and management of heavy menstrual bleeding and bleeding disorders in adolescents. *JAMA Pediatr*, **174** : 186-194, 2020.
- Kaufmann JE, Vischer UM. Cellular mechanisms of the hemostatic effects of desmopressin (DDAVP). *J Thromb Haemost*, **1** : 682-689, 2003.
- Castaman G, Goodeve A, Eikenboom J, European Group on von Willebrand D. Principles of care for the diagnosis and treatment of von Willebrand disease. *Haematologica*, **98** : 667-674, 2013.
- Swaminathan N, Sharathkumar A, Dowlut-McElroy T. Reproductive tract bleeding in adolescent and young adult females with inherited bleeding disorders : an underappreciated problem. *J Pediatr Adolesc Gynecol*, **35** : 614-623, 2022.
- Critchley HOD, Maybin JA, Armstrong GM, Williams ARW. Physiology of the endometrium and regulation of menstruation. *Physiol Rev*, **100** : 1149-1179, 2020.



22. Larmore KA, Klein KO. Estradiol suppression and recovery during leuprolide acetate treatment in women as determined weekly by an ultrasensitive recombinant cell bioassay. *Gynecol Endocrinol*, **14** : 405-410, 2000.
23. Lhomme C, Brault P, Bourhis JH, Pautier P, Doholou N, Dietrich PY, Akbar-Zadeh G, Lucas C, Pico JL, Hayat M. Prevention of menstruation with leuprorelin (GnRH agonist) in women undergoing myelosuppressive chemotherapy or radiochemotherapy for hematological malignancies : a pilot study. *Leuk Lymphoma*, **42** : 1033-1041, 2001.
24. Khan Z. Etiology, Risk Factors, and Management of Asherman Syndrome. *Obstet Gynecol*, 2023.