Title	Can 3D-CT angiography (3D-CTA) replace conventional catheter angiography in ruptured aneurysm surgery? Our experience with 162 cases
Author(s)	Matsumoto, Masato; Kasuya, Hiromichi; Sato, Taku; Endo, Yuji; Sakuma, Jun; Suzuki, Kyouichi; Sasaki, Tatsuya; Kodama, Namio
Citation	Fukushima Journal of Medical Science. 53(2): 85-94
Issue Date	2007-12
URL	http://ir.fmu.ac.jp/dspace/handle/123456789/213
Rights	© 2007 The Fukushima Society of Medical Science
DOI	10.5387/fms.53.85
Text Version	publisher

Fukushima J. Med. Sci.,
Vol. 53, No. 2, 2007

[**Original Article**]

CAN 3D-CT ANGIOGRAPHY (3D-CTA) REPLACE CONVENTIONAL CATHETER ANGIOGRAPHY IN RUPTURED ANEURYSM SURGERY ? OUR EXPERIENCE WITH 162 CASES

MASATO MATSUMOTO, HIROMICHI KASUYA, TAKU SATO, YUJI ENDO, JUN SAKUMA, KYOUICHI SUZUKI, TATSUYA SASAKI and NAMIO KODAMA

Department of Neurosurgery, Fukushima Medical University, Fukushima, 960-1295, Japan

(Received April 24, 2007, accepted October 4, 2007)

Abstract: In this communication, we studied whether 3D-CT angiography (3D-CTA) gives us enough information for a safe operation without those from conventional catheter angiography (CCA) in patients with ruptured aneurysms.

Between December 1996 and September 2005, we treated 162 consecutive patients with ruptured aneurysms in the acute stage based on 3D-CTA findings. One hundred sixty-two ruptured aneurysms, including 64 associated unruptured aneurysms, were detected using 3D-CTA. CCA was performed in nine (5.6%) of the 162 patients after 3D-CTA. They were four dissecting vertebral artery aneurysms, two basilar tip aneurysms, one basilar artery-superior cerebellar artery (BA-SCA), one previously clipped BA-SCA and one internal carotid-posterior communicating artery aneurysm. All ruptured aneurysms confirmed at surgery were treated successfully. The lack of information on CCA did not lead any neurological deficits or difficulties in the surgical procedure.

3D-CTA was of high diagnostic value compatible with CCA and yielded important information such as the configuration of the aneurysmal sac and neck, calcification in the aneurysmal wall, and the aneurysms' anatomic relation with adjacent vessels and bone structures. We suggest that 3D-CTA can replace CCA in the diagnosis of ruptured aneurysms and that most of ruptured aneurysms can be operated by using only 3D-CTA without CCA.

Key words: Cerebral aneurysm, 3D-CTA, Surgery

松本正人，粕谷泰道，佐藤　拓，遠藤雄司，佐久間潤，鈴木恭一，佐々木達也，児玉南海雄
Corresponding author: Masato Matsumoto　E-mail: mat@fmu.ac.jp

INTRODUCTION

In 1927, roentgenologic imaging of cerebral vessels with contrast medium first introduced by a Portuguese neurologist, Egas Moniz[1], remains the diagnostic gold standard in the field of neurosurgery. Initially, the cerebral angiography was performed by percutanenous direct puncture of the cervical carotid artery or vertebral artery. Later, the cerebral angiographs were obtained by puncturing the femoral artery and inserting a catheter; this less invasive method is now routinely applied in the diagnosis of central nervous system disorders[2]. Although the introduction of non-ionic contrast material decreased the incidence of side effects, the patients undergoing the cerebral angiography require anesthesia and bed rest for a few hours after the examination. Even when skilled examiners perform it with great care, the rate of complications has been reported to be 0.25 to 1%[3,4] and is higher in elderly patients[5]. Bendszus *et al.* documented that diffusion-weighted MRI performed immediately after conventional catheter angiography (CCA) depicted silent embolisms in approximately 26% of patients[6], indicating that the complication rate of CCA were more frequent than that of the apparent neurological deficits.

Dramatic improvements in the image quality of MR and 3D-CT angiography (MRA, 3D-CTA) resulted in improved diagnostic accuracy. The ability to diagnose cerebral aneurysms is reported to be 90-97%[7,8] on MRA and 95-100%[9-11] on 3D-CTA. In the acute stage of subarachnoid hemorrhage (SAH), MRA is less appropriate than 3D-CTA because it involves a longer examination time, necessitates moving the patient to an MRI table after the acquisition of unenhanced CT scans, raises the possibility of missing large aneurysms due to turbulence or low blood flow in the vascular lumen, and does not yield images of bone. Therefore, as the information on MRA is not satisfactory, we consider 3D-CTA a more suitable modality in patients scheduled for aneurysm surgery. Recently, in some institutions, the ruptured aneurysm surgery is performed on the basis of 3D-CTA findings alone[8,11-13].

In our preliminary study, we evaluated 60 patients with ruptured aneurysms prospectively evaluated with both 3D-CTA and CCA, with 3D-CTA we detected all the ruptured aneurysms that we did with CCA, and demonstrated 100% diagnostic accuracy in ruptured aneurysms[14]. Based on this high sensitivity and specificity of 3D-CTA in the cerebral aneurysm detection, we have performed aneurysm surgery on the basis of 3D-CTA findings alone. In the present study, we discuss whether 3D-CTA can replace CCA in the examination of patients with ruptured cerebral aneurysms and whether the surgery can be performed safely based on 3D-CTA findings alone.

MATERIALS AND METHODS

Between December 1996 and September 2005, 167 patients with subarachnoid hemorrhage (SAH) were admitted to our hospital. Of the 167 patients, five were excluded from this study because their condition was too critical for us to perform 3D-CTA. Therefore, the population enrolled in this study was 162 patients. Sixty-three were man and 99 were woman whose ages ranged from 25 to 90 years. Informed consent was obtained from the patients or their relatives if the patients had difficulty in responding on their own. Each patient's clinical condition was classified just prior to surgery on the World Federation of Neurosurgical Societies grading scale[14] (Table 1).

We have performed surgery for 162 patients with ruptured aneurysm based on information acquired by 3D-CTA alone. The scans were obtained within 24 hours of the initial bleed and all ruptured aneurysms were surgically treated within 72 hours after the bleeding onset.

Of the 162 patients, 105 were scanned with a helical CT scanner (X vigor; Toshiba Corp., Tokyo, Japan; December 1996-December 2000) and the other 57 were done with a helical CT scanner (Aquilion; Toshiba Corp., Tokyo, Japan; January 2001-September 2005). All patients were first evaluated with an unenhanced CT scan immediately followed by a helical CT scan. During unenhanced and helical CT scanning, mild sedative drugs were given to patients who were unable to remain at rest during the examinations. The scan parameters were as follows: 135 kV; 200 mA or 260 mA; 1 or 0.5-mm slice thickness; 1 mm/sec or 0.5 mm/sec table speed; 0.5 mm or 0.3 mm reconstruction pitch; and 180 degree reconstruction interposition. Nonionic contrast medium (Iomeprol [Iomeron, 350 mg/ml] or Iopamidol [Iopamilon, 370 mg/ml]) was injected continuously at a rate of 3 ml/

Table 1. Clinical status of 162 consecutive patients

Clinical Characteristics		Value
age(yrs)		
	range	25-90
sex		
	male	63
	female	99
WFNS grade		
	I	75
	II	33
	III	17
	IV	32
	V	5

WFNS=World Federation of Neurological Societies

second for a total volume of 100 ml, through a 20-gauge needle inserted in the antecubital vein by a power injector (Nemoto Kyorindo, Tokyo, Japan). The scanning started 20 seconds after the initiation of injection. Source images thus obtained were transferred to the workstation (X Link ; Toshiba Corp., or Zaio M 900 : Ziosoft Inc., Tokyo, Japan) dedicated to the helical CT scanner. More than two senior neurosurgeons diagnosed the presence and location of cerebral aneurysms. The diagnosis of a ruptured aneurysm was confirmed by operative findings, and its size was measured directly during the operation. The size of unruptured aneurysms that were not confirmed at surgery was measured on 3D-CTA.

CCA (ANGIOREX CAS-RA ; December 1996-November 2002, Infimix Celeve VS ; December 2002-September 2005, Toshiba Corp., Tokyo, Japan) was performed by use of the transfemoral Seldinger technique with an image intensifier matrix of 1,024×1,024 pixels. Anteroposterior and lateral views were routinely obtained. When necessary, additional projections were also obtained.

Table 2. Distribution and size of cerebral aneurysms in 162 consecutive patients

Site & Size	Ruptured	Unruptured
Site		
ICA bifurcation	4	2
ICA-PCoA	32	10
ICA-AChA	6	2
ACoA	32	10
distal ACA	6	1
MCA	45	26
BA tip	7	4
BA-SCA	3	1
VA-PICA	5	1
VA dissecting	7	0
Others	15	7
Size (mm)		
< 5	47	56
≦ 5 to < 10	84	6
≦10 to < 15	25	2
≦15 to < 20	5	0
≦20 to < 25	1	0

ICA = internal carotid artery, PCoA = posterior communicating artery, AChA = anterior choroidal artery, ACoA = anterior communicating artery, ACA = anterior cerebral artery, MCA = middle cerebral artery, BA = basilar artery, SCA = superior cerebellar artery, VA = vertebral artery, PICA = posterior inferior cerebellar artery

RESULTS

Using 3D-CTA, we detected 162 ruptured and 64 unruptured aneurysms. The distribution of the aneurysms' location and size are shown in Table 2. All ruptured aneurysms were confirmed at surgery and successfully treated. At surgery, we also confirmed the presence of 42 of 64 unruptured aneurysms detected on 3D-CTA. The remaining 22 unruptured aneurysms were not verified because the operative field for ruptured aneurysms was not the same as that for unruptured aneurysms. Comparing to the intraoperative findings, there were no false negative cases on 3D-CTA. CCA was performed in nine (5.6%) of the 162 patients after 3D-CTA. The reasons why CCA was needed were as follows. In four patients with dissecting vertebral artery (VA) aneurysms, we needed information on true and false lumens of the VA aneurysm that 3D-CTA had not provided. In two patients with a basilar tip aneurysm, CCA was performed to acquire the information on the perforators arising from the tip of the basilar artery because 3D-CTA was not able to visualize them. However, the surgery for basilar bifurcation aneurysms has been performed on the basis of 3D-CTA alone since we understood that we could confirm the perforators during surgery. In one patient who had a 0.8-mm basilar artery-superior cerebellar artery (BA-SCA) aneurysm detected on targeted 3D-CTA, CCA was performed to confirm this finding (Fig. 1). One patient with prior surgery for a ruptured BA-SCA aneurysm was admitted with recurrent SAH. As 3D-CTA failed to demonstrate the entire shape of aneurysm due to clip-induced artifact, we added CCA to obtain this information (Fig. 2). Lastly, in the case of an internal carotid-posterior communicating artery aneurysm, motion artifact rendered the diagnosis on 3D-CTA scans difficult ; the necessary information was demonstrated on CCA. By suppressing the patient's head, 3D-CTA depicted the aneurysm (Fig. 3).

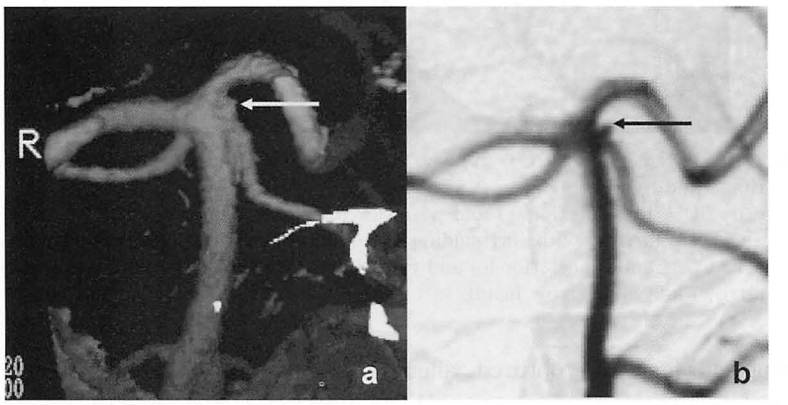

Fig. 1. a : 3D-CTA, anterior view, demonstrating a small basilar-superior cerebellar artery aneurysm (arrow).
b : CCA demonstrating an aneurysm (arrow).

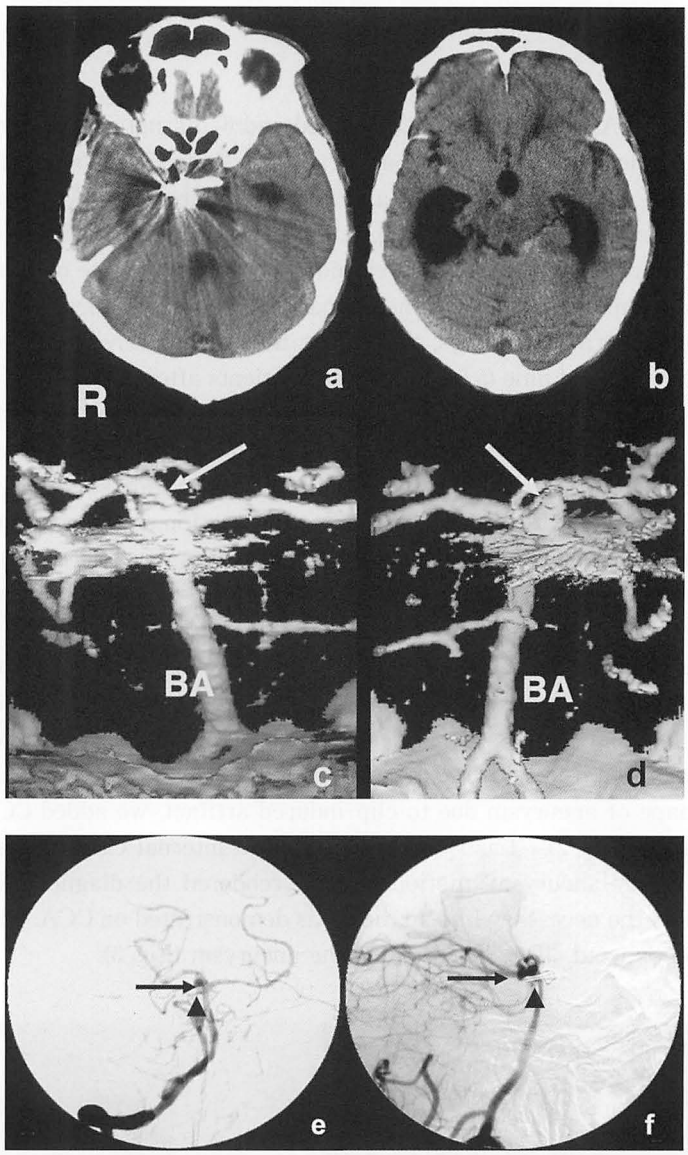

Fig. 2. a, b : Unenhanced CT showing clip-induced artifacts, subarachnoid hemorrhage and hydrocephalus.
c, d : 3D-CTA, anterior (c) and posterior (d) views, demonstrating a part of an aneurysm (arrow) with surrounding clip-induced artifacts. BA = basilar artery
e, f : CCA, anteroposterior (e) and right lateral (f) views, showing the aneurysm (arrow) and clip (arrow head)

During surgery of ruptured aneurysms, we did not encounter incidental unruptured aneurysms that might not have been visualized on 3D-CTA. The lack of information on CCA did not induce any neurological deficits or difficulties in the surgical procedure. There were no complications associated with the performance

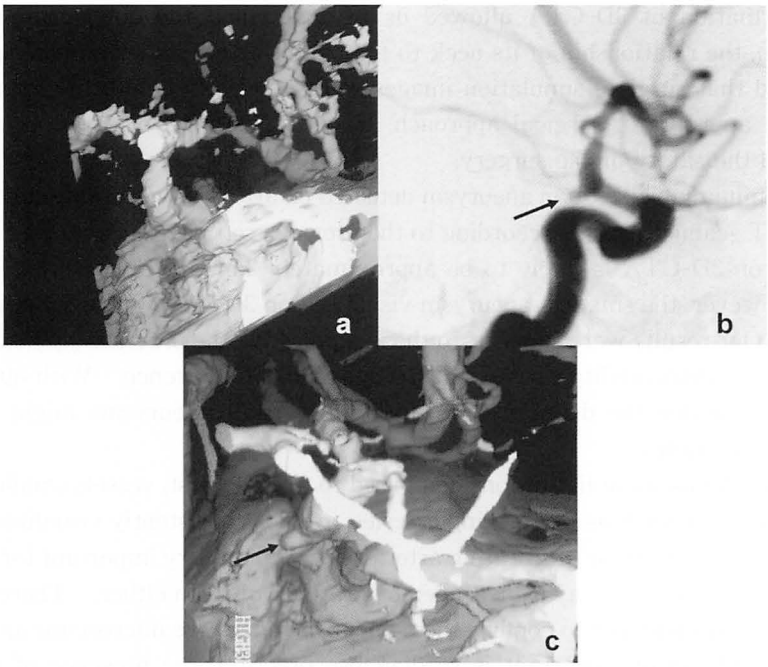

Fig. 3. a : Diagnosis of the aneurysm was difficult on 3D-CTA (right lateral view) due to patient's movement.
b : CCA (right lateral view) showing an internal carotid-posterior communicating artery aneurysm (arrow).
c : 3D-CTA (right lateral view) obtained by using a head holder, clearly demonstrated the aneurysm (arrow).

of 3D-CTA.

DISCUSSION

Patients with ruptured cerebral aneurysms require a quick and accurate diagnosis and appropriate management. 3D-CTA produced the three-dimensional vascular images within approximately 15 minutes by scanning with an intravenous injection of contrast medium. The omission of the cerebral angiography decreased the time between arrival at the hospital and surgery to an average of 90 min. Early surgery prevents rebleeding and facilitates subsequent aggressive therapy to avoid vasospasm.

For aneurysm surgery based on 3D-CTA findings alone, high diagnostic accuracy compatible with conventional angiography is definitely required. In our preliminary study, all the ruptured aneurysms detected on 3D-CT angiography were confirmed at surgery[13,15]. This study indicated that the diagnostic accuracy of the 3D-CTA for ruptured aneurysms based on the intraoperative findings was 100%, therefore, the diagnostic ability of the 3D-CTA is comparable to CCA.

Information of 3D-CTA allowed us to understand the configuration of the aneurysm, the relationship of its neck to the parent artery and surrounding vessels. We found that surgical simulation images were especially helpful for determining the most appropriate surgical approach, for intraoperative orientation, and they increased the safety of the surgery.

The minimum size of an aneurysm detected on 3D-CTA varies depending on the helical CT scanner used. According to the previous reports, the smallest aneurysm detected on 3D-CTA is likely to be approximately 2 mm in diameter[16,17]. In our series, however, the smallest aneurysm visualized on 3D-CTA was 0.8 mm in diameter[13,15]. Our results were superior to those reported in the previous studies. These variations in detectability may be caused by technical difference. With our experience and practice the diagnostic sensitivity for small aneurysms might improve diagnostic accuracy.

3D-CTA has some limitations compared to CCA. First, vessels smaller than 1 mm in diameter, such as perforating arteries, are not consistently visualized on 3D-CTA. To identify these perforating arteries is certainly very important for surgery, however, CCA is not always able to demonstrate all of them either. Therefore, the surgeons must endeavor to confirm them under the operative microscope as much as possible. The most important is to diagnose precisely the presence of ruptured aneurysms without fail. Second, 3D-CTA does not supply dynamic information of the cerebral circulation, such as collateral flow. Last, the aneurysms located close to the skull base may not be visible against the bony structures, which is a disadvantage when using 3D-CTA, but the findings of the three-dimensional anatomical relation of the aneurysm to the skull can be an advantage for surgery.

Considering the aforementioned characteristics of 3D-CTA, we believe that surgery for almost all the ruptured aneurysms can be performed using 3D-CTA, except for the following cases in which CCA is required. 1) In patients in whom cerebral infarction is shown on unenhanced CT, CCA is required to evaluate stenoses or occlusions of the intracranial arteries, cervical carotid or vertebral arteries. 2) In patients with giant or large aneurysms scheduled for bypass surgery, the hemodynamic information provided by CCA is necessary. Likewise, CCA is needed to acquire information on perforating arteries surrounding the aneurysm because it is difficult to identify these vessels during surgery. 3) For the aneurysms close to bony structures, such as cavernous portion aneurysms, CCA is necessary to obtain precise diagnosis. 4) In patients with dissecting aneurysms, CCA findings of true and false lumen are needed for surgical treatment. 5) If there is a discrepancy between the distribution of SAH on unenhanced CT findings and the location of the aneurysm on 3D-CTA, it is necessary to rule out the presence of another aneurysm in the area of the hemorrhage.

Hoh *et al.* reported that 88 of 109 SAH patients (81%) could be operated based on 3D-CTA findings alone[11]. In 16 (15%) of patients, they performed CCA to obtain additional information on the anatomy of the aneurysm, particularly its neck and

relationship to adjacent vessels. In 5 (5%), they required CCA because 3D-CTA failed to reveal cerebrovascular lesions. However, CCA also demonstrated no cerebrovascular lesions. We propose that CCA can be omitted because we are able to confirm the information on the aneurysm neck and the relationship to adjacent vessels during surgery. In the series reported by Hoh *et al.* the proportion of patients operable based on 3D-CTA findings alone was smaller than in our study[11]. In our experience, the lack of the information did not lead to difficulties in surgical procedures and affect the surgical outcomes. Ours is the first large series of operated patients with ruptured cerebral aneurysms that demonstrates a high rate of success with a prospective protocol that replaces CCA with 3D-CTA.

The diagnostic value of 3D-CTA was compatible with CCA. 3D-CTA studies yielded useful information for aneurysm surgery. Based on our findings, we suggest that 3D-CTA can replace CCA in the diagnosis of ruptured aneurysms and that surgery can be performed in almost all ruptured aneurysms by using only 3D-CTA without CCA.

REFERENCES

1. Moniz E. Liencephalograhie arterielle, son importance dans la location des tumeurs cerebrales. Rev Neurol, **2**: 72-90, 1927.
2. Seldinger SI. Catheter replacement of the needle in percutanenous arteriography: A new technique. Acta Radiol, **39**: 368-376, 1953.
3. Heiserman JE, Dean BI, Hodak JA, Flom RA, Bird CR, Drayer BP, Fram EKl. Neurologic complications of cerebral angiography. AJNR Am J Neuroradiol, **15**: 1401-1407, 1994.
4. Waugh JR, Sacharias N. Angiographic complications in the DSA era. Radiology, **18**: 243-246, 1992.
5. Earnest F IV, Forbes G, Sandok BA, Piepgras DG, Faust RJ, Iistrup DM, Arndt LJ. Complications of cerebral angiography prospective assessment of risk. AJR, **142**: 247-253, 1984.
6. Bendszus M, Koltzenburg M, Burger B, Warmuth-Metz M, Hofmann E, Solymosi L. Silent embolism in diagnostic cerebral angiography and neurointerventional procedures: a prospective study. The Lancet, **354**: 1594-1597, 1999.
7. Chung TS, Joo JY, Lee SK, Chien D, Laub G. Evaluation of cerebral aneurysms with high-resolution MR angiography using a section interpolation technique: Correlation with digital subtraction angiography. AJNR Am J Neuroraiol, **20**: 229-235, 1999.
8. Watanabe Z, Kikuchi Y, Izaki K, Hanyu N, Lim FSH, Gotou H, Koizumi J, Gotou T, Kowada M, Watanabe K. The usefulness of 3D MR angiography in surgery for ruptured cerebral aneurysms. Surg Neurol, **55**: 359-364, 2001.
9. Anderson GB, Steinke DE, Petruk KC, Ashforth R, Findlay JM. Computed tomographic angiography versus digital subtraction angiography for the diagnosis and early treatment of ruptured intracranial aneurysms. Neurosurgery, **45**: 1315-1323, 1999.
10. Hochmuth A, Spetzger U, Schmacher M. Comparison of three-dimensional rotational angiography with digital subtraction angiography in the assessment of ruptured cerebral aneurysms. AJNR Am J Neuroradiol, **23**: 1199-1205, 2002.
11. Hoh BL, Cheung AC, Rabinow JD, Pryor JC, Cater BS, Ogilvy CS. Results of a prospective protocol of computed tomographic angiography in place of catheter angiography as the only diagnostic and pretreatment planning study for cerebral aneurysms

by a combined neurovascular team. Neurosurgery, **54**: 1329-1342, 2004.

12. Velthuis BK, van Leeuwen MS, Witkamp TD, Ramos LMP, van der Sprenkei JWB, Rinkel GJE. Computerized tomography angiography in patients with subarachnoid hemorrhage: from aneurysm detection to treatment without conventional angiography. J Neurosurg, **91**: 761-767, 1999.
13. Matsumoto M, Sato M, Nakano M, Yuji Endo, Youichi Watanabe, Tatsuya Sasaki, Kyouichi Suzuki, Namio Kodama. Three-dimensional computerized tomography angiography-guided surgery of acutely ruptured cerebral aneurysms. J Neurosurg, **94**: 718-727, 2001.
14. Drake CG. Report of World Federation of Neurological Surgeons Committee on a Universal Subarachnoid Hemorrhage Grading Scale. J Neurosurg, **68**: 985-986, 1988.
15. Sato M, Yuji E, Matsumoto M, Sasaki T, Kodama N. Three-dimensional CT Angiography in acute cerebral aneurysm surgery. Jpn J Neurosurg (Tokyo), **10**: 18-26, 2001.
16. Nakajima Y, Yoshimne T, Yoshida H, Sakashita K, Okamoto M, Kishikawa M, Yagi K, Yokota J, Hayakawa T. Computerized tomography angiography of ruptured cerebral aneurysms: factors affecting time to maximum contrast concentration. J Neurosurg, **88**: 663-669, 1998.
17. Young N, Dorsch NWC, Kingston RJ, Soo MY, Robinsn A. Spiral CT scanning in the detection and evaluation of aneurysms of the circle of Willis. Surg Neurol, **50**: 50-61, 1998.