Title	Two cases of pancreatic abscess associated with penetration to the gastrointestinal tract during treatment using endoscopic ultrasound-guided drainage
Author(s)	Imamura, Hidemichi; Irisawa, Atsushi; Takagi, Tadayuki; Shibukawa, Goro; Wakatsuki, Takeru; Takahashi, Yuta; Sato, Ai; Sato, Masaki; Hikichi, Takuto; Obara, Katsutoshi; Ohira, Hiromasa
Citation	Fukushima Journal of Medical Science. 53(1): 39-49
Issue Date	2007-06
URL	http://ir.fmu.ac.jp/dspace/handle/123456789/207
Rights	© 2007 The Fukushima Society of Medical Science
DOI	10.5387/fms.53.39
Text Version	publisher

Fukushima J. Med. Sci.,
Vol. 53, No. 1, 2007

[**Case Report**]

TWO CASES OF PANCREATIC ABSCESS ASSOCIATED WITH PENETRATION TO THE GASTROINTESTINAL TRACT DURING TREATMENT USING ENDOSCOPIC ULTRASOUND-GUIDED DRAINAGE

HIDEMICHI IMAMURA[1], ATSUSHI IRISAWA[1], TADAYUKI TAKAGI[1], GORO SHIBUKAWA[1], TAKERU WAKATSUKI[1], YUTA TAKAHASHI[1], AI SATO[1], MASAKI SATO[1], TAKUTO HIKICHI[2], KATSUTOSHI OBARA[2] and HIROMASA OHIRA[1]

[1]*Department of Internal Medicine 2, Fukushima Medical University School of Medicine*
[2]*Department of Endoscopy, Fukushima Medical University Hospital*

(Received July 13, 2006, accepted December 20, 2006)

Abstract: Of pancreatic pseudocysts, approximately 30% are complicated by abscess formation, perforation into the abdominal cavity, penetration to the gastrointestinal tract, or bleeding. We report two cases of pancreatic abscess complicating severe acute pancreatitis in which the abscess penetrated to the gastrointestinal tract during the course of treatment with endoscopic ultrasound (EUS)-guided pseudocyst drainage. In these cases, neither aggravation nor recurrence of the pancreatic abscess has been identified since the event occurred. The EUS-guided treatment was effective for improvement of severe inflammation of the pseudocyst as an initial treatment. However, drainage tube placement limitations pertained because the pseudocyst was present with multilocular infection. Penetrations eventually contributed to their resolution because the fistulas were used as wide drainage routes. It is important to understand the courses of these cases for preparation of therapeutic strategies to treat pancreatic pseudocyst/abscess.

Key words: pancreatic pseudocyst, penetration, EUS-guided drainage

INTRODUCTION

Pancreatic pseudocysts, which contain pancreatic juice and effusion, are formed by pancreatic inflammation. A secondary pseudocyst develops in 10-15% of

今村秀道，入澤篤志，高木忠之，渋川悟朗，若槻　尊，髙橋裕太，佐藤　愛，佐藤匡記，引地拓人，小原勝敏，大平弘正
Correspondence to: Atsushi Irisawa, MD, PhD Department of Internal Medicine 2 Fukushima Medical University School of Medicine Hikarigaoka 1, Fukushima City, 960-1295, Japan.
E-mail: irisawa@fmu.ac.jp

patients with acute pancreatitis and chronic pancreatitis[1]. Of those, approximately 30% are complicated by abscess formation, perforation into the abdominal cavity, penetration to the gastrointestinal tract, or bleeding (gastrointestinal bleeding, intra-abdominal bleeding, intracystic bleeding)[2,3]. About 20-60% of pancreatic pseudocysts will disappear spontaneously. However, that rate falls to less than 10% for pseudocysts of 6 cm diameter or greater. Therefore, if a cyst is not reduced, even after the sixth week when the cyst wall starts to organize and adhere to surrounding organs, cyst drainage is indicated[4,5]. On the other hand, a pancreatic pseudocyst associated with infection or pancreatic abscess might cause sepsis and multi-organ failure. It might penetrate into the gastrointestinal tract, cause bleeding, and form a pseudo-aneurysm if inflammation spreads to surrounding organs. Consequently, for conservative treatment of uncontrolled intracystic infection, immediate drainage is required, even if in the early phase of pseudocyst formation.

We have recently experienced two cases of pancreatic abscess complicating severe acute pancreatitis in which the abscess penetrated to the gastrointestinal tract during treatment with endoscopic ultrasound (EUS)-guided pseudocyst drainage. In these cases, penetrations eventually contributed to their resolution because the fistulas were used as wide drainage routes. The courses of these cases should be understood for preparation of therapeutic strategies of pancreatic pseudocyst/abscess.

CASE REPORT

Case 1

A 65-year-old man was admitted to another hospital because of severe acute pancreatitis. Although the pancreatitis was relieved using various treatments, pancreatic pseudocyst developed around the pancreas. After eating was restarted, he displayed a high fever (39°C); infection of the pseudocyst was suspected. He was then referred to our hospital, to which he was admitted for treatment. Laboratory tests performed on admission indicated a severe inflammatory reaction with WBC of 21,200/μl and CRP of 12.7 mg/dl. Mild anemia, mild thrombocytopenia, liver dysfunction, and marked hypoalbuminemia were also indicated. Renal functions, blood glucose, serum AMY, and tumor markers were normal (Table 1). Abdominal CT showed a 12-cm-diameter abscess around the pancreatic tail and another abscess around the pancreatic head (Fig. 1). It was considered that immediate drainage for abscess should be done. Therefore, EUS-guided drainage was performed using a 19-gauge puncture needle (Echotip19G; Wilson-Hirata, Osaka, Japan) guided by ultrasound using a convex type echoendoscope (GF-UCT240AL-5; Olympus Medical Systems. Co., Tokyo, Japan) (Fig. 2a) with a transgastric approach. After puncture of the abscess, the needle stylet was removed. The aspirated fluid, viscous, white, and slightly bloody, was collected. A 0.025-inch guide wire (Jagwire; Boston Scientific Japan, Tokyo) was inserted into the needle

Table 1. Laboratory tests of Case 1 (on admission)

WBC	21,200/μl	TP	6.2 g/dl
RBC	$349\times10^4/\mu$l	ALB	1.6 g/dl
Hb	10.9 g/dl	BUN	18 mg/dl
Hct	32.9%	CREA	0.6 mg/dl
PLT	$13.8\times10^4/\mu$l	Na	137 mEq/l
		K	4.3 mEq/l
TB	1.6 mg/dl	Cl	102 mEq/l
DB	1.1 mg/dl	AMY	82 IU/l
AST	162 IU/l		
ALT	73 IU/l	BS	128 mg/dl
LDH	391 IU/l		
ALP	374 IU/l	CEA	1.5 ng/ml
γ-GTP	153 IU/l	CA19-9	29.1 U/ml

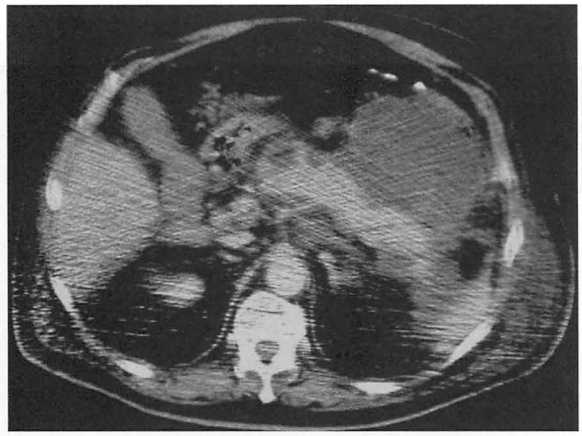

Fig. 1. Abdominal CT showed a 12-cm-diameter abscess around the pancreatic tail and another abscess around the pancreatic head in case 1.

and was advanced into the abscess. Then a 6 Fr endoscopic naso-biliary drainage (ENBD) tube (Flexima ; Boston Scientific Japan, Tokyo) was placed in the abscess over the guide wire (Fig. 2b). The abscess cavity was washed every day with saline mixed with amikacin sulfate. After this treatment, although the inflammatory reaction decreased and the patient's general condition improved, follow-up CT revealed residual abscess cavities. Two weeks after the drainage, hematochezia was observed. Emergent colonoscopy revealed two ulcerative lesions with mucosal edema in the transverse colon ; penetrations of pancreatic abscesses into the colon were suspected (Fig. 3). Images obtained by CT scanning revealed an abscess containing air near the pancreatic tail. Pseudo-aneurysm was not seen in the locations of the fistulas. Fortunately, apparent anemia and an inflammatory reac-

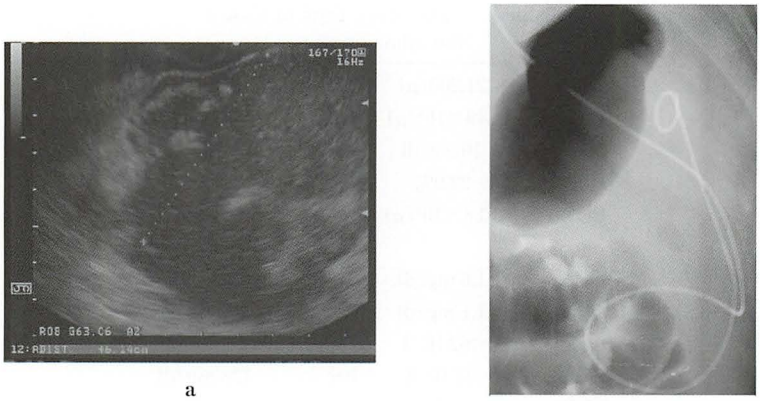

a b

Fig. 2. a : EUS-guided drainage was performed using a 19-gauge puncture needle guided by ultrasound using a convex type echoendoscope with the transgastric approach.
b : An endoscopic naso-biliary drainage (ENBD) tube was placed in the abscess.

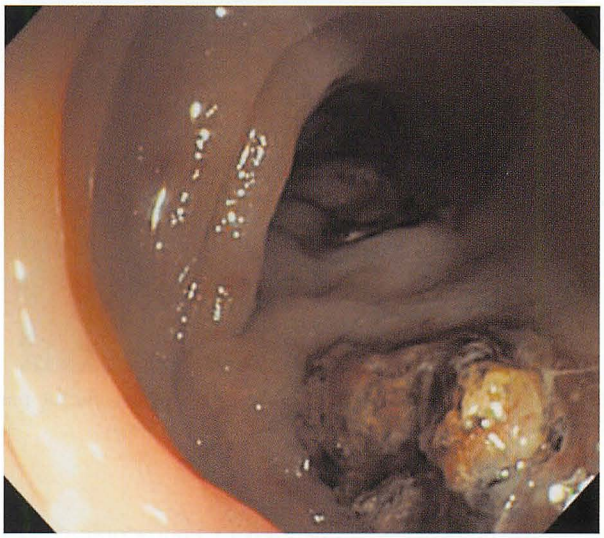

Fig. 3. Colonoscopy revealed two ulcerative lesions with mucosal edema in the transverse colon. Penetrations of pancreatic abscesses into the colon were suspected.

tion were not identified. Therefore, conservative treatments were performed. An abdominal CT scan performed 2 weeks after the hematochezia showed communication between the abscesses and the transverse colon, as well as the reduced abscesses (Fig. 4). Since the event occurred, neither aggravation nor recurrence of the pancreatic abscess has been identified.

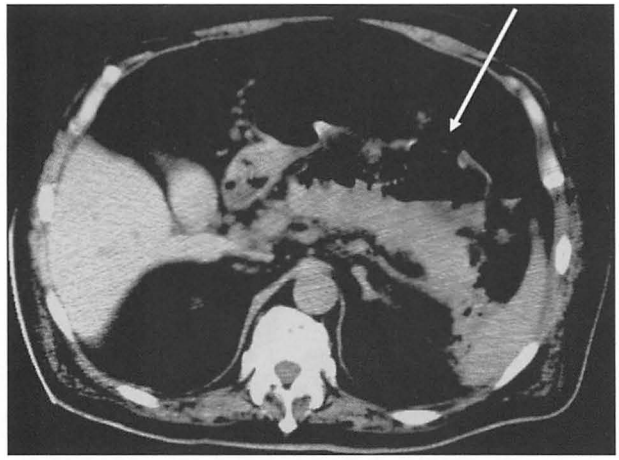

Fig. 4. An abdominal CT scan performed 2 weeks after hematochezia showed communication between the abscesses and the transverse colon (arrow), as well as the reduced abscesses.

Case 2

A 53-year-old man with a history of choledocholithiasis was admitted to another hospital with a diagnosis of severe acute alcoholic pancreatitis. The pancreatitis was relieved through treatment with protease inhibitors and antibiotics under a fasting condition. Nevertheless, the patient developed a fever of 39°C and abdominal pain. Abdominal CT images suggested infection of a pancreatic pseudocyst associated with acute pancreatitis. For treatment, he was referred to our hospital. On admission, laboratory tests showed WBC of 9,900/μl, CRP of 11.8 mg/dl, mild anemia, thrombocytosis, and mild liver dysfunction. Renal function

Table 2. Laboratory tests of Case 2 (on admission)

WBC	9,900/μl	TP	7.2 g/dl
RBC	$376\times10^4/\mu$l		
Hb	11.9 g/dl	BUN	12 mg/dl
Hct	33.7%	CREA	0.6 mg/dl
PLT	$51.7\times10^4/\mu$l	Na	133 mEq/l
		K	4.7 mEq/l
TB	0.5 mg/dl	Cl	97 mEq/l
DB	0.3 mg/dl	AMY	111 IU/l
AST	23 IU/l		
ALT	25 IU/l	BS	140 mg/dl
LDH	251 IU/l		
ALP	479 IU/l		

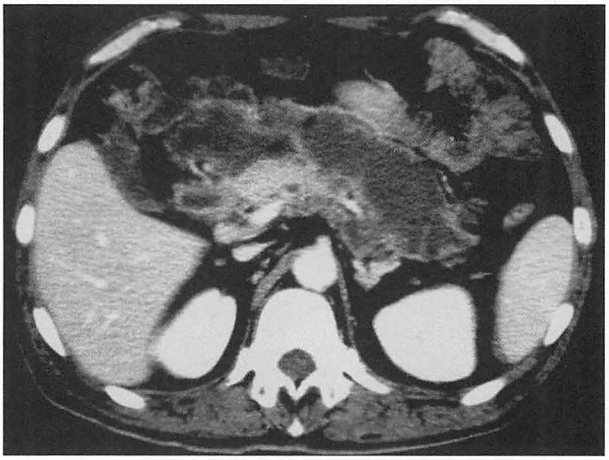

Fig. 5. Abdominal CT revealed extensively developed abscesses in case 2.

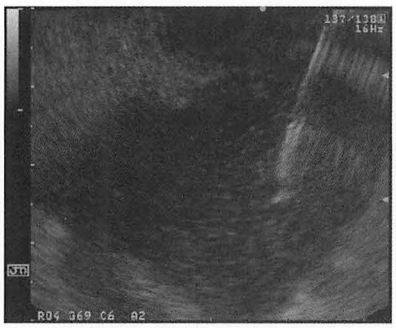

a

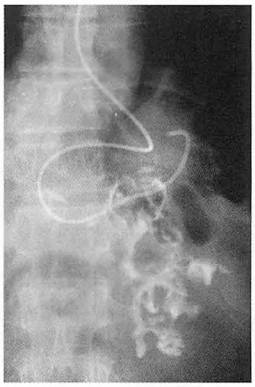

b

Fig. 6. a : EUS-guided drainage was done using the same procedure as that used in "case 1".
b : ENBD tube was indwelled in the abscess.

and serum AMY were normal ; a marked increase of blood glucose was not observed (Table 2). Abdominal CT revealed extensively developed abscesses around the pancreas (Fig. 5). It was considered that immediate drainage should be performed. Therefore, EUS-guided drainage was performed using the same procedure as that used in "case 1" (Fig. 6a). Yellow and white pus was aspirated from the abscess. At that time, a 6 Fr ENBD tube (Flexima ; Boston Scientific Japan, Tokyo) was indwelled in the abscess (Fig. 6b). The abscess cavity was washed through the tube daily with saline mixed with amikacin sulfate. Improvement of fever and the inflammatory reaction were apparent after the drainage. Two weeks later, X-ray fluoroscopic examination was done by injection of contrast medium via

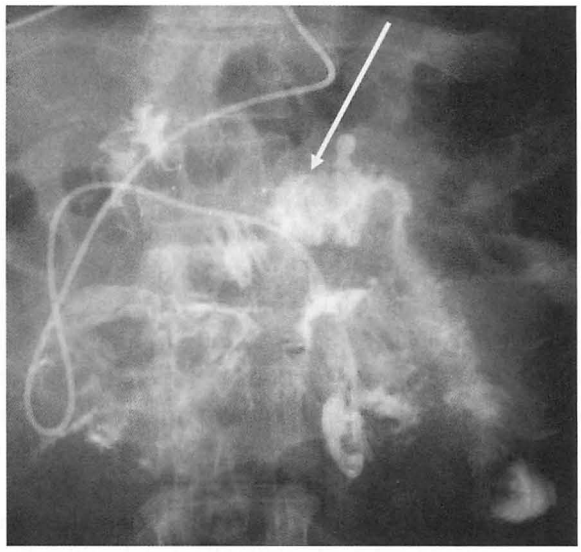

Fig. 7. On the fluoroscopic image, the small intestine was visualized in images taken inside of the abscess cavity (arrow), suggesting that the pancreatic abscess had penetrated into the small intestine.

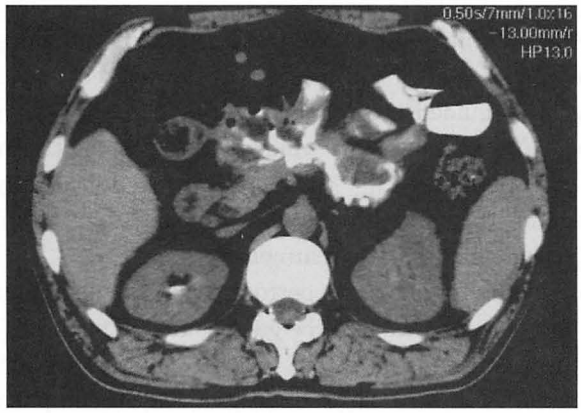

Fig. 8. Abdominal CT showed the reduced pancreatic abscess. Contrast medium was recognized in the small intestine and the abscess cavity.

an ENBD tube to decrease the pancreatic abscess. Then, the small intestine was visualized in images taken inside the abscess cavity, which suggested that the pancreatic abscess had penetrated into the small intestine (Fig. 7). Subsequently, CT showed the reduced pancreatic abscess (Fig. 8). During the course of the case, abdominal pain, melena, inflammatory reaction, and anemia were not seen. Since that event occurred, neither aggravation nor recurrence of the pancreatic abscess has been identified.

DISCUSSION

Pancreatic pseudocysts are classifiable into three types depending on their etiology: type I, pseudocyst complicating acute pancreatitis; type II, pseudocyst complicating the aggravation of chronic pancreatitis; or type III, chronic pseudocyst [retention cyst][6]. Both type I and type II described above are conditions of post-necrotizing pseudocyst. The space of the omental sac between the front of the pancreas and the stomach becomes a cyst cavity when the inflammation spreads from the pancreas. The exudate is retained in that space, and a pseudocyst is formed because Winslow's foramen is closed by severe inflammation. Type III is a cyst within the pancreas. Although the cyst wall might adhere to the gastrointestinal tract because of repeated inflammation in chronic pancreatitis, the cyst wall is usually separated from the wall of the gastrointestinal tract. Generally, type I and type II cysts, which develop secondary to acute pancreatitis and acute aggravation of chronic pancreatitis, tend to be complicated by bleeding, infection, and penetration into the gastrointestinal tract. In both cases described in this report, pancreatic pseudocysts complicating severe acute pancreatitis (above-mentioned type I) were infected, consequently forming pancreatic abscesses. They were at high risk of sepsis and might have bled severely by prolonged inflammation. Therefore, immediate drainage was necessary. As noted previously, the cyst wall might include the gastric wall itself, and it was considered that endoscopic retrograde pancreatography-guided transpapillary drainage might aggravate the acute pancreatitis. For those reasons, EUS-guided trans-gastrointestinal drainage was chosen. In both cases, inflammatory reactions improved gradually after drainage, showing the effect of washing through the drainage tube. Our treatment was inferred to be effective as an initial treatment.

Pancreatic pseudocyst is known to perforate into the abdominal cavity and the retroperitoneum, and to penetrate into the gastrointestinal tract. The frequency of penetration into the gastrointestinal tract is approximately 15-20% among pancreatic pseudocyst cases[3,7]. In the case of a pseudocyst complicating acute pancreatitis, the partial wall of the pseudocyst was composed of the wall of the gastrointestinal tract, and adhered to surrounding gastrointestinal tract because of severe inflammation. The pancreatic enzymes in the pseudocyst weaken the gastrointestinal tract wall. Consequently, the pseudocyst might penetrate into the gastrointestinal tract and naturally generate an internal fistula. Moreover, internal pressure of the pseudocyst caused by hemorrhage might involve penetration into the gastrointestinal tract[8]. To our knowledge, there are some such cases of penetration into other organs in the literature. Of those, the most frequently penetrated organ was the stomach (9 cases)[12-16,19]; other organs including the duodenum (4 cases)[10,16], transverse colon (4 cases)[9,11], spleen (4 cases), aorta (1 case)[18], and bile duct (1 case) were also penetrated (two or more organs were penetrated in some

cases). No penetration has ever been recorded into the small intestine, as occurred in case 2. The fistula which was formed by penetration into the gastrointestinal tract imparted a drainage effect that might have eliminated some pseudocysts naturally. In both cases reported here, naturally generated internal fistulas as a complication eventually contributed to elimination of the pseudocyst.

Pseudocysts complicating acute pancreatitis often form multilocular cysts because of widely expanded inflammation. In recent years, EUS-guided drainage has been performed widely as a treatment for pancreatic pseudocyst including abscess and infectious pancreatic necrosis. Many studies have examined the usefulness of the technique[20,21]. As an initial treatment for advanced inflammation, EUS-guided drainage is effective. On the other hand, limitation of the drainage tube placement in the case of multilocular infection is known. In such cases, multiple drainage tubes might have been required to be punctured from other sites. Additionally, because of the large amount of necrotic debris contained in the abscess, debris removal might be distressful, even with larger drainage tubes, and sufficient treatment might be difficult. In such cases, an endoscopic approach into the pseudocyst through the gastrointestinal tract wall (endoscopic necrosectomy) should be performed[22,23].

In our case 1, pancreatic abscesses penetrated into the transverse colon and caused bleeding. Further massive bleeding in the cyst and the abdominal cavity might occur if inflammation involves major vessels near the pseudocyst and forms a pseudo-aneurysm[24,25]. Therefore, as noted above, trans-gastrointestinal endoscopy-guided necrosectomy should be considered early when EUS-guided drainage is not effective.

In conclusion, EUS-guided treatment was effective for improvement of severe inflammation of a pseudocyst as an initial treatment. However, limitations of the drainage tube placement pertained in these cases of pseudocyst with multilocular infection. For treatment of pseudocyst/abscess complicating acute pancreatitis, a therapeutic strategy should include consideration of the pathogenic mechanism and configuration, with particular attention to the potential secondary complications.

REFERENCES

1. Simpson A, Srivastava VK. Pseudocyst of pancreas. Br J Surg, **60**: 45-49, 1973.
2. Stabile BE, Wilson SE, Debas HT. Reduced mortality from bleeding pseudocyst and pseudoaneurysm caused by pancreatitis. Arch Surg, **118**: 45-51, 1983.
3. Sankaran S, Walt AJ. The natural and unnatural history of pancreatic pseudocysts. Surgery, **62**: 37-44, 1975.
4. Vitas GJ, Sarr MG. Selected management of pancreatic pseudocysts: Operative versus expectant management. Surgery, **111**: 123-130, 1992.
5. Yeo CJ, Bastidas JA, Lynch-Nyhan A, Fishman EK, Zinner MJ, Cameron JL. The natural history of pancreatic pseudocysts documented by computed tomography. Surg Gynecol Obstet, **170**: 411-417, 1990.
6. D'Egidio A, Schein M. Pancreatic pseudocysts: a proposed classification and its

management implications. Br J Surg, **78**: 981-984, 1991.
7. Bradley EL, Clements JL, Gonzalez AC. The natural history of pancreatic pseudocysts. A united concept of management. Am J Surg, **137**: 135, 1979.
8. Greenstein A, DeMaio EF, Nabseth DC. Acute hemorrhage associated with pancreatic pseudocyst. Surgery, **69**: 56-62, 1972.
9. Goda M, Yukawa N, Fujisawa J, Matsukawa H, Shimizu S, Tomita Y. A case of serious melena and shock associated with a pancreatic pseudocyst. (in Japanese, English abstract) Journal of Japan Surgical Association, **65**: 2194-2199, 2004.
10. Yajima S, Yamasaki S, Shimada K, Sano T, Esaki M, Koide N, Kosuge T. A Case of Pancreatic Abscess Mimicking Mucinous Cystic Tumor of the Pancreas. (in Japanese, English abstract) Jpn J Gastroenterol Surg, **37**: 1428-1432, 2004.
11. Ando T, Sakakibara K, Nishiwaki N. A Case of Hemorrhagic Pseudocyst Fenestrating into the Transverse Colon. (in Japanese, English abstract) Jpn J Gastroenterol Surg, **35**: 63-67, 2002.
12. Shida A, Yamadera H, Nakabayashi Y, Ishida Y, Anazawa S, Yamazaki Y. Total gastrectomy for gastric penetration of pseudocyst of pancreas with upper gastrointestinal bleeding - report of a case -. (in Japanese, English abstract) Journal of Japan Surgical Association, **62**: 2900-2904, 2001.
13. Takahashi T, Shimada K, Kobayashi N, Kakita A. Migration of Steel-Wire Coils into the Stomach after Transcatheter Arterial Embolization for a Bleeding Splenic Artery Pseudoaneurysm: Report of a case. Surgery Today, **31**: 458-462, 2001.
14. Ohmura Y, Kashiwa T. Pancreatic carcinoma coexistent with pancreatic pseudocyst which penetrated into the stomach. International Journal of Clinical Oncology, **5**: 195-199, 2000.
15. Ishihara K, Yamada T, Suzuki N, Eirai M, Aki A, Nishikawa M, Hujii H. A Case Report of Hemorrhagic Pancreatic Pseudocyst Fenestrated into the Stomach. (in Japanese, English abstract) Jpn J Gastroenterol Surg, **32**: 870-874, 1999.
16. Shimoyama T, Ishikawa H, Shimizu T, Hisano H, Honjo S, Matsuo S, Sumida Y, Matsuo S, Nishikawa K, Terada R, Kusano H, Nakagoe T, Miura T, Tomita M, Kawaguchi A, Ashizawa K. Pancreatic Pseudocysts - Proposal for Diagnosis and Surgical Management -. Acta Medica Nagasakiensia, **40**: 18-21, 1995.
17. Yokota T, Naruse M, Oohira Y, Abe S, Aoki H, Nimura H, Tsutsumi J, Moriya Y, Tokita I, Soji K, Aoki T. A case of pancreatic pseudocyst with colonic penetration. (in Japanese, English abstract) Journal of Japanese Society for Clinical Surgery, **56**: 605-609, 1995.
18. Tsubono T, Fukushige H, Muto T. Pancreatic pseudocyst penetrated into the abdominal aorta - a case report -. (in Japanese, English abstract) Journal of Japanese Society for Clinical Surgery, **53**: 1698-1701, 1992.
19. Hirotsuji N, Takeda Y, Ohshiba S, Tsukiyama J. Pancreatic Pseudocyst Resulting in a Submucosal Hematoma, Report of a Case. (in Japanese, English abstract) I to Cho (Stomach and Intestine), **25**: 211-215, 1990.
20. Imamura H, Irisawa A, Bhutani MS, Hikichi T, Shibukawa G, Takagi TJ, Katakura K, Wakatsuki T, Sato A, Obara K, Sato Y. A New Device for Dilation of the Fistula Tract between Gastric and Cystic Wall in Performing EUS-Guided Pancreatic Pseudocyst Drainage. Gastrointestinal Endoscopy, **61**: AB283, 2005.
21. Irisawa A, Hikichi T, Obara K, Sato Y. Current State of EUS-Guided Therapy. (in Japanese, English abstract) Endoscopia Digestiva, **16**: 1247-1252, 2004.
22. Seewald S, Groth S, Omar S, Imazu H, Seitz U, Weerth AD, Soetikno R, Zhong Y, Sriram VJS, Ponnudurai R, Sikka S, Thonke F, Soehendra Nib. Aggressive endoscopic therapy for pancreatic necrosis and pancreatic abscess: a new safe and effective treatment algorithm (videos). Gastrointestinal Endoscopy, **62**: 92-100, 2005.
23. Matthes H, Janiszewski C, Schenk G. Endoscopic Transgastric EUS Guided Drainage and Necrosectomy of Infected Pancreas Pseudocysts. Gastrointestinal Endoscopy, **61**:

AB292, 2005.

24. El Hamael A, Parc R, Adda G, Bouteloup P.Y, Huguet C, Malafosse M. Bleeding pseudocysts and pseudoaneurysms in chronic pancreatitis. Br J Surg, **8**: 1059-1063, 1991.
25. Adams DB, Zellner JL, Anderson MC. Arterial hemorrhage associated with pancreatic pseudocysts: role of angiography. J Surg Res, **54**: 150-156, 1993.