福島県立医科大学 学術機関リポジトリ

Title	Perinatal diagnosis of a fetus with an unbalanced translocation 46,XY,der(10)t(6;10)(p22;q26.1) with multiple malformations: a case report and literature review
Author(s)	Ishibashi, Makiho; Watanabe, Takafumi; Kyozuka, Hyo; Yamaguchi, Akiko; Sato, Kenichi; Sato, Maki; Go, Hayato; Fujimori, Keiya
Citation	Fukushima Journal of Medical Science. 67(2): 83-88
Issue Date	2021
URL	http://ir.fmu.ac.jp/dspace/handle/123456789/1588
Rights	© 2021 The Fukushima Society of Medical Science. This article is licensed under a Creative Commons [Attribution-NonCommercial-ShareAlike 4.0 International] license.
DOI	10.5387/fms.2020-28
Text Version	publisher

This document is downloaded at: 2024-04-25T15:06:27Z

Fukushima Medical University

Fukushima J. Med. Sci.,
Vol. 67, No. 2, 2021

[Case report]

Perinatal diagnosis of a fetus with an unbalanced translocation 46,XY,der(10)t(6 ; 10)(p22 ; q26.1) with multiple malformations : a case report and literature review

Makiho Ishibashi[1)2)], Takafumi Watanabe[2)], Hyo Kyozuka[2)], Akiko Yamaguchi[2)], Kenichi Sato[3)], Maki Sato[3)], Hayato Go[3)] and Keiya Fujimori[2)]

[1)]Iwase General Hospital, Department of Obstetrics and Gynecology, Iwase General Hospital, Sukagawa, Japan, [2)]Department of Obstetrics and Gynecology, Fukushima Medical University School of Medicine, Fukushima, Japan, [3)]Department of Pediatrics, Fukushima Medical University School of Medicine, Fukushima, Japan

(Received December 25, 2020, accepted April 15, 2021)

Abstract

The phenotype of an unbalanced translocation is characterized by the dosage effects of the affected genes in the translocated chromosome. We present the case of a fetus with a paternally derived unbalanced 46,XY,der(10)t(6 ; 10)(p22 ; q26.1) translocation, detected following growth retardation and cardiac malformation. In trisomy 6p and 10q26 monosomy, external surface malformations, including characteristic facial abnormalities, and neurological or higher effects have been reported. Developmental delay and hypotonia are reported in ≤ 80% of cases of 10q monosomy. Herein, low birth weight, cephalic abnormalities including microcephaly, low-set ears and a high arched palate, ambiguous genitalia including scrotal hypoplasia and cryptorchidism, and congenital heart defects, including ventricular septal defect and pulmonary atresia, were observed. Neurological impact was not evaluated due to neonatal death. The mortality rate and frequency of low birth weight in such translocations has been seldom reported. In this case, severe cardiac malformation and low birth weight may have caused early neonatal death. Whilst Trisomy 6 is associated with low birth weight and perinatal death, few studies have reported these outcomes in 10q26 deletion syndrome. Our findings therefore contribute to the evidence base regarding unbalanced translocations and may improve the clinical management of such patients.

Key words : congenital heart disease, multiple malformations, perinatal diagnosis, severe fetal growth restriction, unbalanced translocation

Introduction

The frequency of unbalanced translocations in neonates is generally around 0.03%[1)]. In 82% of such cases, one of the parents harbors a balanced translocation. Among families harboring an unbalanced translocation, 19.2% of the translocation carriers may produce a child with an unbalanced translocation[2)].

Unbalanced translocations, as with other chromosomal abnormalities, typically result in phenotypes with multiple malformations, growth disorders, or intellectual impairment. Fetuses with moderate malformations may survive to term ; however, severe malformations may result in miscarriage or intrauterine fetal death.

We report the case of an unbalanced translocation between chromosomes 6p22 and 10q26, detected perinatally, which resulted in severe fetal growth restriction (FGR) and congenital heart disease

Corresponding author : Makiho Ishibashi E-mail : a0001669@fmu.ac.jp
©2021 The Fukushima Society of Medical Science. This article is licensed under a Creative Commons [Attribution-NonCommercial-ShareAlike 4.0 International] license.
https://creativecommons.org/licenses/by-nc-sa/4.0/

(CHD), and present a review of the related literature. The patient provided consent for the publication of this report.

Case report

The mother was a 29 year-old gravida 1, para 0, with no family history of chromosomal abnormalities. The father was 40 years old, with no family history (parents and two younger siblings) of phenotypic or chromosomal abnormalities. He did not have a significant medication or smoking history ; however, his previous partners had experienced multiple miscarriages.

The mother conceived naturally and underwent regular antenatal check-ups at other hospitals from the early stages of pregnancy. At 23 weeks gestation, FGR at −1.5 standard deviations (SD) was observed. The mother was referred to our hospital at 27 weeks gestation, due to the suspicion of fetal cardiac malformations. The fetus was diagnosed with FGR, with an estimated fetal weight (EFW) of 641 g (−3.7 SD), and CHD (comprising ventricular septal defect [VSD] and pulmonary stenosis) was suspected. However, as no arterial obstruction or reflux was observed in the umbilical cord, the cause of FGR was unclear. The mother was hospitalized for prenatal management ; isosorbide dinitrate was administered to improve blood flow in the uterine artery.

We performed chromosome analysis using amniotic-fluid cells at 29 weeks gestation and detected the chromosomal aberration 46,XY,add(10)(q26) (Figure 1). Chromosomes 6p22 and 10q26.1 had unbalanced translocations ; chromosome 10q26.1 displayed partial monosomy, and chromosome 6p22 displayed partial trisomy. To identify the origin of the additional chromosome, we conducted an additional karyotype analysis of the parents at 32 weeks gestation. The mother had a normal complement of chromosomes, but the father harbored a balanced 46,XY,t(6 ; 10)(p22 ; q26.1) translocation (Figure 2) owing to the reciprocal recombination of chromosomes 6p22 and 10q26.1. Subsequently, EFW was measured on a weekly basis, and was found to be −3.6 SD at 30 weeks gestation. Subsequent growth was slow, at −4.0 SD at 33 weeks gestation, and −4.9 SD at 36 weeks of gestation, indicative of severe FGR.

The fetus was delivered by caesarean section at 37 weeks gestation, because of blood flow abnormalities through the umbilical artery, fetal distress, and severe FGR. The neonate was male and weighed 1,470 g ; he showed Apgar scores of 3, 7, and 8 at 1, 5 and 8 minutes, respectively, with an umbilical cord arterial blood pH of 7.21.

Cardiac malformations included a ventricular septal defect (VSD), pulmonary atresia (PA), and pulmonary hypoplasia. Externally, facial malformations included low-set ears and a high-arched palate,

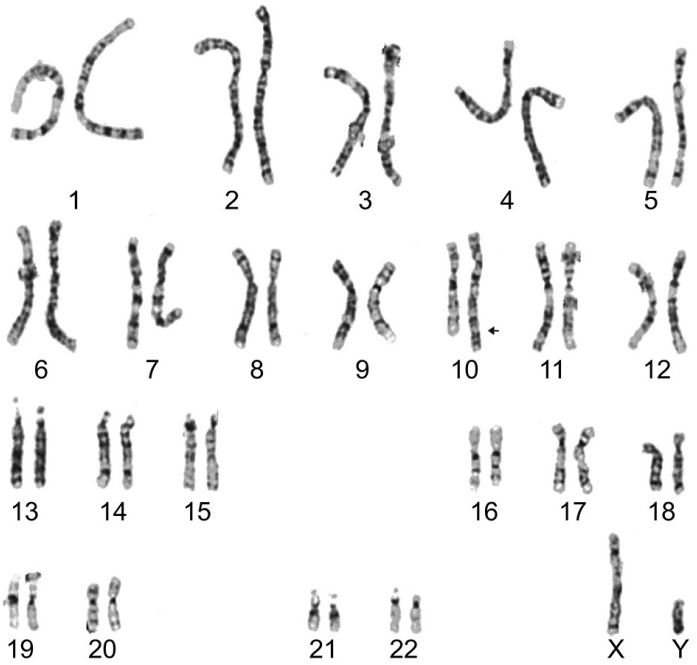

Figure 1. Karyotype analysis of amniotic fluid cells. Chromosome abnormalities are indicated by arrows. An additional chromosomal region was identified in chromosome 10.

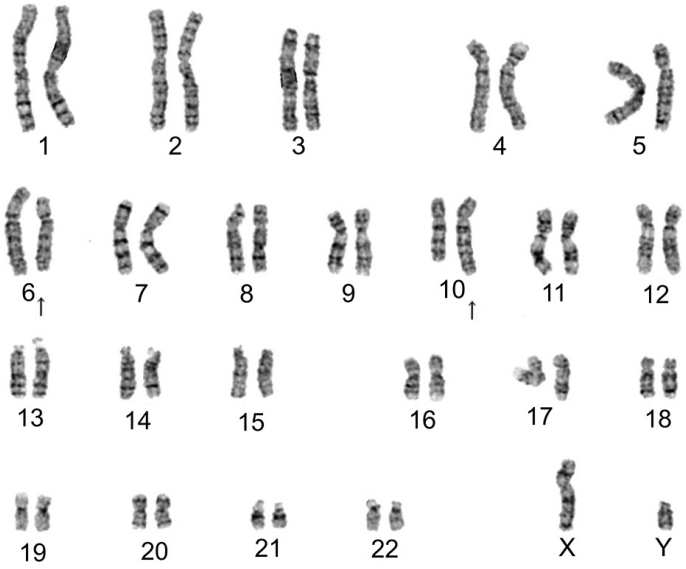

Figure 2. G-banding for the karyotype of the father revealed a balanced 46,XY,t(6 ; 10)(p22 ; q26.1) translocation. The arrow indicates the breakpoint of chromosome 6 and chromosome 10.

with other external malformations including scrotal hypoplasia, overlapping toes, and cryptorchidism, also detected in the neonate. Neurological abnormalities could not be assessed ; however, hypotonia was detected. Urinary tract or renal anomalies were not detected (Table 1). Immediately after birth, the neonate was intubated, and his respiration managed by mechanical ventilation. Echocardiography showed that the ductus arteriosus was very thin (1.5 mm). However, the presence of major aortopulmonary collateral arteries other than those associated with a patent ductus arteriosus (PDA) were suspected, because the left and right pulmonary veins flowed into the left atrium, maintaining oxygenation to some extent. After a lipid-encapsulated preparation of prostaglandin E1 (LipoPGE1) was administered for PDA-dependent heart disease, a decrease in blood pressure was observed, and a pressor agent administered. As blood pressure dropped and oxygenation decreased, the ventilator settings were raised to the upper limit. The resulting pulmonary hypertension decreased the pulmonary blood flow, therefore nitric oxide treatment was started. Sedation and muscle relaxants were started at the onset of pulmonary hypertension, but PDA stenosis led to the subsequent change from LipoPGE1 to PGE1. Despite this, the decrease in blood pressure worsened. The neonate died at 14 days-old owing to multiple organ failure triggered by pulmonary hypoplasia and circulatory failure.

Discussion

Phenotypic abnormalities observed as a result of chromosome 6 trisomy are infrequent, and were first reported as "the trisomy 6p syndrome" by Therkelsen in 1971[3]. Phenotypic abnormalities observed in the partial trisomy of chromosome 6 include craniofacial malformations, developmental delay, cardiac abnormalities, and other complications. Castiglione reported several cephalic abnormalities (including craniosynostosis, tall forehead, ear anomalies, strabismus, long philtrum, a thin vermilion border of the lips, and a high arched palate), neurological abnormalities (such as developmental delay and behavioral issues), cardiac malformations, hydronephrosis, overlapping toes, low birth weight (LBW), and immunodeficiency[4].

Multiple malformations have been reported in patients carrying partial deletions of chromosome 10. Individuals with chromosome 10q26 deletion syndrome exhibit several malformations, including craniofacial anomalies, developmental delay, urinary tract abnormalities, cardiac malformations, and neurodevelopmental deficits.

Table 1 shows the partial phenotypes of 44 cases with 6p trisomy and 20 cases with 10q26 deletion syndrome, as previously reported[4,6]. Among the 6p trisomy cases, 84% presented with mild-severe dysmorphic facies, comprising one or more of the following craniofacial malformations : low-set ears, prominent forehead, blepharophimosis, choanal atresia, arcuate palate, bulbous nose, craniosynostosis, thin lips, and tiny nares. Neurological abnormali-

Table 1. Internal and external malformations in the present case and in reported trisomy 6p and chromosome 10q26 deletion syndromes.

Feature	Present case	6p trisomy † *n*/all cases (%)	10q26 deletion ‡ *n*/all cases (%)
Total number of patients	1	44/44 (100)	20/20 (100)
Craniofacial dysmorphism	+	37/44 (84)	20/20 (100)
Microcephaly	+	2/44 (4.5)	11/14 (79)
Brachycephaly	−	3/44 (6.8)	1/4 (25)
Craniosynostosis	−	▲	1/4 (25)
Widow's peak	−	△	1/4 (25)
Tall forehead	−	▲	7/8 (88)
Bitemporal narrowing	−	△	3/4 (75)
Ear anomalies	+	▲	17/20 (85)
Thick eyebrows	+	△	1/4 (25)
Deep set eyes	−	△	2/4 (50)
Palpebral ptosis	−	13/44 (30)	△
Strabismus	−	1/44 (2.3)	13/16 (81)
Broad/prominent nose	−	▲	18/20 (90)
Hypertelorism	−	△	7/14 (50)
Long philtrum	−	▲	10/18 (56)
Thin lip vermilion	−	▲	10/17 (59)
Downturned mouth	−	△	1/5 (20)
Bifid uvula	−	△	1/4 (25)
Posterior cleft palate	−	△	3/4 (25)
High arched palate	+	▲	2/5 (40)
Broad chin	−	△	5/7 (71)
Micrognathia	−	2/44 (4.5)	4/7 (57)
Neurologic abnormalities	△	24/44 (55)	19/20 (95)
Developmental delay	△	19/44 (43)	19/20 (95)
Psychomotor delay	△	21/44 (48)	△
Intellectual disability	△	7/44 (16)	16/19 (84)
Behavioral problems	△	△	710 (70)
Seizure	△	4/44 (9.1)	1/1 (100)
Hypotonia	+	5/44 (11)	8/9 (89)
Limb anomalies	△	9/44 (21)	11/16 (69)
Clinodactyly	−	4/44 (9.1)	9/16 (56)
Congenital heart disease	+	12/44 (27)	7/12 (58)
Patent ductus arteriosus	−	△	5/7 (71)
Ventricular septal defect	+	△	3/5 (60)
Atrial septal defect	−	△	1/1 (100)
Ventricular asymmetry	−	△	1/4 (25)
Urinary tract/renal anomalies	−	13/44 (30)	5/12 (42)
Genital anomalies	+	5/44 (11)	7/14 (50)
Cryptorchidism	+	2/44 (4.5)	3/7 (43)
CNS malformations	△	3/44 (6.8)	4/12 (33)
Global cerebellar hypoplasia	△	2/44 (4.5)	1/4 (25)
Others	+	16/44 (36)	4/12 (33)
Low birth weight	+	3/4 (6.8)	△
Immunodeficiency	−	9/44 (21)	△
Hearing loss	△	4/44 (9.1)	4/12 (33)
Feeding problems	△	14/44 (32)	△
Skin pigmentary angioma	−	12/44 (27)	△

† : Malformations in trisomy 6p syndrome reported by Castiglione *et al.*[4]

‡ : Summary of malformations in chromosome 10q26 deletion syndrome reported by Lin *et al.*[6]

Legend : +, observed ; −, not observed ; △, could not be evaluated ; ▲, observed but frequency unknown ; *n*, number of cases.

ties, particularly, developmental and psychomotor delays, were also seen in about 50% of cases. In some cases, limb anomalies such as clinodactyly were observed, but the overall incidence of these was low. Heart malformations were seen in about 25% of cases, but the details of these conditions were not reported. Renal abnormalities, such as hydronephrosis, hypoplasia, renal failure, proteinuria, and genital abnormalities such as cryptorchidism was observed in 33% of patients, and small labia majora affected about 10% of patients. Immunodeficiencies, pigmented skin angiomas, and feeding problems, including swallowing difficulties, were observed in 20–30% of cases. In individuals with 10q26 deletion syndrome, the most common craniofacial abnormalities were microcephaly, tall forehead, bitemporal narrowing, ear anomalies, strabismus, broad/prominent nose, long philtrum, thin vermilion border of the lips, posterior cleft palate, and a broad chin. Neurological abnormalities were observed in 95% of patients, with developmental delay and hypotonia detected in more than 80% of cases. Behavioral problems were also frequent. Although limb abnormalities, including clinodactyly and tapering of the fingers, were observed in half of cases, no specific morphological abnormality was noted in this case. Cardiac malformations such as atrial septal defect (ASD) and VSD were observed in more than half of the cases. Minor malformations and urinary abnormalities, although infrequent, have also been reported in some cases[6].

Patients with trisomy 6 and monosomy 10 share some craniofacial abnormalities, including tall forehead, ear abnormalities, broad/prominent nose, long philtrum, and a pale vermilion border of the lips. Psychomotor delays, palpebral ptosis, LBW, immunodeficiency, feeding problems (including swallowing difficulties), and pigmented skin angiomas were often observed in trisomy 6p. Microcephaly, bitemporal narrowing, strabismus, broad chin, micrognathia, developmental delay, behavioral problems, and hypotonia seemed to be specific to monosomy 10q. Limb anomalies such as clinodactyly, congenital heart disease, and genital anomalies such as cryptorchidism were also associated with monosomy 10q[4,6]. Cardiac and urinary malformations were reported in both chromosomal abnormalities.

In the present case, LBW, cephalic abnormalities including microcephaly, low-set ears, a high arched palate, and ambiguous genitalia-associated conditions, including scrotal hypoplasia and cryptorchidism were observed. Furthermore, congenital heart defects including VSD and PA, were observed ; however, no renal malformations were observed. Developmental delay could not be evaluated, owing to neonatal death. Microcephaly, ear anomalies, hypotonia, and VSD, which are the most common external malformations in 10q26 deletion syndrome, according to Lin *et al.*[6], were observed in the present case. However, tall forehead, bitemporal narrowing, strabismus, broad/prominent nose, choanal atresia, posterior cleft palate, and broad chin were not observed. The mortality rate and frequency of LBW infants with this translocation have been seldom reported. In the present case, early neonatal death may have resulted from severe cardiac malformation and LBW. Trisomy 6 may have contributed to perinatal death and LBW, with only a few studies reporting the involvement of 10q26 deletion syndrome with perinatal death and LBW.

During gametogenesis, a chromosomal pattern opposite to that observed in our case may occur ; thus, there is a possibility of trisomy 10 and monosomy 6. In the present case, abortion would have been possible owing to significant chromosome loss. Previous studies have reported phenotypes such as preterm birth, delayed growth, developmental delay, microcephaly, craniosynostosis, internal organ abnormalities, digital abnormalities, short neck, flat face, arched eyebrows, ocular hypertelorism, flat nose, micrognathia, and cleft palate associated with the partial deletion of chromosome 6p[7]. Funnel chest and congenital cardiac anomalies such as ASD, VSD, and PDA have been reported in cases of monosomy 6p[7]. With respect to 10q trisomies, the 10q24→qter trisomy has been most frequently reported, accompanied by LBW, growth retardation, and severe developmental delay[8]. Approximately half of carriers with this trisomy have been reported to die during infancy[8].

In this case, severe FGR and multiple heart malformations were observed. The father had a history of multiple miscarriages occurring with his previous partners ; hence, a prenatal chromosomal test was performed. The parents seemed to be ready to accept the newborn infant, following the provision of information to their families about the possibility of the offspring having multiple facial malformations and visceral malformations before these had been confirmed. Based on the data presented in Table 1, it was possible to provide the family with information about the multiple malformations that could occur, in addition to those that were identified by ultrasound before birth. Therefore, we believe that prenatal chromosomal testing is a valuable tool for clinical counseling. It is important to recognize,

however, that complications that cannot be predicted based on available reports may occur, as seen in this case.

In conclusion, in the present case, karyotype analyses of a fetus presenting with severe FGR and CHD revealed an unbalanced translocation, derived from a balanced translocation inherited from the father. Chromosome analysis allows, to some extent, the prediction of prenatal malformations and postpartum neuropsychiatric developmental disorders. Given the outcomes of this pregnancy, chromosomal abnormalities can be investigated during subsequent pregnancies, and preimplantation genetic diagnosis of embryos could be implemented, to obtain useful information and ensure adequate counseling.

Availability of data and materials

Medical data are not publicly available, due to privacy and ethical restrictions.

Acknowledgments

We would like to thank Editage (www.editage.com) for their assistance with English language editing.

Conflict of interest

None declared.

Author contributions

MI : drafted the manuscript. TW : performed genetic counseling and approved the manuscript. HK, AY, KS, MS, HG, MH, and KF performed the clinical assessment.

References

1. Jacobs PA, Browne C, Gregson N, Joyce C, White H. Estimates of the frequency of chromosome abnormalities detectable in unselected newborns using moderate levels of banding. J Med Gen, **29** : 103-108, 1992.
2. Youings S, Ellis K, Ennis S, Barber J, Jacobs P. A study of reciprocal translocations and inversions detected by light microscopy with special reference to origin, segregation, and recurrent abnormalities. Am J Med Genet A, **126A** : 46-60, 1004.
3. Therkelsen AJ, Klinge T, Henningsen K, Mikkelsen M, Schmidt G. A family with a presumptive C-F translocation in five generations. Ann Genet, **14** : 13-21, 1971.
4. Castiglione A, Guaran V, Astolfi L, *et al.* Karyotype-phenotype correlation in partial trisomies of the short arm of chromosome 6 : a family case report and review of the literature. Cytogenet Genome Res, **141** : 243-259, 2013.
5. Ferrando P, San Román C, de Cordoba SR, Arnaiz-Villena A. Partial trisomy 6p : 46, XX,-10, der (10), t(6 ; 10)(p22 ; q26) pat and HLA localisation. J Med Genet, **18** : 231-234, 1981.
6. Lin S, Zhou Y, Fang Q, *et al.* Chromosome 10q26 deletion syndrome : Two new cases and a review of the literature. Mol Med Rep, **14** : 5134-5140, 2016.
7. Palmer CG, Bader P, Slovak ML, Comings DE, Pettenati MJ. Partial deletion of chromosome 6p : delineation of the syndrome. Am J Med Genet, **39** : 155-160, 1991.
8. Han JY, Kim KH, Jun HJ, Je GH, Glotzbach CD, Shaffer LG. Partial trisomy of chromosome 10 (q22-q24) due to maternal insertional translocation (15 ; 10). Am J Med Genet A, **131** : 190-193, 2004.