福島県立医科大学 学術機関リポジトリ

Title	Simultaneous multiple craniotomies in the management of multifocal malignant brain lesions: case reports
Author(s)	Tanei, Takafumi; Fujii, Masazumi; Takebayashi, Shigenori; Nakahara, Norimoto; Wakabayashi, Toshihiko
Citation	Fukushima Journal of Medical Science. 65(2): 43-49
Issue Date	2019
URL	http://ir.fmu.ac.jp/dspace/handle/123456789/1001
Rights	© 2019 The Fukushima Society of Medical Science. This article is licensed under a Creative Commons [Attribution-NonCommercial-ShareAlike 4.0 International] license.
DOI	10.5387/fms.2019-06
Text Version	publisher

This document is downloaded at: 2024-04-20T11:13:44Z

Fukushima Medical University

Fukushima J. Med. Sci.,
Vol. 65, No. 2, 2019

[Case Report]

Simultaneous multiple craniotomies in the management of multifocal malignant brain lesions : case reports

Takafumi Tanei[1,2], Masazumi Fujii[3], Shigenori Takebayashi[2], Norimoto Nakahara[2] and Toshihiko Wakabayashi[4]

[1)]Department of Neurosurgery, Komaki City Hospital, Komaki, Aichi, Japan, [2)]Department of Neurosurgery, Nagoya Central Hospital, Nagoya, Aichi, Japan, [3)]Department of Neurosurgery, Fukushima Medical University, Fukushima, Japan, [4)]Department of Neurosurgery, Nagoya University Graduate School of Medicine, Nagoya, Aichi, Japan

(Received March 15, 2019, accepted June 12, 2019)

Abstract

The appropriate strategy for treating multiple malignant brain tumors has not been well established. We discuss the indications and surgical considerations of multiple craniotomies in the same surgical session, and present three such cases. A 41-year-old woman (case 1) and a 65-year-old man (case 2), both presented with two metastatic brain lesions, one in each hemisphere. The third case was a 65-year-old woman with multiple recurrent atypical meningiomas, who underwent surgical removal in two stages. In the first surgery, only the superior sagittal sinus lesion was excised. Then in the second surgery, multiple disseminated bilateral convexity tumors were excised through a craniotomy on each side. All cases had a remarkable neurological improvement immediately after surgery. We suggest that the indications for surgical removal of multiple brain tumors with two or more craniotomies in the same surgical session are : 1) progressing neurological symptoms, 2) tumors with a maximum diameter more than 2 cm, 3) resistance to radiation and/or chemotherapy, 4) ability to tolerate the scheduled surgical time, 5) vital prognosis anticipated to be more than 3 months, 6) expectation of significant neurological improvement, and 7) single-session surgery not carrying more risk than multiple surgeries.

Key words : simultaneous, multiple craniotomies, multifocal, malignant, brain tumor

Introduction

The appropriate strategy for treating multiple malignant brain tumors is not yet well established[1,2]. One should consider the biological behavior of each pathology, the patient's prognosis, and the relative merits of each treatment modality, including observation, surgery, radiation or chemotherapy, and any combination thereof[3]. Surgery is generally indicated with the aim of improving quality of life, rather than achieving disease control and cure[4]. It could be performed primarily for patients with multiple, large, and rapidly growing tumors and/or symptomatic lesions, to mitigate against life-threatening events and/or provide symptomatic relief as early as possible[4,5].

The strategy of surgical removal of multiple malignant brain tumors, when indicated, depends on the location of each tumor. When multiple tumors are in close proximity, the tumors can be removed with one craniotomy[2]. When multiple brain tumors are more distant, we should consider two operational strategies, either two or more craniotomies performed in separate procedures over time, or multiple craniotomies in one session. Many factors must be considered, such as number, size, growth rate and location of the tumors, the patient's general condition and neurological symptoms, availability of hospital resources and individual circumstances. Guidelines or even proposals to support an appropri-

Corresponding author : Takafumi Tanei, MD, Ph.D. E-mail : nsgtakasyun@msn.com
https://www.jstage.jst.go.jp/browse/fms http://www.fmu.ac.jp/home/lib/F-igaku/

ate decision regarding operative strategy for patients with multiple malignant tumors have not been well established. Here we report 3 cases of surgical removal of multiple distant malignant brain tumors with two simultaneous craniotomies in the same session and discuss roles, indications and surgical considerations for multiple craniotomies in one session.

Case reports

Case 1 : A 41-year-old woman presented with a melanotic macule on her right ear. This macule increased in size, and neck lymph nodes were enlarged. A neck lymph node biopsy was diagnosed as malignant melanoma. The right ear melanotic macule, right parotid gland, and neck lymph nodes were excised, and adjuvant chemotherapy started. Four months later, she presented with headache and right hemiparesis. Her consciousness rapidly deteriorated to a Glasgow Coma Scale score of 12 (E2V4M6). Computed tomography (CT) and magnetic resonance imaging (MRI) revealed right frontal and left parietal tumors (Fig. 1A, B). Both tumors were more than 5 cm in diameter. She underwent surgical removal of the tumors through two craniotomies in the same surgical session. First, the left parietal tumor was removed through a left parietal craniotomy while prone. Next, her position was changed from prone to supine. Intraoperative MRI was performed, and the tumor navigation system data was updated. Then, the right frontal tumor was removed through a right frontal craniotomy. The first surgical time was 2 hours 47 minutes and second time was 2 hours 32 minutes. CT confirmed that the two tumors were removed (Figure 1 C and D). Her consciousness and right hemiparesis dramatically improved after surgery. Her Karnofsy Performance Scale (KPS) score increased from 20% to 90%, she was discharged, and subsequently spent meaningful time at home with her family for 3 of the 4 post-operative months that she survived.

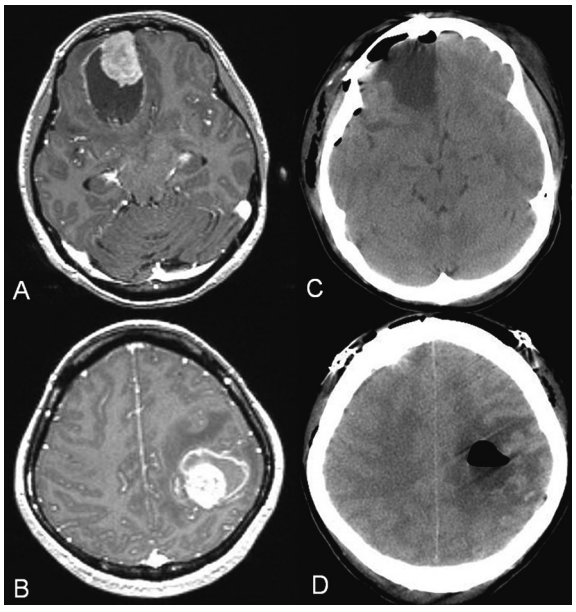

Fig. 1. Magnetic resonance images show right frontal and left parietal tumor as strongly enhanced on T1-weighted image with gadolinium with peripheral edema (A, B). Postoperative computed tomography images show removal of the two tumors (C, D). Reprinted with permission from Simultaneous surgical resections of two distant metastatic malignant melanoma lesions—case report. Tanei T, Nakahara N, Takebayashi S, Hirano M, Wakabayashi T. Nagoya J Med Sci. 74 : 173-179, 2012.

Case 2 : A 65-year-old-man presented with left hemiparesis and progressive disturbance of consciousness. His Glasgow Coma Scale score was 13 (E4V3M6). MRI revealed right frontal and left occipital tumors (Figure 2 A). Chest X-ray and CT showed a mass lesion in the right lung, which demonstrated a high uptake of (^{18}F) fluoro-2-deoxyglucose in a positron emission tomography scan. Based on the imaging findings, these lesions were thought to be multiple metastatic brain tumors from a lung primary. He underwent surgical removal of the tumors through two craniotomies in the same surgical session. First, the right frontal tumor was removed through a right frontal craniotomy while supine. Next, his position was changed from supine to prone. Intraoperative MRI was performed, and the tumor navigation system data was updated. Then, the left occipital lesion was removed through a left occipital craniotomy. Removal of both tumors was confirmed by intraoperative MRI (Figure 2 B and C). First surgical time was 3 hours 27 minutes and the second surgical time was 1 hour 55 minutes. Histopathology confirmed a small cell lung carcinoma. Symptoms improved, and his KPS score increased from 30% to 60%. He underwent chemotherapy and transferred to continue treatment in another hospital 5 months later.

Case 3 : A 65 year-old-woman first underwent surgical removal of a parasagittal atypical meningioma 13 years ago, with adjuvant gamma knife irradiation to the residual tumor. She underwent a second and third surgical removal of recurrent tumors 3 years and 1 year ago respectively. She presented

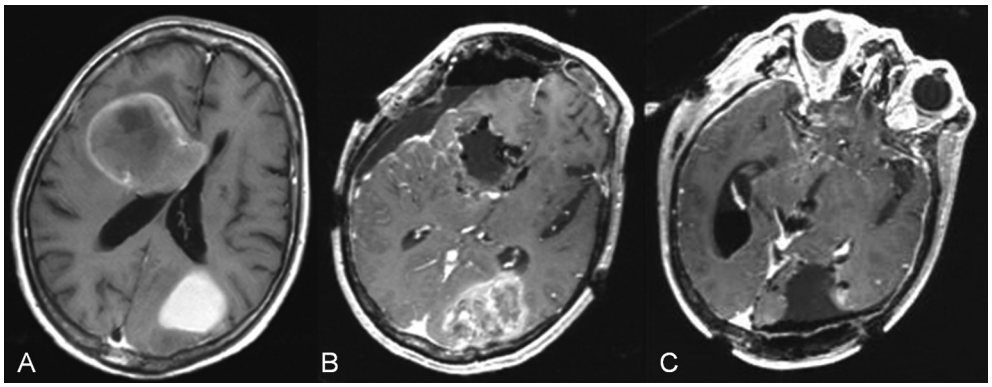

Fig. 2. Magnetic resonance T1-weighted images with gadolinium show right frontal and left occipital lesions (A). Removal of right frontal tumor was confirmed by intraoperative magnetic resonance T1-weighted images with gadolinium after first surgery (B). Removal of left occipital tumor was confirmed by intraoperative magnetic resonance images after second surgery (C).

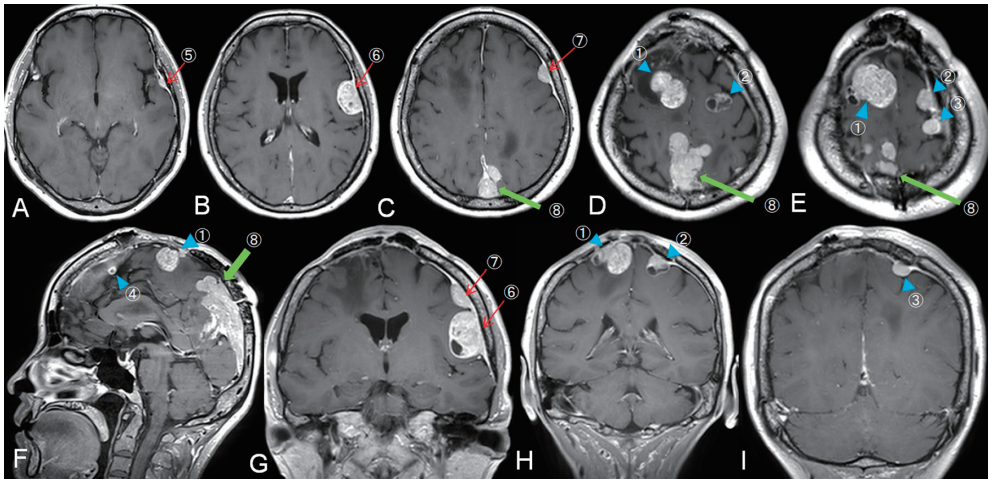

Fig. 3. Magnetic resonance T1-weighted images with gadolinium show multiple tumors at bilateral convexity and the superior sagittal sinus (A-E : axial, F : sagittal, G-I : coronal views, tumors #1-8). The superior sagittal sinus tumor (#8) was removed at the first surgery (thick arrow).
At the second surgery, frontal tumors (#1-4) ware removed through bi-frontal craniotomy (arrowhead). Next, left side tumors (#5-7) were removed through a left frontotemporal craniotomy (arrow).

with left hemiparesis, motor aphasia, and her Glasgow Coma Scale score was 14(E4V4M6). MRI revealed recurrent tumors in the superior sagittal sinus (Figure 3, tumor #8), and disseminated bilateral convexity tumors (Figure 3, tumors #1-7). The removal of tumor #8 was deemed a highly difficult operation because of tumor invasion in the superior sagittal sinus and the necessity of reconstructing dura matter using autologous tissue. Therefore, we planned two-stage surgical excisions. At the first surgery, the superior sagittal sinus tumor (tumor #8) was removed. The skin incision was in a T-shape along the previous surgical incision line (Figure 4 A-a), and a craniotomy was added to the preexisting parietal craniotomy (Figure 4 B). Skin incisions were carefully designed to maintain sufficient blood supply to each area of the scalp, with superior temporal artery supply to the anterior and middle area, and occipital artery supply to the posterior area. The defective portion of the dura mater was closed using a fascia lata graft. The first surgical time was 7 hour 13 minute. Removal of the superior sagittal sinus tumors was confirmed by MRI (Figure 4 C and D). Two weeks later, second surgery was performed through two craniotomies in the same surgical session. First, a bi-frontal craniotomy was performed along previous surgical incisions and previous craniotomy in the supine position (Figure 4 A-b), and four frontal tumors were removed (Fig 3, tumors #1-4). Next, the patient's position was changed from supine to left lateral. Intraoperative MRI images were taken, and the tumor navigation system data was updated. Then, a left frontotemporal craniotomy was per-

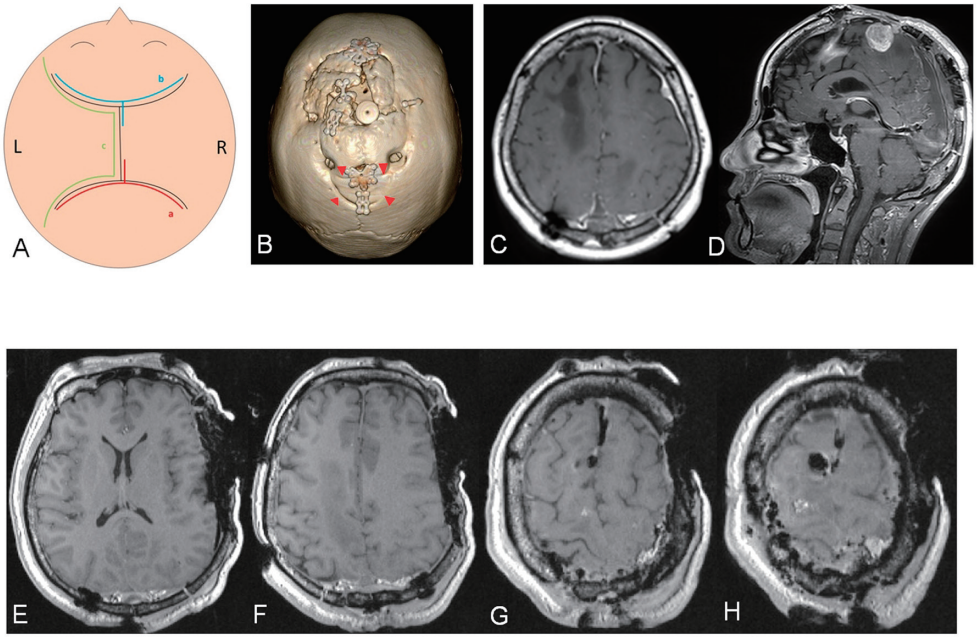

Fig. 4. Diagram of skin incision design (black : previous surgery, red : first session surgery (A-a), blue : first surgery of second session surgery (A-b), green : second surgery of second session surgery (A-c). Computed tomography image reveals portion of the craniotomies (B). Parietal craniotomy is added to the pre-existing craniotomy (arrow head). Magnetic resonance T1-weighted images with gadolinium show removal of tumors at the superior sagittal sinus (C : axial, D : coronal views). Removal of multiple bilateral convexity tumors was confirmed by intraoperative magnetic resonance T1-weighted images with gadolinium (E-H).

formed using the previous skin incision with extension (Figure 4 A-c). On the left side, 3 tumors were removed (Figure 4, tumors #5-7). Removal of all tumors was confirmed by intraoperative MRI (Figure 4 E-H). First surgical time was 4 hours 27 minutes, and the second time was 3 hours 29 minutes. Her consciousness, motor aphasia, and left hemiparesis dramatically improved. Her KPS score increased from 70% to 100%. She returned to work 1 month after the second surgery and survived more than 1 year.

Discussion

Surgical Indication and Disease Type

Differential diagnosis of multiple malignant brain tumors usually includes metastatic lesions, recurrence of malignant meningiomas, multifocal gliomas, and central nervous system lymphomas. With multiple brain tumors, vigorous surgery is most appropriate for lesions with a growth pattern that compresses the brain and does not invade far into the brain parenchyma, such as metastatic brain tumors and malignant meningiomas. In fact, 2 in our series of patients had metastatic brain tumors and 1 had a malignant form of meningioma, and they all achieved significant improvement of symptoms immediately after surgery. Radiation and/or chemotherapy have to be considered first for tumors sensitive to them, such as central nervous system lymphomas.

Metastatic Brain Tumors

Metastatic brain tumors do not infiltrate far into brain parenchyma[6,7]. While brain invasion, if present at all, is limited, metastatic tumors often compress surrounding brain tissue with wide perifocal edema, causing neurological symptoms and threatening life. Surgical removal of such tumors could improve neurologic symptom and avoid catastrophic events. It is apparent that surgical excision is effective for a solitary single brain metastatic tumor when certain criterions met[8,9]. In cases of multifocal brain metastatic tumors, however, the role of surgery has not been established, and it has been a common practice to perform radiation therapy for them[10]. With expanding treatments for primary and metastatic tumors, however, it is now common for those with multiple brain metastases to live longer than before[11-13], and thus management of multiple brain metastases should be re-considered in modern times. Konstadoulakis *et al.* reported that surgical removal of multiple metastatic brain tumors extended mean length of life when certain condi-

tions are fulfilled[14]. The conditions are that the patient is young, the primary cancer is well-controlled, and improvement of neurological symptom can be expected by tumor removal[14]. Baker *et al.* also reported on simultaneous resection of multiple metastatic brain tumors with multiple craniotomies. They suggest that it has similar surgical risk compared to one resection of a single brain metastasis, while beneficially improving KPS scores in the early postoperative period and allowing patients to be weaned from steroids[2]. They recommend that surgery be reserved for patients who had 1) tumors larger than 2 cm in diameter, 2) tumors with substantial edema or mass effect, or both, or 3) tumors that produce a neurologic deficit regardless of size. Both Case 1 and 2 fulfilled the above criterion of surgical indication and were relieved of neurological symptoms soon after surgery without any surgical complications. Surgery in Case 2 might be criticized, for the large bilateral tumors turned out to be metastatic small cell lung cancer. Had we known this pathological diagnosis in advance, we might not have chosen surgery. The patient had suffered from progressive and intense symptoms from the large bilateral tumors. Therefore, the surgery was performed as soon as possible to alleviate the patients' symptoms. It is, in fact, difficult to judge the most appropriate treatment strategy for such critically ill patients in common clinical practice. Because it can take time, often a week or two, to obtain a pathological diagnosis, doing a biopsy alone might be an unsafe choice. It could expose the patients to risks of progression of symptoms and even be life-threatening.

Multifocal Malignant Gliomas

Multifocal glioma and terminal stage glioblastoma are intensively invasive tumors. In general, surgical removal of these multiple tumors has rarely been performed mainly because of the poor prognosis and lack of improvement of the neurological symptom[15]. However, Hassaneen *et al.* demonstrated that multiple craniotomies for multifocal gliomas might be as effective as surgeries for single lesion cases and the prognosis of the former was quite comparable to the latter when aggressive surgery was performed[16].

Multiple Malignant Meningiomas

To our knowledge, there are few reports regarding the treatment of multiple meningiomas. However, we assume that surgery of multiple meningiomas is not rare in common clinical practice. Multiple meningiomas are often small and asymptomatic, and only observation is necessary for these tumors, whereas symptomatic and growing tumors are to be treated by surgery in most cases[17]. For small and some medium-size symptomatic meningiomas with high surgical risk, stereotactic radiosurgery might be indicated[17]. Case 3 was a case of multiple anaplastic meningiomas with a history of multiple prior surgeries. All the tumors present at the time of surgery were either newly developed or recurrent lesions in spite of full dose radiation therapy. Some of them were considered to be symptomatic. Radical resection for all of them was attempted for better control of the disease, as well as early relief of her symptoms. Special consideration was made especially for the design of skin incisions so that enough blood supply to the scalp was maintained to facilitate proper wound healing.

Surgical Consideration for Multiple Brain Tumors

In planning for surgical removal of multiple brain tumors with multiple craniotomies, there are several checkpoints such as selection of one- or two-stage surgery, the order of each tumor's removal, and skin incision design. Selection of one- or two-staged surgery depends on operative time and degree of surgical invasiveness. When surgical removal of multiple tumors can be short enough, and the degree of surgical invasiveness is not high, one-stage is desirable. Alternatively, when surgical removal of one tumor requires a long surgical time or carries a high invasiveness, a two-stage process is more desirable. When two-stage surgery is chosen, the duration of first and second surgery should be considered in the context of the patient's expected postoperative status and growth of the residual tumor.

The advantages of intraoperative MRI are to update navigation data and provide more accurate navigation in subsequent surgery. In an operating rooms lacking intraoperative MRI, accurate navigation can be effective only at the first surgery. Therefore, the navigation system usage priority should be considered. It is necessary to carefully determine the skin incision design, the craniotomy location, the location of head fixation pins, and consider previous craniotomy in recurrent cases.

The advantages of surgical removal of multiple brain tumors through multiple craniotomies in the same surgical session compared to two sessions are the dramatic decrease in intracranial pressure and relieving multiple tumors' combined pressure on normal brain tissue. Those advantages are expect-

Table 1. Previous reports of simultaneous resection of multiple brain tumors with multiple craniotomies

Author	Number	Type of tumors	Site of primary tumor	Overall median survival time
Bindai R, *et al.*[18]	16	metastasis	melanoma, breast, lung, sarcoma, colon, renal, and obary	Not available
Hassaneen W, *et al.*[16]	20	glioblastoma	Not applicable	9.7 months
Auslands K, *et al.*[19]	8	metastasis	melanoma, breast, gastrointestinal tract, lung, ovaryand cervix, and kidney	Not available
Tanei T, *et al.*[1]	1	metastasis	melanoma	4 months
Baker CM, *et al.*[2]	20	metastasis	lung, melanoma, renal, breast, colon, and testes	10.8 months

ed to produce dramatic improvement of neurological symptoms. Single-session surgery should be considered especially in patients with large tumors in both hemispheres with marked compression of the brain. Removal of individual tumors over two or more consecutive craniotomies within a certain time interval could allow brain mass effects immediately after the first surgery, with subsequent risk of fatal brain herniation. Regarding end-stage malignant cancer patients, rapid improvement, even if it is just temporary, can be considered as a favorable palliative treatment option. Malignant meningioma occasionally reoccurs, and radiation therapy is usually performed. But, after frequent sessions, additional irradiation might be difficult. Therefore, surgical removal of such tumors remains a valid option. Table 1 shows previous reports of simultaneous resection of multiple brain tumors with multiple craniotomies.

Disadvantages of surgical removal of multiple brain tumors, with multiple craniotomies in one session compared to two sessions, are the long surgical time and the possibility of simultaneous multifocal brain damage. Also, there are risks of position change between the first second stages (e.g., risks of withdrawing the endotracheal tube, venous lines, and arterial lines).

Indications of Simultaneous Multiple Craniotomies

We suggest that the indications for surgical removal of multiple brain tumors with two or more craniotomies in the same surgical session are : 1) progressive neurological symptoms, 2) tumors with a maximum diameter more than 2 cm, 3) resistance to radiation and/or chemotherapy, 4) ability to tolerate the scheduled surgical time, 5) vital prognosis anticipated to be more than 3 months, 6) expectation of significant neurological improvement, and 7) single-session surgery not carrying more risk than multiple surgeries.

In this article, we showed that excising multifocal brain tumors through multiple craniotomies in a single surgical session could lead to a significant neurological improvement, if certain preconditions are met.

Conflicts of Interest Disclosure

All authors certify that they have no affiliation with or involvement in any organization or entity from which a financial conflict of interest could emerge (e.g., through honoraria ; educational grants ; participation in speakers' bureaus ; membership, employment, consultancies, stock ownership, or other equity interest ; and expert testimony or patent-licensing arrangements) or any non-financial interest (e.g., personal or professional relationships, affiliations, knowledge, or beliefs) related to the subject matter or materials discussed in this manuscript.

Informed Consent

Informed consent was obtained from all individual participants included in the study.

References

1. Tanei T, Nakahara N, Takebayashi S, Hirano M, Wakabayashi T. Simultaneous surgical resections of two distant metastatic malignant melanoma lesions—case report. Nagoya J Med Sci, **74** : 173-179, 2012.
2. Baker CM, Glenn CA, Briggs RG, *et al.* Simultaneous Resection of Multiple Metastatic Brain Tumors with Multiple Keyhole Craniotomies. World Neurosurg, **106** : 359-367, 2017.
3. Maiuri F, Cappabianca P, Iaconetta G, Esposito F, Messina A. Simultaneous presentation of meningiomas with other intracranial tumours. Br J Neurosurg, **19** : 368-375, 2005.
4. Paek SH, Audu PB, Sperling MR, Cho J, Andrews DW. Reevaluation of surgery for the treatment of brain metastases : review of 208 patients with single or multiple brain metastases treated at one institution with modern neurosurgical tech-

niques. Neurosurgery, **56** : 1021–1034, 2005.
5. Iwadate Y, Namba H, Yamaura A. Significance of surgical resection for the treatment of multiple brain metastases. Anticancer Res, **20** : 573–577, 2000.
6. Yagi R, Kawabata S, Ikeda N, *et al.* Intraoperative 5-aminolevulinic acid-induced photodynamic diagnosis of metastatic brain tumors with histopathological analysis. World J Surg Oncol, **15** : 179, 2017.
7. Yoo H, Kim YZ, Nam BH, *et al.* Reduced local recurrence of a single brain metastasis through microscopic total resection. J Neurosurg, **110** : 730–736, 2009.
8. D'Andrea G, Palombi L, Minniti G, Pesce A, Marchetti P. Brain Metastases : Surgical Treatment and Overall Survival. World Neurosurg, **97** : 169–177, 2017.
9. Noordijk EM, Vecht CJ, Haaxma-Reiche H, *et al.* The choice of treatment of single brain metastasis should be based on extracranial tumor activity and age. Int J Radiat Oncol Biol Phys, **29** : 711–717, 1994.
10. Assouline A, Levy A, Chargari C, Lamproglou I, Mazeron JJ, Krzisch C. Whole brain radiotherapy : prognostic factors and results of a radiation boost delivered through a conventional linear accelerator. Radiother Oncol, **99** : 214–217, 2011.
11. Arvold ND, Lee EQ, Mehta MP, *et al.* Updates in the management of brain metastases. Neuro Oncol, **18** : 1043–1065, 2016.
12. Auslands K, Apskalne D, Bicans K, Ozols R, Ozolins H. Postoperative survival in patients with multiple brain metastases. Medicina (Kaunas), **48** : 281–285, 2012.
13. Bindal RK, Sawaya R, Leavens ME, Lee JJ. Surgical treatment of multiple brain metastases. J Neurosurg, **79** : 210–216, 1993.
14. Konstadoulakis MM, Messaris E, Zografos G, Androulakis G, Karakousis C. Prognostic factors in malignant melanoma patients with solitary or multiple brain metastases. Is there a role for surgery? J Neurosurg Sci, **44** : 211–218 ; discussion 219, 2000.
15. di Russo P, Perrini P, Pasqualetti F, Meola A, Vannozzi R. Management and outcome of high-grade multicentric gliomas : a contemporary single-institution series and review of the literature. Acta Neurochir (Wien), **155** : 2245–2251, 2013.
16. Hassaneen W, Levine NB, Suki D, *et al.* Multiple craniotomies in the management of multifocal and multicentric glioblastoma. Clinical article. J Neurosurg, **114** : 576–584, 2011
17. Tsermoulas G, Turel MK, Wilcox JT, *et al.* Management of multiple meningiomas. J Neurosurg, **128** : 1403–1409, 2018.
18. Bindal RK, Sawaya R, Leavens ME, Lee JJ. Surgical treatment of multiple brain metastases. J Neurosurg, **79** : 210–216, 1993.
19. Auslands K, Apskalne D, Bicans K, Ozols R, Ozolins H. Postoperative survival in patients with multiple brain metastases. Medicina (Kaunas), **48** : 281–285, 2012