福島県立医科大学 学術機関リポジトリ

FUKUSHIMA MEDICAL UNIVERSITY

| | |
|---|---|
| Title | Acute peri-myocarditis with an unusual initial manifestation of gallbladder edema and a profound eosinophilic surge during convalescence |
| Author(s) | Zenda, Takahiro; Araki, Ichiro; Nakamiya, Otoyuki; Ogawa, Mitsuko; Higashi, Kotaro; Ueno, Toshio |
| Citation | Fukushima Journal of Medical Science. 64(2): 95-102 |
| Issue Date | 2018 |
| URL | http://ir.fmu.ac.jp/dspace/handle/123456789/700 |
| Rights | © 2018 The Fukushima Society of Medical Science |
| DOI | 10.5387/fms.2018-08 |
| Text Version | publisher |

This document is downloaded at: 2024-05-05T10:01:22Z

Fukushima Medical University

Fukushima J. Med. Sci.,
Vol. 64, No. 2, 2018

**[Case Report]**

# Acute peri-myocarditis with an unusual initial manifestation of gallbladder edema and a profound eosinophilic surge during convalescence

Takahiro Zenda[1)], Ichiro Araki[1)], Otoyuki Nakamiya[2)], Mitsuko Ogawa[3)], Kotaro Higashi[4)] and Toshio Ueno[5)]

*[1)]Departments of Internal Medicine, [2)]Radiology, [3)]Clinical Laboratory, and [4)]Radiology PET-CT Center, Asanogawa General Hospital, Kanazawa, Japan, [5)]Department of Internal Medicine, Kanazawa Medical Station VieC, Kanazawa, Japan*

(Received April 5, 2018, accepted July 31, 2018)

**Abstract**

A 29-year-old man with fever and right upper quadrant pain was referred to our hospital. Ultrasonography revealed intense gallbladder edema and pericardial effusion. Despite no symptoms and signs related to heart failure, the patient was clinically suspected of cardiac dysfunction related to acute peri-myocarditis based on his symptoms of preceding fever and headache, pericardial effusion, positive troponin T value, elevated B-type natriuretic peptide level, and sequential changes on electrocardiography. With a profound eosinophilic surge (8,022/μL) during convalescence, acute peri-myocarditis and gallbladder edema resolved spontaneously. This case instructively shows that acute peri-myocarditis initially manifests with abdominal symptoms, mimicking acute acalculous cholecystitis. In addition, an extensive review of acute myocarditis cases with peripheral eosinophilia suggests that there is a subgroup characterized by a predilection for young and middle-aged men, concurrence of pericardial effusion, transient eosinophilic surge during convalescence, and favorable outcome.

**Key words :** acute myocarditis, eosinophilic surge during convalescence, congestive heart failure, gallbladder edema, acute acalculous cholecystitis

## Introduction

Acute myocarditis is defined as cardiac inflammation that commonly results from an infectious process or hypersensitivity to drugs[1)]. Because acute myocarditis presents various vague symptoms or findings ranging from an asymptomatic state shown only by abnormalities on an electrocardiogram to cardiac sudden death[1-6)] or often shows no significance in the physical examination[1)], early diagnosis of acute myocarditis is challenging[2,5,7)].

We describe an unusual case of acute peri-myocarditis that initially manifested with intense gallbladder edema mimicking acute acalculous cholecystitis and thereafter presented with a profound surge of eosinophils. Based on an extensive review of acute myocarditis with peripheral eosinophilia, we also discuss a possible subgroup of acute myocarditis characterized principally by an eosinophilic surge during convalescence.

## Case Report

A 29-year-old Japanese man visited an outpatient clinic with complaints of malaise, headache, and fever of >39°C. The patient was first diagnosed with upper respiratory tract infection and prescribed non-steroidal anti-inflammatory drugs. The next day, he reported right upper quadrant pain and underwent abdominal ultrasonography, which revealed marked thickening of the gallbladder wall

Corresponding author : Takahiro Zenda, M.D., Ph.D. E-mail : zenda@asanogawa-gh.or.jp
https://www.jstage.jst.go.jp/browse/fms http://www.fmu.ac.jp/home/lib/F-igaku/

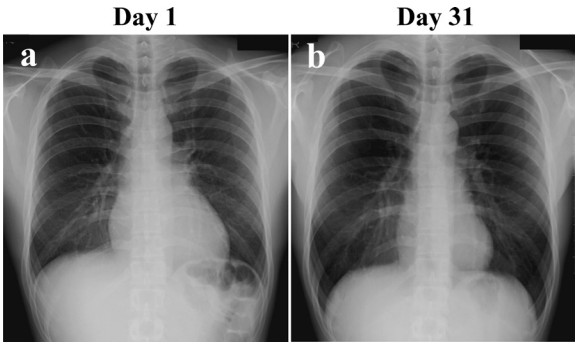


Fig. 1. Chest roentgenography. On admission, the patient's heart size was enlarged as suggested by a cardio-thoracic ratio (CTR) of 50% but no remarkable findings in the pulmonary fields (a). On day 31, concomitant with the disappearance of pericardial effusion, the CTR decreased to 37.5% (b).

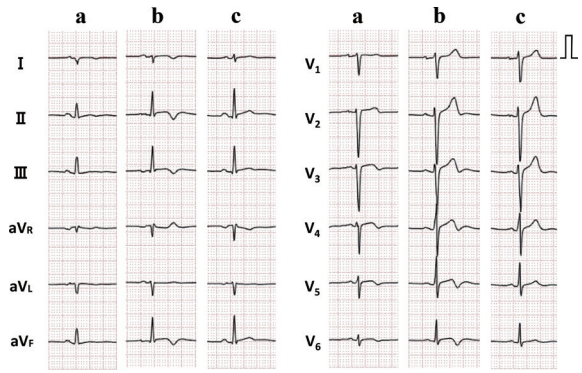


Fig. 2. Electrocardiogram on days 1 (a), 10 (b), and 31 (c). On admission, all leads showed low voltage, regression of the R wave in leads $V_{1-6}$ and a flat T wave in leads II, III, and aVF (a). Ten days later, the low voltage was restored, but a negative T wave was seen in leads I, II, III, aVF, and $V_6$ (b). The electrocardiogram normalized on the day 31 (c). The scale represents 1mV.

with no stones. He was then referred to our hospital for the treatment of suspected acute acalculous cholecystitis.

At initial presentation, his general condition was fairly good, except for hypotension with a blood pressure of 78/42 mmHg, pulse rate of 88 beats per minute, and low grade fever of 37.2°C. Oxygen saturation in the periphery was 96% on room air. Physical examination revealed tenderness in the right upper quadrant, but neither the liver nor the gallbladder was palpable. His respiratory and heart sounds were normal. No clinical signs of heart failure, such as peripheral edema or dilatation of the jugular vein, were observed. The patient was a non-smoker and an occasional alcohol consumer. He had no significant history, allergic tendency, or any history of drug use.

On chest roentgenography, his heart size was slightly enlarged with a cardio-thoracic ratio of 50%, but no pulmonary infiltration was observed (Fig. 1-a). An electrocardiogram showed low voltage in all leads, regression of the R wave in leads $V_{1-6}$, and a flat T wave in leads II, III, and aVF (Fig. 2-a). Re-evaluation with ultrasonography revealed diffuse gallbladder wall thickening of up to 18 mm with a three-layered structure[8]. Wall thickening was limited exclusively to the middle layer, reflecting edema of the tunica of the subserosa and propria muscularis. The inner and outer layers, regarded as the mucosa and serosa, respectively, were intact (Fig. 3-a-c). Color Doppler sonography clearly defined the intramural blood circulation (Fig. 3-d), which excluded ischemic cholecystitis. Gallstones, hepatomegaly, and dilatation of the hepatic veins were absent, and inspiratory collapse of the inferior vena cava was observed (Fig. 3-e). A diagnosis of gallbladder edema, not cholecystitis[8], was finally made via ultrasonography. Ultrasonography also revealed moderate amounts of pericardial effusion (Fig. 3-f ; arrows).

A peripheral blood cell count showed mild leukocytosis (9,700/μL) with an increased eosinophil count of 989/μL. Blood biochemistry showed elevated liver enzyme levels (normal ranges in parentheses) ; aspartate aminotransferase (AST) 70 IU/L (13-33), alanine aminotransferase (ALT) 236 IU/L (8-42), alkaline phosphatase (ALP) 405 IU/L (115-359), gamma-glutamyl transpeptidase (γGTP) 150 IU/L (10-47), mild inflammatory increase in C-reactive protein (CRP) 0.56 mg/dL (<0.3) and elevated IgE 635.1 IU/mL (0.0-295.6). Viral markers associated with acute hepatitis, which accompanies gallbladder wall thickening[8], such as IgM-hepatitis A virus antibody, IgM-hepatitis B core antibody, hepatitis C virus antibody, IgA-hepatitis E antibody, IgM-Epstein-Barr antibody, and IgM-cytomegalovirus antibody, were all negative.

With respect to pericardial effusion, despite a normal creatine phosphokinase level of 246 IU/L (62-287), a positive cardiac troponin T value (TROP T Sensitive®, Roche Diagnostics Inc., Tokyo, Japan), which is a diagnostic and prognostic marker of myocarditis[9], and an increased B-type natriuretic peptide (BNP) of 563 pg/mL (0.0-18.4) suggested the presence of cardiac dysfunction with myocardial damage. However, except for moderate amounts of pericardial effusion (Fig. 4-a), echocardiography reveled no significant findings such as cardiac wall thickening, chamber dilatation, or valvular dysfunc-

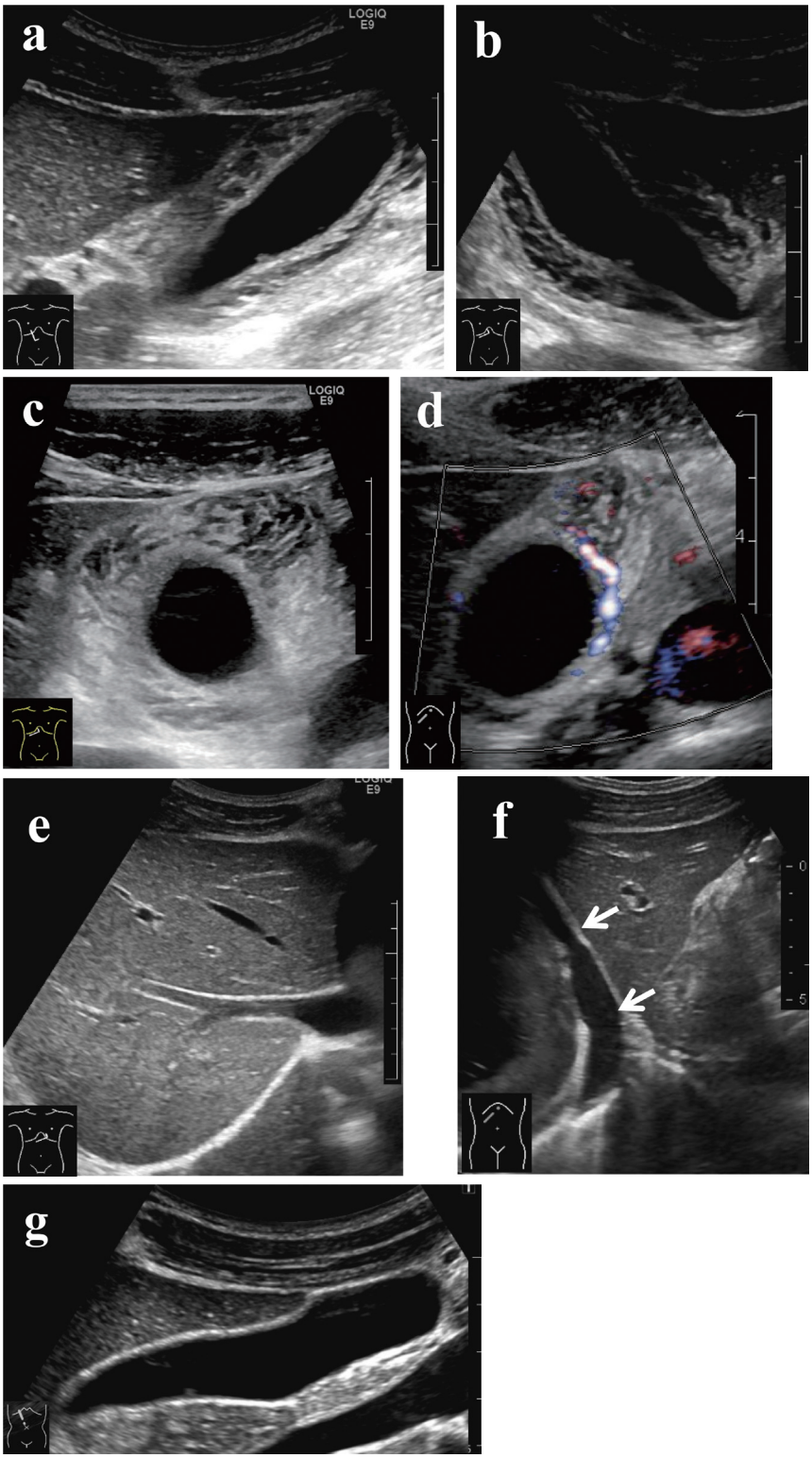


Fig. 3. Ultrasonography. Ultrasonography revealed diffuse gallbladder wall thickening up to 18 mm with a three-layered structure. Although the wall thickening was limited exclusively to the middle layer reflecting edema principally of the connective tunica of the subserosa, the inner and outer layers, which were regarded as the mucosa and serosa, respectively, were intact (a-c). Color Doppler sonography demonstrated intramural blood circulation (d), which excluded ischemic cholecystitis. Gallstones, hepatomegaly, and dilatation of the hepatic veins were not found (e), and inspiratory collapse of the inferior vena cava was observed. A final diagnosis of gallbladder edema, not acute acalculous cholecystitis, was made via ultrasonography. Ultrasonography also revealed moderate amounts of pericardial effusion (f ; arrows) and a few tiny gall bladder polyps (a and b). Ten days later, the gallbladder edema completely subsided (g). One distance of the scale represents 1 cm.

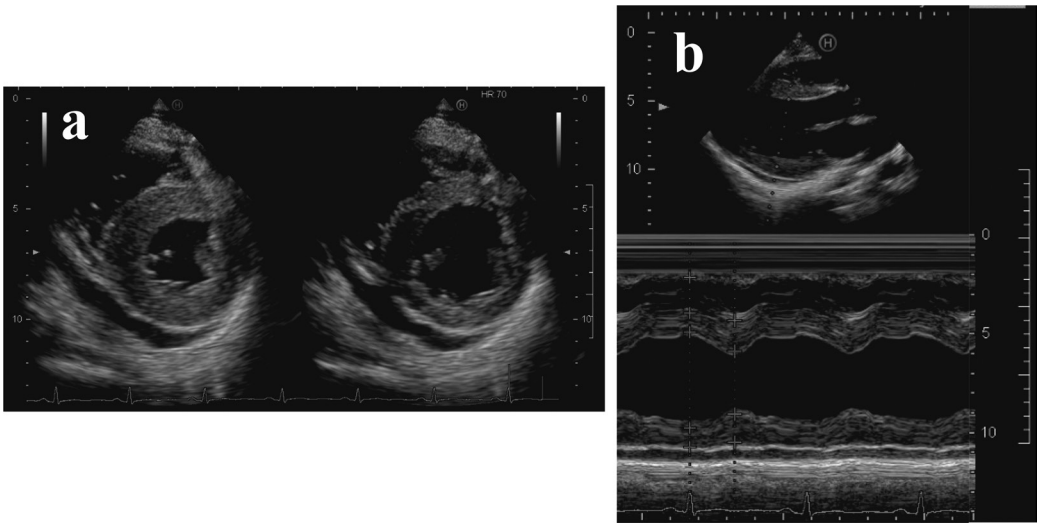


Fig. 4. Cardiosonography. Left ventricular wall motion and function were normal, as demonstrated by an ejection fraction of 63.2% and a percent fractional shortening of 34.3%. Wall thickness was normal with 9.7 mm of end-diastolic and 14.3 mm of end-systolic left ventricular posterior wall thickness and 9.7 mm of end-diastolic and 15.7 mm of end-systolic interventricular septum thickness (a and b). No valvular dysfunction was detected. Pericardial effusion was revealed (a). One distance of the scale represents 1 cm.

tion (Fig. 4-b). Cardiac wall motion and function were well preserved as demonstrated by an ejection fraction of 63.2% and percent fractional shortening of 34.3% (Fig. 4-b). Similarly, myocardial perfusion scintigraphy via $^{99m}$Tc pyrophosphate performed on the day 2 after admission revealed no abnormal concentration, for which neither SPECT (single photon emission computed tomography) imaging of short axis, vertical long axis nor horizontal long axis was available. Holter monitor electrocardiography for 24 hours revealed no significant arrhythmia. Considering all test results, the patient was clinically suspected to have acute peri-myocarditis[2] with eosinophilia in the fastigium phase. It was also assumed that the gallbladder edema resulted from congestive hepatopathy subsequent to heart failure.

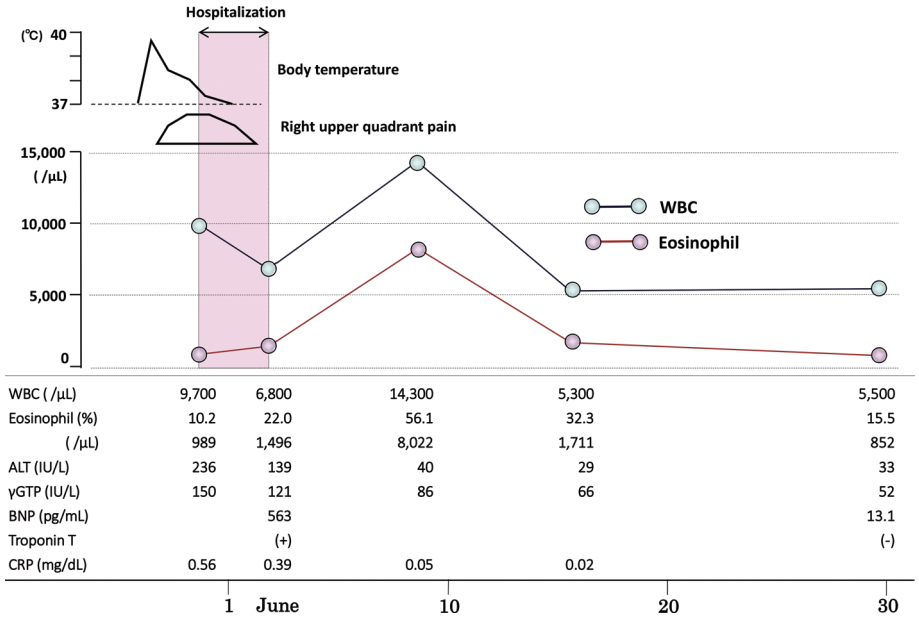


Fig. 5. Clinical course. Despite being in the convalescent period of myocarditis and gallbladder edema, a high eosinophilic surge up to 8,022/μL was asymptomatically detected on day 10. The patient's blood cell count, ALT, BNP, troponin T, and CRP became nearly normalized or negative by day 31. ALT : alanine aminotransferase, γGTP : gamma-glutamyl transpeptidase, BNP : B-type natriuretic peptide, CRP : C-reactive protein, WBC : white blood cell.

Because fever and cholecystalgia rapidly and spontaneously resolved, the patient left the hospital on day 3 against medical advice that peri-myocarditis should be carefully observed while maintaining rest[1,2]. Complete resolution of the gallbladder wall thickening was confirmed on ultrasonography on day 10. The liver injury nearly normalized on day 17. Disappearance of the pericardial effusion on ultrasonography, reduction of the cardio-thoracic ratio (Fig. 1-b), normalization of electrocardiogram (Fig. 2-c) and BNP level (13.1 pg/mL), and a negative cardiac troponin T value occurred by day 31 without any medication (Fig. 5). However, eosinophilia was sustained asymptomatically and presented as a surge up to 8,670/μL with leukocytosis of 14,300/μL on day 10. After the surge, the eosinophil count gradually decreased to 932/μL on day 31 (Fig. 5), when neither degranulated eosinophils in the peripheral blood smear nor eosinophil cationic protein in the serum was detectable. After day 31, the patient stopped visiting us, simply because he no longer experienced symptoms ; nevertheless, we repeatedly urged him to continue follow-up consultations.

The cause of the eosinophilia and/or peri-myocarditis could not be identified despite our efforts, as there was no significant elevation of viral antibody titers of adenovirus, echovirus 3 or 4, enterovirus 70 or 71, or Coxsackie virus A9, A16, B2, or B5 in two serum samples obtained in the acute and remission phase with a 4-week interval. Influenza A, B antigen and IgM parvovirus 19 antibody were negative in the acute phase. Parasite eggs were not detected in the feces. Serologically, levels of immunoglobulins including those of IgG, IgA, IgM, and IgG4, and complements proteins were all normal. Markers of autoimmune diseases, such as antinuclear antibody, double-stranded DNA antibody, rheumatoid factor, and perinuclear and proteinase 3 anti-neutrophil cytoplasmic antibody, were all negative.

## Discussion

Endomyocardial biopsy, which is the gold standard for diagnosing myocarditis[2,3], was not performed because of the patient's refusal owing to the prompt resolution of his symptoms. However, the presence of a preceding fever and headache, abnormal findings on electrocardiography, pericardial effusion shown by ultrasonography, positive cardiac troponin T value, and mild elevation of white blood cell counts and CRP levels sufficiently fulfilled the criteria of clinically suspected myocarditis, for which the diagnostic processes exclusively depends on patient's clinical presentations and results of non-invasive testing[2]. In the present case, although cardiac function and myocardial damage were nearly restored on admission according to echocardiography and $^{99m}$Tc pyrophosphate scintigraphy, the positive cardiac troponin T value, significantly raised BNP level, and sequential changes on electrocardiography were suggestive of cardiac dysfunction with myocardial damage, i.e., acute myocarditis. This clinical discrepancy may be explained by the observation that acute myocarditis in the majority of patients is surprisingly mild and resolves within a few days[10].

Symptoms related to acute myocarditis are vague and numerous, including variously a subclinical presentation, common cold-like symptoms (fever, malaise, sore throat, cough, and arthralgia)[2-5,7], chest pain due to pericardial irritation[3], acute coronary syndrome-like symptoms (chest pain or changes on electrocardiography)[2-6], dyspnea and fatigue related to congestive heart failure[6], palpitation and syncope related to arrhythmia[6], and even sudden death[2-5]. However, to the best of our knowledge, this is the first report of acute myocarditis that initially manifested with intense gallbladder edema. Because gallbladder venous return flows into the portal system in the hepatic parenchyma, gallbladder edema is caused by the blockage of portal and systemic venous drainage[8,11] owing to congestive hepatopathy from causes such as liver cirrhosis and acute hepatitis, congestive heart failure[11], or cardiac tamponade[12,13]. The relatively loose connective tissue accounts for the occurrence of edematous changes principally in the subserosal layer of the gallbladder[11]. Similar to our case, gallbladder edema is occasionally incorrectly diagnosed as acute acalculous cholecystitis simply based on the finding of wall thickening in the absence of stones[12]. However, careful evaluation of the thickened layer of the gallbladder wall by ultrasonography, certification of intramural blood flow by color Doppler ultrasonography, and an undistended gallbladder may provide critical clues for distinguishing gallbladder edema from acute acalculous cholecystitis, which is one of the dreaded causes of acute abdomen with a mortality rate of >30%[11]. Thus, to avoid erroneous surgery, awareness that acute myocarditis may manifest with acute abdominal symptoms[12,13], resembling acute acalculous cholecystitis, is required.

Liver function abnormalities are found in about a half of patients with uncompensated heart failure[14]. In such cases, reduced cardiac output and

the subsequent low hepatic perfusion and/or oxygenation (forward heart failure) induce centrolobular hepatocellular damage to elevate levels of AST and ALT, whereas high central venous pressure and the subsequent hepatic congestion (backward heart failure) induce cholestasis via bile duct compression to elevate levels of ALP, γGTP or bilirubin[14,15]. Although the patient did not present apparent symptoms and signs related to congestive heart failure on admission, elevated levels not only of AST and ALT but also of ALP and γGTP suggest a possibility that the patient had once fallen in an ill hemodynamic state such as low cardiac output and high central venous pressure related to peri-myocarditis. Further, we speculate that delayed restoration of microscopic liver congestion resulted in liver injury and gallbladder edema on admission.

Another noticeable finding was the profound eosinophilic surge, with a peak value of 8,022/μL, despite being in the convalescent period of peri-myocarditis. Although eosinophilia continued from the first consultation, background conditions to cause sustained eosinophilia such as allergic predisposition, systemic eosinophilic disorders (e.g., hypereosinophilic syndrome and granulomatous necrotizing polyangiitis of Churg-Strauss syndrome)[4,5,16-18], autoimmune disease, parasite infection, recent initiation of drug use, or exposure to an allergen were all excluded. Although the cause of eosinophilia remained unknown, eosinophilic fluctuation in the form of a surge is more likely to result from a transient hypersensitive immune response to a foreign body[4,5,17,19-21] rather than a chronic hypereosinophilic disorder.

As shown in Table 1, to our knowledge, there have been 11 cases of acute myocarditis with a profound eosinophilic surge described in the English[7,20] or Japanese[16,17,21-24] literature. Although all the patients documented were interestingly Japanese, we cannot explain the reason for such a predilection at present. The documented clinical features can be summarized as follows : (i) male predominance, especially young and middle-aged men[16,17,20-24] ; (ii) absence of eosinophilia (<500/μL)[7,22,23] or mild eosinophilia (<1,500/μL)[7,16,20,21] at the onset of disease that gradually increases as myocarditis progresses ; (iii) an eosinophilic surge occurring in the convalescent period (mean ± standard deviation : peak eosinophil count, 5,252 ± 2,506/μL ; interval from the onset of disease, 11.9 ± 4.1 days)[7,16,17,20-24] ; (iv) myocarditis accompanied by pericardial effusion, i.e., in the form of peri-myocarditis[16,17,20-24] ; (v) favorable outcome

Table 1. Literature review of acute myocarditis accompanied by a profound eosinophilic surge.

| | author | year | age | gender | allergic tendency | preceding infection | heart failure (NYAH) | eosinophil count (/μL) | | | pericardial effusion | biopsy* | EM findings in pathology | treatment | outcome | reference number |
|---|---|---|---|---|---|---|---|---|---|---|---|---|---|---|---|---|
| | | | | | | | | onset | surge | | | | | | | |
| | | | | | | | | | peak | day | | | | | | |
| 1 | Inoh T, *et al.* | 1980 | 34 | M | (−) | (−) | II | 774 | 4,200 | 14 | (+) | (−) | − | n.d. | alive ( 2 months) | 20 |
| 2 | Ishide T, *et al.* | 1985 | 37 | M | (−) | (−) | II | <100 | 5,000 | 19 | (+) | (+) | (−) | (−) | alive ( 4 years) | 22 |
| 3 | Suzuki H, *et al.* | 1989 | 11 | M | (−) | (−) | III | 680 | 8,684 | 9 | (+) | (+) | (−) | (−) | alive ( 2 months) | 16 |
| 4 | Ono N, *et al.* | 1991 | 47 | M | (+) | (−) | II | 612 | 1,764 | 8 | (+) | (+) | (+) | (−) | alive (40 days) | 21 |
| 5 | | 1991 | 30 | M | (+) | (−) | II | 1,694 | 2,046 | 12 | (+) | (+) | (+) | (−) | alive (31 days) | 21 |
| 6 | Hata H, *et al.* | 1999 | 20 | M | (+) | (+) | III | 1,834 | 6,681 | 8 | (+) | (−) | − | cardiotonics, diuretics | alive (36 days) | 17 |
| 7 | Yamamoto K, *et al.* | 2002 | 22 | M | (−) | (−) | II | 1,560 | 3,944 | 15 | (+) | (+) | (+) | steroid, diuretics | alive ( 6 months) | 24 |
| 8 | Morimoto S, *et al.* | 2003 | 47 | M | (+) | (+) | IV | 1,312 | 9,024 | 12 | n.d. | (+) | n.d. | steroid | alive (33 days) | 7 |
| 9 | | 2003 | 39 | F | (−) | (+) | IV | 660 | 5,439 | 8 | n.d. | (+) | n.d. | steroid | alive (50 days) | 7 |
| 10 | | 2003 | 24 | F | (+) | (−) | IV | 189 | 2,020 | 9 | n.d. | (+) | n.d. | (−) | alive (60 days) | 7 |
| 11 | Mori N, *et al.* | 2004 | 47 | M | (−) | (−) | I | 490 | 5,550 | 19 | (+) | (+) | (+) | steroid | alive ( 5 months) | 23 |
| 12 | our case | 2018 | 29 | M | (−) | (−) | I | 989 | 8,670 | 10 | (+) | (−) | − | (−) | alive (31 days) | |
| | average | | 32.3 | | | | | 981 | 5,252 | 11.9 | | | | | | |

EM : eosinophilic myocarditis, M : male, F : female, NYHA : New York Heart Association, * : endomyocardial biopsy, n.d. : not described.

with[7,17,23,24] or without[7,16,21,22] appropriate treatment, although cardiac function may be impaired or with[21,23,24] or without[16,22] eosinophil infiltration into the myocardium, i.e., eosinophilic myocarditis ; and (vi) allergic predisposition or preceding upper respiratory tract infection that is not necessarily concurrent. Concerning pericardial effusion, it may be a characteristic finding of acute myocarditis with peripheral eosinophilia, similarly to eosinophil-rich ascites which is one of the crucial diagnostic clue of eosinophilic gastroenteritis[25]. As our case fits well into these clinical features, there may be a subgroup of patients with acute myocarditis that is principally characterized by a profound eosinophilic surge during convalescence.

This case report had a limitation related to the absence of an endomyocardial biopsy. Owing to the lack of pathological evaluation of the endomyocardium, a definite diagnosis of neither acute myocarditis nor eosinophilic myocarditis could be established[2,3]. Although the patient recovered favorably, sustained eosinophil infiltration into the endomyocardium can potentially result in lethal cardiac impairment, regardless of the underlying cause[21]. Moreover, eosinophilia in the peripheral blood does not necessarily reflect eosinophil infiltration into the myocardium[7], according to reports of patients with biopsy-proved eosinophilic myocarditis that did not present with eosinophilia throughout the clinical course[4,5,7,19] or conversely, those of patients with sustained eosinophilia but lacking any cardiac involvement[5]. Such inconsistency between peripheral eosinophilia and eosinophil infiltration into the myocardium was noted among patients with acute myocarditis accompanied by an eosinophilic surge (Table 1). Therefore, a histological study is indispensable for a patient with myocarditis accompanied by eosinophilia when considering inducing immunosuppressive therapy with steroids or predicting prognosis. Although the outcome of acute myocarditis with an eosinophilic surge appears to be generally favorable, longer observation to determine whether subsequent cardiomyopathy develops[1,2] and further consideration by accumulation of similar cases are still required.

## Acknowledgement

The authors are grateful to Kei Hamazaki, (Assistant Professor, Department of Public Health, Faculty of Medicine, University of Toyama) for his extensive research of literature and instructive comments.

## Declaration of interest

The authors report no conflicts of interest in relation to this study.

## References

1. Wynne J, Braunwald E. Cardiomyopathy and myocarditis. *In* : Harrison's Principles of Internal Medicine. 16th ed. McGraw-Hill, New York, 1408-1414, 2005.
2. Caforio ALP, Pankuweit S, Arbustini E, *et al*. Current state of knowledge on aetiology, diagnosis, management, and therapy of myocarditis : a position statement of the European Society of Cardiology Working Group on Myocardial and Pericardial Diseases. Eur Heart J, **34** : 2636-2648, 2013.
3. JCS Joint Working Group. Guidelines for diagnosis and treatment of myocarditis (JCS 2009) : digest version. Circ J, **75** : 734-743, 2011.
4. Kuchynka P, Palecek T, Masek M, *et al*. Current diagnostic and therapeutic aspects of eosinophilic myocarditis. Biomed Res Int, 2016 : 2829583. doi : 10.1155/2016/2829583.
5. Rizkallah J, Desautels A, Malik A, *et al*. Eosinophilic myocarditis : two case reports and review of the literature. BMC Res Notes, **6** : 538, 2013. doi : 10.1186/1756-0500-6-538.
6. Şimşek E, Özerkan Çakan F, Akın M. Eosinophilic myocarditis presenting as acute coronary syndrome. Turk Kardiyol Dern Ars, **45** : 358-361, 2017.
7. Morimoto S, Kubo N, Hiramitsu S, *et al*. Changes in the peripheral eosinophil count in patients with acute eosinophilic myocarditis. Heart Vessels, **18** : 193-196, 2003.
8. Teefey SA, Baron RL, Bigler SA. Sonography of the gallbladder : significance of striated (layered) thickening of the gallbladder wall. Am J Roentgenol, **156** : 945-947, 1991.
9. Kindermann I, Barth C, Mahfoud F, *et al*. Update on myocarditis. J Am Coll Cardiol, **59** : 779-792, 2012.
10. Fung G, Luo H, Qiu Y, *et al*. Myocarditis. Circ Res, **118** : 496-514, 2016.
11. Desautels CN, Tierney DM, Rossi F, Rosborough TK. Case report : an unrecognized etiology of transient gallbladder pain in heart failure diagnosed with internist-performed point-of-care ultrasound. Crit Ultrasound J, **7** : 2, 2015. doi : 10.1186/s13089-014-0019-8.
12. Cho HJ, Park CH, Kim JS, *et al*. Edema of pancreas and gallbladder misread as inflammation in cardiac tamponade. Ann Thorac Surg, **97** : 1455, 2014. doi : 10.1016/j.athoracsur.2013.09.075.

13. Donnelly LF, Kimball TR, Barr LL. Purulent pericarditis presenting as acute abdomen in children : abdominal imaging findings. Clin Radiol, **54** : 691-693, 1999.
14. Nikolaou M, Parissis J, Yilmaz MB, *et al*. Liver function abnormalities, clinical profile, and outcome in acute decompensated heart failure. Eur Heart J, **34** : 742-749, 2013.
15. van Deursen VM, Damman K, Hillege HL, van Beek AP, van Veldhuisen DJ, Voors AA. Abnormal liver function in relation to hemodynamic profile in heart failure patients. J Card Fail, **16** : 84-90, 2010.
16. Suzuki H, Akiba T, Yoshikawa M, *et al*. A case of acute benign myopericarditis with transient marked eosinophilia in the convalescent period. (In Japanese) Shinzo (Heart), **21** : 313-319, 1989.
17. Hata H, Maruoka Y, Yamada K, Hamanaka N. A case of acute peri-myocarditis with transient eosinophilia in the convalescent period. (In Japanese) Shinzo (Heart) **31** : 241-247, 1999.
18. Hara T, Yamaguchi K, Iwase T, *et al*. Eosinophilic myocarditis due to Churg-Strauss syndrome with markedly elevated eosinophil cationic protein. Int Heart J, **54** : 51-53, 2013.
19. Fozing T, Zouri N, Tost A, *et al*. Management of a patient with eosinophilic myocarditis and normal peripheral eosinophil count : Case report and literature review. Circ Heart Fail, **7** : 692-694, 2014.
20. Inoh T, Tsukitani M, Adachi Y, Motooka T, Fukuzaki H. A case of acute peri-myocarditis associated with delayed appearance of eosinophilia. Kobe J Med Sci, **26** : 223-228, 1980.
21. Ono N, Shimizu Y, Kasai A, *et al*. Eosinophilic heart disease with favorable courses : report of two cases. (In Japanese abstract in English) J Cardiol, **21** : 171-181, 1991.
22. Ishide T, Shimizu M, Nakayama A, *et al*. A case of hypereosinophilic endomyocarditis showing benign clinical course : a case report and review of 25 cases of this syndrome in Japan. (In Japanese abstract in English) Kokyu To Junkan (Respiration & Circulation), **33** : 473-477, 1985.
23. Mori N, Morimoto S, Hiramitsu S, *et al*. Eosinophilic myocarditis in which the appearance of cardiac symptoms preceded an increased eosinophil count. (In Japanese) Nihon Naika Gakkai Zasshi (Journal of Japanese Society of Internal Medicine), **93** : 367-369, 2004.
24. Yamamoto K, Kasamatsu K, Nakanishi H, *et al*. A case of acute peri-myocarditis with virus infection and eosinophilia. (In Japanese) Shinzo (Heart) **34** : 279-285, 2002.
25. Agrawal S, Vohra S, Rawat S, Kashyap V. Eosinophilic ascites : A diagnostic and therapeutic challenge. World J Gastrointest Surg. **8** : 656-659, 2016.