Title	Massive subcutaneous emphysema, bilateral pneumothorax, pneumomediastinum, pneumoperitoneum, pneumoretroperitoneum, and pneumoscrotum after multiple direct laryngoscopies: an autopsy case report
Author(s)	Ono, Yuko; Okubo, Yoshinori; Hashimoto, Katsuhiko; Inokuchi, Ryota; Odajima, Hajime; Tase, Choichiro; Shinohara, Kazuaki
Citation	Journal of anesthesia. 29(4): 622-626
Issue Date	2015-08
URL	http://ir.fmu.ac.jp/dspace/handle/123456789/524
Rights	© Japanese Society of Anesthesiologists 2015. The final publication is available at link.springer.com.
DOI	10.1007/s00540-015-1997-9
Text Version	author

Massive subcutaneous emphysema, bilateral pneumothorax, pneumomediastinum, pneumoperitoneum, pneumoretroperitoneum, and pneumoscrotum after multiple direct laryngoscopies: an autopsy case report

Yuko Ono[1,2]* • Yoshinori Okubo[1] • Katsuhiko Hashimoto[1] • Ryota Inokuchi[1,3] • Hajime Odajima[4] • Choichiro Tase[2] • Kazuaki Shinohara[1]

[1]Department of Anesthesiology, Ohta General Hospital Foundation, Ohta Nishinouchi Hospital, Koriyama, Japan

[2]Emergency and Critical Care Medical Center, Fukushima Medical University Hospital, Fukushima, Japan

[3]Department of Emergency and Critical Care Medicine, The University of Tokyo Hospital, Tokyo, Japan.

[4]Department of Pathology, Ohta General Hospital Foundation, Ohta Nishinouchi Hospital, Koriyama, Japan

***Corresponding Author:**

Yuko Ono, MD

Department of Anesthesiology, Ohta General Hospital Foundation, Ohta Nishinouchi Hospital,

2-5-20 Nishinouchi, Koriyama, Fukushima 963-8558, Japan

Tel.: +81-024-925-1188, Fax: +81-024-925-7791, E-mail: windmill@fmu.ac.jp

Keywords: Airway management • Airway trauma • Cardiopulmonary resuscitation • Iatrogenic injury

Word count: 1,369 words

Number of tables: 0

Number of figures: 3

Abstract

Multiple endotracheal intubation (ETI) attempts increase the risk of airway-related adverse events. However, little is known about autopsy findings after severe ETI-related complications. We present the detailed pathological findings of a case with severe ETI-related complications. A 77-year-old obese male suffered cardiopulmonary arrest after choking at a rehabilitation facility. Spontaneous circulation returned after chest compressions and foreign-body removal. After multiple failed direct laryngoscopies, the patient was transferred to our hospital. He had massive subcutaneous emphysema, bilateral pneumothorax, pneumomediastinum, pneumoperitoneum, pneumoretroperitoneum, and pneumoscrotum on admission and died from hypoxic brain injury 15 hours later. Autopsy revealed severe oropharyngeal; laryngeal; and left lung lower lobe injury. The likely mechanisms of diffuse emphysema were: 1) oropharyngeal injury associated with multiple ETI attempts and excessive ventilation pressures and 2) left lung lower lobe injury associated with chest compressions and other resuscitative procedures. Multiple laryngoscopies can cause severe upper-airway injury, worsen respiratory status, and make ETI more difficult—a vicious circle that can be prevented by limiting ETI attempts. This is particularly important in unfavorable environments, in which backup devices and personnel are not easily obtained. The pathological findings of our patient caution against repeated attempts at ETI during resuscitation.

Introduction

Emergency airway management is a critical intervention that can be fraught with severe complications. Multiple attempts at endotracheal intubation (ETI) are known to be associated with increased risk of airway-related adverse events [1, 2] that can cause serious consequences, including tracheal rupture [3], massive subcutaneous emphysema [3–6], pneumomediastinum [3, 5, 6], pneumothorax [4], and pneumoperitoneum [4]. An autopsy case exhibiting these severe complications is extremely rare, and detailed pathological findings of severe ETI-related complications have not been reported. We present autopsy findings of a case of massive subcutaneous emphysema, bilateral pneumothorax, pneumomediastinum, pneumoperitoneum, pneumoretroperitoneum, and pneumoscrotum; complications likely associated with multiple direct laryngoscopies, excessive ventilation pressure, and chest compressions.

Case description

A 77-year-old obese male with a history of obstructive sleep apnea and left putaminal hemorrhage choked on a piece of bread at a rehabilitation facility and suffered cardiopulmonary arrest. Spontaneous circulation returned after chest compressions by nurses and foreign-body

removal and manual bag ventilation by an in-house rehabilitation doctor. After return of spontaneous circulation, the doctor attempted ETI with a direct laryngoscope because the patient exhibited agonal respirations. Because no portion of the larynx could be visualized, the doctor applied greater lifting force with each laryngoscopy. After more than three failed ETI attempts, the patient was transferred to our hospital under manual bag ventilation by the rehabilitation doctor. On admission, the patient was deeply comatose (Glasgow Coma Scale score of 3). There was no spontaneous breathing, but his common carotid and femoral arteries were palpable. Manual bag resistance was extremely strong, making ventilation difficult. We observed significant subcutaneous emphysema in the patient's face, neck, trunk, genitals, and extremities; neck emphysema was particularly severe. In addition, copious bleeding from oropharyngeal laceration prevented the use of either a video laryngoscope or a supraglottic airway device (SGA). ETI was difficult (Cormack–Lehane grade 3 on direct laryngoscopy) but successful on the first attempt by an anesthesiologist. Duration of manual bag ventilation before successful ETI was about 1 hour. Computed tomography revealed diffuse subcutaneous emphysema, bilateral pneumothorax, pneumomediastinum, pneumoperitoneum, pneumoretroperitoneum, and pneumoscrotum (Fig. 1). Despite multiple rescue attempts, including bilateral thoracic drainage and mechanical ventilation, the patient died from hypoxic brain injury 15 hours after admission. Autopsy revealed severe lacerations of the tongue and

valleculae with substantial hematoma (Fig. 2a), injuries to the hypopharynx and larynx (right epiglottis and right arytenoid cartilage [Fig. 2b]), and left lung lower lobe disruption (mediastinal side of posterior basal segment [S10] and superior segment [S6]) (Fig. 3). There was no thoracic wall injury, rib fracture, or right lung injury. Hematoma was present at the esophageal orifice. The patient's stomach was severely distended with air, but there was no rupture of the esophagus, stomach, or lower digestive tract and no laceration of the trachea. A pathologist determined the causes of emphysema to be 1) oropharyngeal injury due to multiple ETI attempts and excessive ventilation pressures and 2) left lung lower lobe injury associated with chest compressions and other resuscitative measures.

Discussion

This case involved severe complications arising from multiple attempts at direct laryngoscopy. Diffuse, massive emphysema was likely caused by air entering the soft tissues of the neck through an oropharyngeal laceration and dissecting into the mediastinum, pleural space, peritoneal cavity, retroperitoneal space, and scrotum [4]. Possible aggravating factors were 1) tongue swelling due to multiple laryngoscopies, resulting in the need for excessive ventilation pressures, and 2) a considerable amount of time (about 1 hour) elapsing before an endotracheal

tube was past the upper-airway lesion. Multiple ETI attempts can create a vicious circle, especially in a compromised case, in which multiple laryngoscopies cause upper-airway injury, exacerbate upper-airway edema, worsen respiratory status, and make ETI more difficult, which leads to further complications. Once upper-airway injury occurs, the endotracheal tube must traverse the lesion and the cuff must be inflated as soon as possible; this is to prevent the injury site proximal to the cuff from being exposed to positive ventilation pressure and to prevent wider spread of the emphysema. Dental and oral surgery case reports [7–9] demonstrate that pneumothorax, systemic air embolism, and even death can be caused by pressurized air entering an oropharyngeal wound. Even when ETI proves difficult, the tendency is for many laryngoscopists as well as second laryngoscopists to attempt ETI repeatedly [10]. Connelly et al. [11] reported that when direct laryngoscopy is unsuccessful, additional attempts using the same technique have close to an 80% failure rate, while the use of an alternative technique (i.e., SGA and video laryngoscopy) is more successful. There is much evidence to support the usefulness of an SGA [12–14] and video laryngoscopy [15–18] in difficult airway management. Most airway management guidelines [19–21] also emphasize that attempts at direct laryngoscopy should be limited and that alternative techniques should be attempted. Studies by Mort [1] and Hasegawa et al. [2] revealed that rates of complication associated with emergency ETI

dramatically increase when more than two laryngoscopies are performed.

This case also illustrates a problem associated with difficult airway management in adverse environments. It is risky to perform ETI in prehospital settings and most chronic-disease hospitals because of the lack of backup personnel and equipment [22]. Neither a video laryngoscope nor an SGA was available at this rehabilitation facility. Managing a difficult airway in such a setting is challenging even for an experienced provider [22], and past reports have revealed that both ETI difficulty [23, 24] and severe ETI-related complications [25, 26] can be increased in such situations. Results of a study by Paal et al. [22] suggested that avoiding repeated ETI attempts is much more important in the prehospital setting than in the emergency or operating room. In the present case, manual bag ventilation was possible after removal of the foreign body. The most appropriate treatment would have been immediate transfer to a hospital to obtain senior help with manual bag ventilation, rather than to continue to attempt ETI in an environment in which backup devices and personnel were not available.

Another important cause of the severe emphysema in this case was left lung lower lobe (S10 and S6) disruption as a complication of chest compressions and other resuscitative procedures. In this case, thoracic wall injury and rib fracture did not occur and lung injury was limited to the left mediastinal side, which was away from the chest compression site. The most likely etiology of the left lung injury was therefore increased intrathoracic pressure associated

with chest compressions and positive-pressure ventilation. Although the *push-hard-and-push-fast* technique advocated by the 2010 American Heart Association Guidelines for Cardiopulmonary Resuscitation and Emergency Cardiovascular Care [27] produces effective chest compressions, it may have exacerbated the complications seen in this case. The lesson here is that, even in the absence of thoracic wall injury and rib fractures, lung disruption may be present after vigorous chest compression. This warrants active post-resuscitative follow-up of the lungs. We regard the disrupted left lower lung to have been the major cause of the subcutaneous emphysema, bilateral pneumothorax, pneumomediastinum, pneumoperitoneum, pneumoretroperitoneum, and pneumoscrotum in this patient. Nevertheless, we believe that oropharyngeal injury associated with multiple direct laryngoscopies was also responsible for these pathologies because 1) neck emphysema was especially severe, and 2) even tiny oropharyngeal lacerations can cause severe subcutaneous emphysema and pneumomediastinum [6, 28].

We believe this case represents a novel complication, as we were unable to find any report describing pneumoretroperitoneum after both cardiopulmonary resuscitation and repeated ETI attempts. It is possible that the diffuse massive emphysema originating from oropharyngeal and left lung lacerations was pushed into the retroperitoneal space by vigorous chest compressions.

In conclusion, the massive subcutaneous emphysema, bilateral pneumothorax, pneumomediastinum, pneumoperitoneum, pneumoretroperitoneum, and pneumoscrotum seen in this case were likely caused by oropharyngeal injury associated with multiple direct laryngoscopies; and left lung injury associated with chest compressions. This case represents severe complications arising from multiple attempts at direct laryngoscopy and cautions against repeated attempts at ETI during resuscitation, especially in adverse settings.

Acknowledgment

The authors wish to thank Nozomi Ono, MD (Department of Psychiatry, Hoshigaoka Hospital, Koriyama, Japan); Testuhiro Yano, MD (Emergency and Critical Care Medical Center, Fukushima Medical University Hospital, Fukushima, Japan); and Makiko Ono, MD (Department of Anesthesiology, Fukushima Medical University Hospital, Fukushima, Japan) for their assistance and helpful advice.

References

1. Mort TC. Emergency tracheal intubation: complications associated with repeated laryngoscopic attempts. Anesth Analg. 2004;99:607–13.

2. Hasegawa K, Shigemitsu K, Hagiwara Y, Chiba T, Watase H, Brown CA 3rd, Brown DF; Japanese Emergency Medicine Research Alliance Investigators. Association between repeated intubation attempts and adverse events in emergency departments: an analysis of a multicenter prospective observational study. Ann Emerg Med. 2012;60:749–54.

3. Gries CJ, Pierson DJ. Tracheal rupture resulting in life-threatening subcutaneous emphysema. Respir Care. 2007;52:191–5.

4. Chortkoff BS, Perlman B, Cohen NH. Delayed pneumothorax following difficult tracheal intubation. Anesthesiology. 1992;77:1225–7.

5. Watters KF, Lacy PD, Walsh RM. Massive subcutaneous emphysema following routine endotracheal intubation. J Laryngol Otol. 2003;117:899–901.

6. Cavuslu S, Oncul O, Gungor A, Kizilkaya E, Candan H. A case of recurrent subcutaneous emphysema as a complication of endotracheal intubation. Ear Nose Throat J. 2004;83:485–8.

7. Davies JM, Campbell LA. Fatal air embolism during dental implant surgery: a report of three cases. Can J Anaesth. 1990;37:112–21.

8. Magni G, Imperiale C, Rosa G, Favaro R. Nonfatal cerebral air embolism after dental surgery. Anesth Analg. 2008;106:249–51.

9. McKenzie WS, Rosenberg M. Iatrogenic subcutaneous emphysema of dental and surgical origin: a literature review. J Oral Maxillofac Surg. 2009;67:1265–8.

10. Cook TM, MacDougall-Davis SR. Complications and failure of airway management. Br J Anaesth. 2012;109 Suppl 1:i68–i85.

11. Connelly NR, Ghandour K, Robbins L, Dunn S, Gibson C. Management of unexpected difficult airway at a teaching institution over a 7-year period. J Clin Anesth. 2006;18:198–204.

12. Frappier J, Guenoun T, Journois D, Philippe H, Aka E, Cadi P, Silleran-Chassany J, Safran D: Airway management using the intubating laryngeal mask airway for the morbidly obese patient. Anesth Analg. 2003;96:1510–5.

13. Caponas G. Intubating laryngeal mask airway. Anaesth Intensive Care. 2002;30:551–69.

14. Kihara S, Watanabe S, Brimacombe J, Taguchi N, Yaguchi Y, Yamasaki Y. Segmental cervical spine movement with the intubating laryngeal mask during manual in-line stabilization in patients with cervical pathology undergoing cervical spine surgery. Anesth Analg. 2000;91:195–200.

15. Sakles JC, Mosier J, Chiu S, Cosentino M, Kalin L. A comparison of the C-MAC video laryngoscope to the Macintosh direct laryngoscope for intubation in the emergency department. Ann Emerg Med. 2012;60:739–48.

16. Aziz MF, Dillman D, Fu R, Brambrink AM: Comparative effectiveness of the C-MAC video laryngoscope versus direct laryngoscopy in the setting of the predicted difficult airway.

Anesthesiology. 2012;116:629–36.

17. Enomoto Y, Asai T, Arai T, Kamishima K, Okuda Y: Pentax-AWS, a new videolaryngoscope, is more effective than the Macintosh laryngoscope for tracheal intubation in patients with restricted neck movements: a randomized comparative study. Br J Anaesth. 2008;100:544–8.

18. Jungbauer A, Schumann M, Brunkhorst V, Börgers A, Groeben H. Expected difficult tracheal intubation: a prospective comparison of direct laryngoscopy and video laryngoscopy in 200 patients. Br J Anaesth. 2009;102:546–50

19. Henderson JJ, Popat MT, Latto IP, Pearce AC; Difficult Airway Society. Difficult Airway Society guidelines for management of the unanticipated difficult intubation. Anaesthesia. 2004;59:675–94.

20. Japanese Society of Anesthesiologists. JSA airway management guideline 2014: to improve the safety of induction of anesthesia. J Anesth. 2014;28:482–93.

21. Apfelbaum JL1, Hagberg CA, Caplan RA, Blitt CD, Connis RT, Nickinovich DG, Hagberg CA, Caplan RA, Benumof JL, Berry FA, Blitt CD, Bode RH, Cheney FW, Connis RT, Guidry OF, Nickinovich DG, Ovassapian A; American Society of Anesthesiologists Task Force on Management of the Difficult Airway. Practice guidelines for management of the difficult airway: an updated report by the American Society of Anesthesiologists Task Force on Management of the Difficult Airway. Anesthesiology. 2013;118:251–70.

22. Paal P, Herff H, Mitterlechner T, von Goedecke A, Brugger H, Lindner KH, Wenzel V.

Anaesthesia in prehospital emergencies and in the emergency room. Resuscitation. 2010;81:148–54.

23. Adnet F, Borron SW, Racine SX, Clemessy JL, Fournier JL, Plaisance P, Lapandry C. The intubation difficulty scale (IDS): proposal and evaluation of a new score characterizing the complexity of endotracheal intubation. Anesthesiology. 1997;87:1290–7.

24. Adnet F, Jouriles NJ, Le Toumelin P, Hennequin B, Taillandier C, Rayeh F, Couvreur J, Nougière B, Nadiras P, Ladka A, Fleury M. Survey of out-of-hospital emergency intubations in the French prehospital medical system: a multicenter study. Ann Emerg Med. 1998;32:454–60.

25. Timmermann A, Russo SG, Eich C, Roessler M, Braun U, Rosenblatt WH, Quintel M. The out-of-hospital esophageal and endobronchial intubations performed by emergency physicians. Anesth Analg. 2007;104:619–23.

26. Ufberg JW, Bushra JS, Karras DJ, Satz WA, Kueppers F. Aspiration of gastric contents: association with prehospital intubation. Am J Emerg Med. 2005;23:379–82.

27. Berg RA, Hemphill R, Abella BS, Aufderheide TP, Cave DM, Hazinski MF, Lerner EB, Rea TD, Sayre MR, Swor RA. Part 5: adult basic life support: 2010 American Heart Association Guidelines for Cardiopulmonary Resuscitation and Emergency Cardiovascular Care. Circulation. 2010;122:S685–S705.

28. Kim SW, Kang HH, Kang JY, Kim SK, Lee BY, Lee SH, Moon HS. A case of pneumomediastinum and parapneumonic effusions following pharyngeal perforation caused by

shouting. Yonsei Med J. 2014;55:270–2.

Figure legends

Fig. 1 Computed tomography imaging. **a** Whole-body coronal section showing massive subcutaneous emphysema, bilateral pneumothorax, pneumomediastinum, pneumoperitoneum, and pneumoscrotum (arrows). **b** Axial view of the upper abdomen showing massive pneumoperitoneum (white circle) and pneumoretroperitoneum (black circle). **c** Axial view of the groin showing massive pneumoscrotum (white circle).

Fig. 2 Upper-airway injury associated with multiple ETI attempts. Photographs showing **a** lacerations of the tongue and valleculae with substantial hematoma (white arrows) and **b** injuries to right epiglottis and right arytenoid cartilage (white arrows). ETI, endotracheal intubation.

Fig. 3 Photograph showing disruption of the left lung lower lobe (mediastinal side of S10 and S6) associated with chest compressions and other resuscitative measures. (white circle).

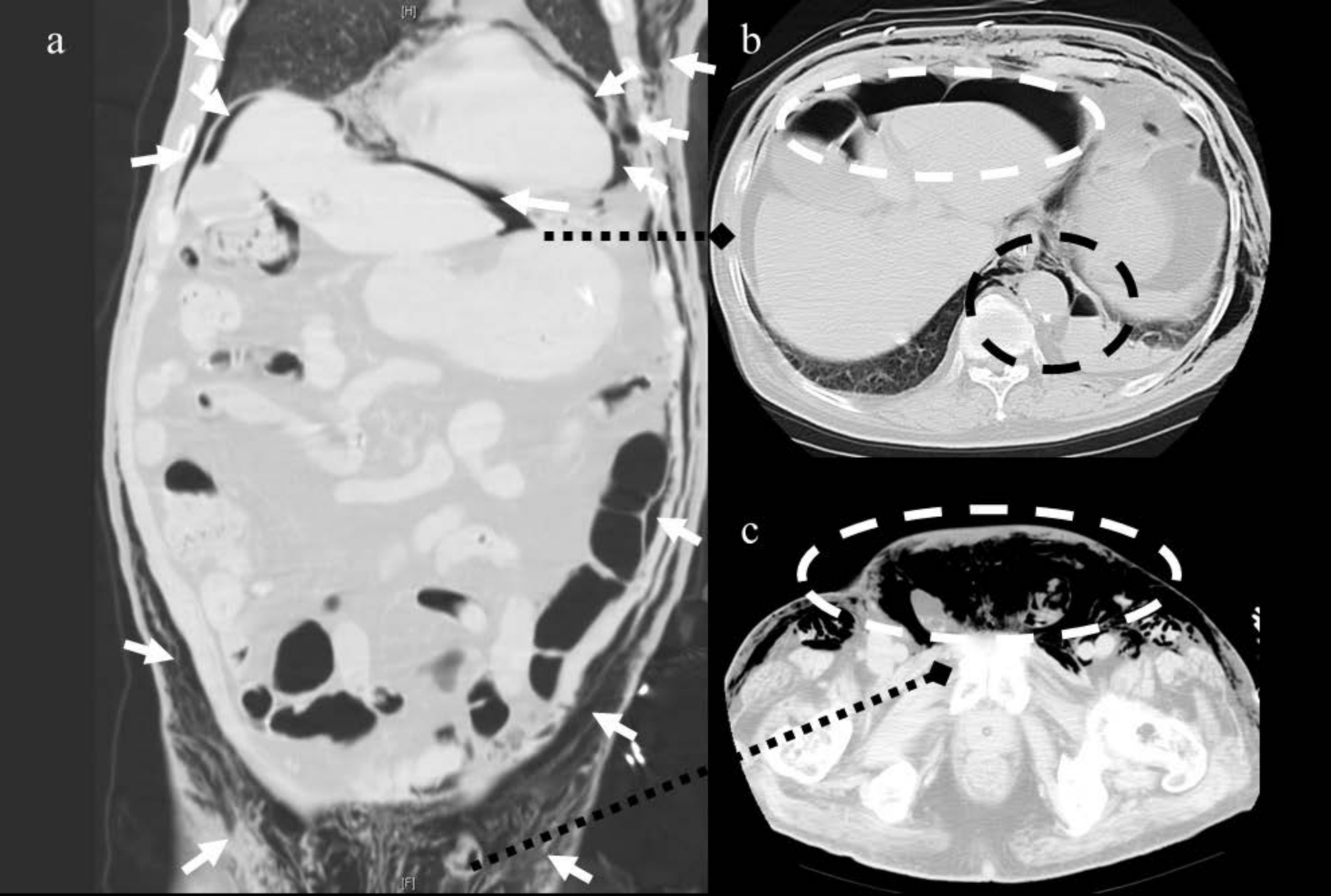
a
b
c

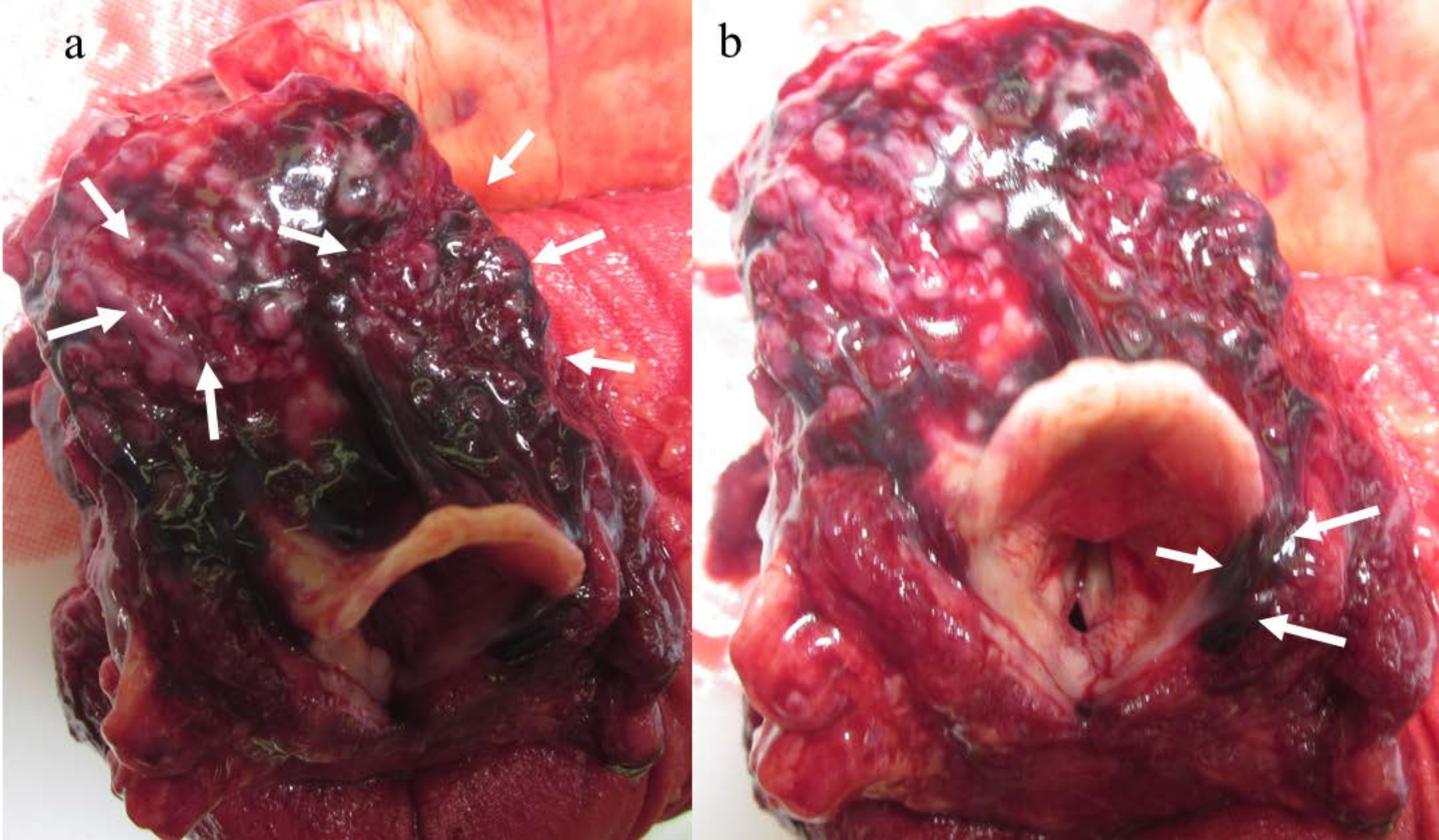
a
b