福島県立医科大学 学術機関リポジトリ

FUKUSHIMA MEDICAL UNIVERSITY

Title	A case of overlap syndrome of primary biliary cirrhosis and autoimmune hepatitis with marked elevation of IgM
Author(s)	Katsushima, Fumiko; Takahashi, Atsushi; Suzuki, Tomohiro; Ejiri, Yutaka; Abe, Kazumichi; Ohira, Hiromasa
Citation	Fukushima Journal of Medical Science. 59(1): 63-67
Issue Date	2013
URL	http://ir.fmu.ac.jp/dspace/handle/123456789/367
Rights	© 2013 The Fukushima Society of Medical Science
DOI	10.5387/fms.59.63
Text Version	publisher

This document is downloaded at: 2024-04-19T19:05:05Z

Fukushima Medical University

Fukushima J. Med. Sci.,
Vol. 59, No. 1, 2013

[Case Report]

A CASE OF OVERLAP SYNDROME OF PRIMARY BILIARY CIRRHOSIS AND AUTOIMMUNE HEPATITIS WITH MARKED ELEVATION OF IgM

FUMIKO KATSUSHIMA[1)], ATSUSHI TAKAHASHI[1)], TOMOHIRO SUZUKI[2)], YUTAKA EJIRI[2)], KAZUMICHI ABE[1)] and HIROMASA OHIRA[1)]

[1)]*Department of Gastroenterology and Rheumatology, Fukushima Medical University School of Medicine, 1-Hikarigaoka, Fukushima 960-1295, Japan,* [2)]*Gastroenterology of Fukushima Rousai Hospital*

(Received August 22, 2012, accepted March 18, 2013)

Abstract : A 60-year-old woman was admitted to our hospital because of anorexia and vomiting. Hematology revealed elevated levels of hepatobiliary enzymes and positive results for antinuclear antibody (ANA) and antimitochondrial (AMA) M2 antibody. Immunoglobulin (Ig) G and IgM levels were extremely elevated, 3,379 mg/dl and 4,250 mg/dl, respectively. A diagnosis of primary biliary cirrhosis and autoimmune hepatitis (PBC-AIH) overlap syndrome was made. However, IgM levels as high as the level of 4,250 mg/dl in this case has not been reported previously. This case may be of value in studying elevated IgM levels with PBC-AIH overlap syndrome and relationships to the mechanism of onset.

Key words : IgM, PBC-AIH overlap syndrome, toll-like receptor 9, predonisolone

INTRODUCTION

Primary biliary cirrhosis and autoimmune hepatitis (PBC-AIH) overlap syndrome is characterized by features and findings of both PBC and AIH. Elevated immunoglobulin (Ig) M levels are a serological characteristic of PBC, and involvement of natural immune response in the mechanism of elevation has been revealed. IgM level reportedly tends to be higher in PBC-AIH overlap syndrome than in PBC alone[1,2,3)]. However, a search of the literature did not show any other cases of PBC-AIH overlap syndrome with IgM level as high as the level of 4,250 mg/dl in this case or higher than the IgG level.

CASE REPORT

A 60-year-old woman had been experiencing anorexia and vomiting since February 10, 2007. She was hospitalized on March 9 for examination and treatment. On admission, her conjunctivae were slightly icteric, her liver and spleen were not palpable, and her legs showed no edema. The patient had a prior history of gastric polyps and gastric ulcer at 60 years old, a 34-year history of smoking, and no history of alcohol consumption. There was no family history of liver disease. She was taking no medications when the symptoms developed. Laboratory data on admission are shown in Table 1. Hepatobiliary enzymes were elevated : aspartate aminotransferase, 907 IU/l ; alanine aminotransferase (ALT), 529 IU/l ; alkaline phosphatase (ALP), 970 IU/l ; γ-glutamyl transpeptidase, 533 IU/l ; and total bilirubin, 2.5 mg/dl. Prothrombin time was 75% and fibrosis markers were slightly elevated. Results for hepatitis viruses A, B, and C were negative. Antinuclear antibody (ANA) was positive, at 1 : 320, and anti-SS-A and anti-SS-B antibodies were negative. Antimitochondrial antibody (AMA) M2 was positive, at 72.4 U/ml. IgG and IgM levels were extremely elevated, 3,597 mg/dl and 4,250 mg/dl, respectively. Abdominal computed tomography (CT) suggested chronic hepatitis (Fig. 1). Biopsy of the liver revealed lymphocyte and plasma cell infiltration, with moderate interface hepatitis and interlobular bile duct destruction (Fig. 2). Immunoelectrophoresis revealed polyclonal increase because

Corresponding author : Fumiko Katsushima E-mail address : f.katsushima@gmail.com (F. Katsushima)
https://www.jstage.jst.go.jp/browse/fms http://www.fmu.ac.jp/home/lib/F-igaku/

Table 1. Clinical data on admission.

Hematology					
WBC	3,700/μl	AST	907 IU/l	ANA (homogeneous)	×2,560
Ne	55%	ALT	529 IU/l	AMA-M2Ab	×72.4
Ly	30%	LDH	338 IU/l	anti-SS-AAb	(−)
Hb	11.5 g/dl	ALP	970 IU/l	anti-SS-B-Ab	(−)
Plt	23×10^4/μl	GGT	533 IU/l		
		FBS	94 mg/dl	**Viral markers**	
Coagulation		TC	170 mg/dl	IgM-HA-Ab	(−)
PT	75%	Type IV collagen 7S	15.8 ng/ml	HBs-Ag	(−)
APTT	67 s	Hyaluronic acid	373 ng/ml	HCV-Ab	(−)
				CMV-IgM	(−)
Biochemistry		**Serology**		CMV-IgG	(+)
TP	10.8 g/dl	CRP	1.7 mEq/l	EBV anti-VCA-IgM	(−)
Alb	3.0 g/dl	IgG	3,597 mg/dl	EBV anti-VCA-IgG	(+)
γ-glob	5.5 g/dl	IgA	280 mg/dl	EBV anti-EBNA-IgG	(+)
TB	2.5 mg/dl	IgM	4,250 mg/dl		
DB	1.7 mg/dl				

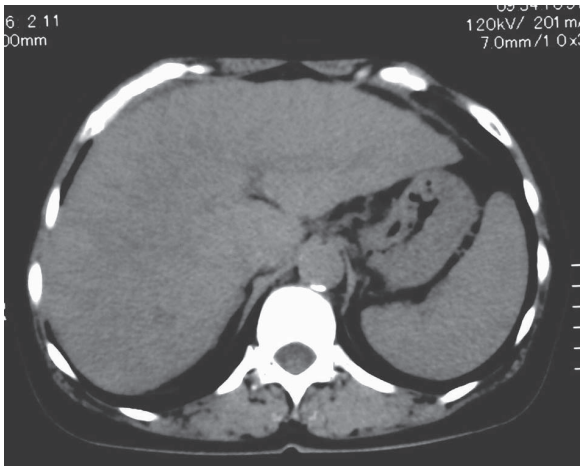

Fig. 1. Abdominal CT
CT revealed mildly irregular hepatic contour, with heterogeneity of the parenchyma, suggestive of chronic hepatitis. No hepatic enlargement, atrophy, or neoplastic lesions were evident. Mild splenomegaly was also observed.

abnormal bands such as M protein were not detected. No evidence of tumor cells or elevated lymphocytes was seen in bone-marrow aspirate. The results of laboratory data and hepatic histology met the diagnostic criteria for PBC-AIH overlap[4]. On March 24, treatment was started with predonisolone (PSL) at 30 mg/day and ursodoxycholic acid at 600 mg/day, resulting in rapid improvement in liver function (Fig. 3). The extremely high IgM level of 4,250 mg/dl also fell rapidly, to 276 mg/dl by July. PSL was gradually tapered to 7.5 mg/day in October, but ALT and ALP levels increased with recurrence of hepatitis. The PSL dose was consequently increased to 20 mg/day, resulting in evident improvement in liver function. When hepatitis recurred, IgM also increased again to 504 mg/dl but fell to 160 mg/dl with the improvement in hepatitis. ANA and AMA M2 decreased gradually despite recurrence. Azathioprine was also added in January 2008, and PSL was tapered to 5 mg/day. Five years has since passed without any further recurrence or development of any malignant disease.

DISCUSSION

PBC-AIH overlap syndrome is a condition characterized by features and findings of both PBC and AIH. Elevated IgM is thus a common finding, as in PBC[1,2,3,5]. However, it is unusual to see an increase in IgM as high as the level of 4,250 mg/dl seen in this case or higher than the IgG level. Diseases involving polyclonal increases in IgM such as in this case include rheumatoid arthritis, Sjögren syndrome, acute hepatitis type A, and chronic nephritis, in addition to PBC, and PBC-AIH overlap. PBC is often associated with Sjögren's syndrome[6,7], but this was not the situation in our case, which had no the symptoms of dryness and showed negative results for anti-SS-A and anti-SS-B antibodies. Chronic nephritis was also ruled out because renal function and urinary findings were normal. Diseases with monoclonal increases, on the other hand, include diseases involving monoclo-

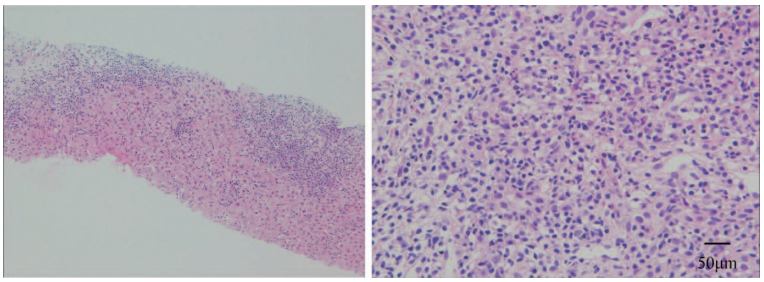

Fig. 2. Histological findings of liver biopsy.
a) Liver biopsy specimen revealed pronounced lymphocyte and plasma cell infiltration on the portal area with advanced interface hepatitis. Magnification : ×40, hematoxylin and eosin staining.
b) Intraepithelial lymphocyte infiltration and interlobular bile duct destruction are apparent around an interlobular bile duct. Magnification : ×200, hematoxylin and eosin staining.

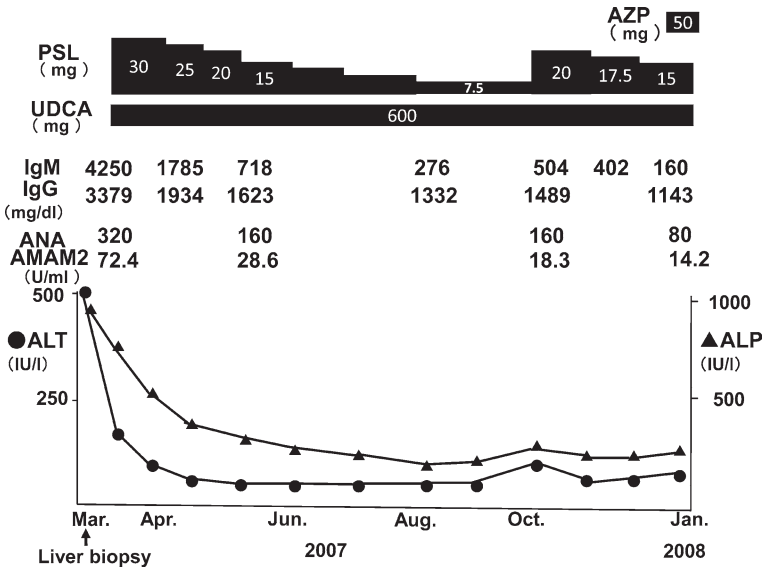

Fig. 3. Clinical course
Treatment with predonisolone (PSL) and ursodeoxycholic acid (UDCA) resulted in a rapid improvement in liver function. The IgM level of 4,250 mg/dl also fell rapidly to 276 mg/dl. PSL was tapered, but hepatitis recurred. IgM level increased again to 504 mg/ml with the recurrence of hepatitis. The PSL dose was therefore increased and azathioprine was also added, resulting in evident improvements in liver function.

nal increases in B cells, particularly macroglobulinemia and chronic lymphocytic leukemia[8]. This case was characterized by polyclonal increases, but the above diseases were ruled out on the basis of results of bone-marrow aspiration.

In our search of the literature, the highest serum IgM level in PBC-AIH overlap was 1,840 mg/dl, reported by Saito *et al.*[1] They reported that the mean level of IgM was significantly higher in 10 patients with PBC-AIH overlap (816±549 mg/dl) than in 103 patients with PBC alone (559±298 mg/dl). In addition, Zhao *et al.* reported that 41.5% patients with PBC-AIH overlap showed isolated IgM elevation[9]. These findings were not reported from Western countries[2,3,8], but we believe in the importance in studying elevation of IgM and its relationship with the onset of PBC-AIH overlap.

As part of the natural immune response, immunoglobulins are the first line of biological defense against infecting microorganisms, thanks to their characteristic agglutinative capacity and complement-activating capacity. The mechanism underlying the increase of serum IgM in PBC has been hypothesized to involve stimulation by CpG followed by an increase in IgM-producing cells and elevated expression of Toll-like receptor (TLR) 9, resulting in a chronic and polyclonal natural immune response to bacteria in PBC, which in turn results in hyperimmunoglobulinemia[10].

On the other hand, bacterial infection itself may be involved in PBC onset. Another possibility is that bacterial protein molecules are modified by

environmental factors such as chemical substances and that a resulting increase in immunogenicity leads to the breakdown of tolerance to self-antigens and the activation of autoreactive T cells[11-13].

AIH mouse models have also shown that CpG stimulation results in the breakdown of immune tolerance and induces transient AIH and that inflammation subsides upon the cessation of stimulation. TLR9 stimulation may also be involved in the onset of AIH[13,14]. In addition, hyperimmunoglobulinemia may have been caused by an excessive natural immune response via elevated TLR9 expression due to chronic bacterial stimulation. Thus, in the present case, some type of bacterial infection may also have resulted in pronounced hyperimmunoglobulinemia, leading to the onset of PBC and AIH.

In this case, we performed immunostaining of TLR9 in the liver specimen according to the method of Benias *et al.*[15] However, there was no obvious difference in TLR9 expression in the liver from that in autoimmune hepatitis (data not shown). Since Benias *et al.* reported that TLR9 was expressed in the liver of chronic hepatitis C similar to that in PBC patients, it is difficult to show the activity of innate immunity only from TLR9 expression. In order to prove that IgM production is increased by the activation of innate immunity in a similar patient, it is necessary to examine IgM production from B cells stimulated by CpG-DNA, serum cytokine levels or TLR9 mRNA expression of lymphocytes infiltrating the liver in future.

In addition, we cannot rule out the possibility that, despite the absence of clinically apparent symptoms of infection in this case, an excessive natural immune response was triggered by some kind of infection during routine living activities, against a background of regulatory T-cell abnormality[16], leading to an increase in IgM level or the onset of PBC-AIH overlap syndrome.

Treatment with a steroid is often effective for PBC-AIH overlap[14,17]. The present case also responded to steroid treatment, resulting in evident improvement in hepatitis and a decrease in IgM level. A mildly elevated IgM level was also observed during the recurrence of hepatitis, suggesting that IgM level may reflect the disease activity of PBC. Further study of a greater number of cases is necessary.

The mechanisms involved in elevated IgM in PBC and PBC-AIH overlap syndrome and the mechanisms involved in the onset of autoimmune liver disease will hopefully be further elucidated in the future. In summary, this is a rare case report of PBC-AIH overlap with marked elevation of serum IgM. This case report may be of value in studying elevated IgM levels with PBC-AIH overlap syndrome and relationships to the mechanisms of onset.

REFERENCES

1. Saito H, Rai T, Takahashi A, Kanno Y, Monoe K, Irisawa A, Ohira H. Clinicolaboratory characteristics of Japanese patients with primary biliary cirrhosis-autoimmune hepatitis overlap. Fukushima J Med Sci, **52** : 71-77, 2006.
2. Heurgue A, Vitry F, Diebold MD, Yaziji N, Bernard-Chabert B, Pennaforte JL, Picot R, Louvet H, Frémond L, Geoffroy P, Schmit JL, Cadiot G, Thiéfin G. Overlap syndrome of primary biliary cirrhosis and autoimmune hepatitis : a retrospective study of 115 cases of autoimmune liver disease. Gastroenterol Clin Biol, **31** : 17-25, 2007.
3. Muratori P, Granito A, Pappas G, Pendino GM, Quarneti C, Cicola R, Menichella R, Ferri S, Cassani F, Bianchi FB, Lenzi M, Muratori L. The serological profile of the autoimmune hepatitis/primary biliary cirrhosis overlap syndrome. Am J Gastroenterol, **104** : 1420-1425, 2009.
4. Chazouilleres O, Wendum D, Serfaty L, Serfaty L, Montembault S, Rosmorduc O, Poupon R. Primary biliary cirrhosis-autoimmune hepatitis overlap syndrome : clinical feature and response to therapy. Hepatology, **28** : 296-301, 1998.
5. Lohse AW, zum Buschenfelde KH, Franz B, Kanzler S, Gerken G, Dienes HP. Characterization of the overlap syndrome of primary biliary cirrhosis (PBC) and autoimmune hepatitis : Evidence for it being a hepatitic form of PBC in genetically susceptible individuals. Hepatology, **29** : 1078-1084, 1999.
6. Valera M JM, Smok SG, Poniachik TJ, Oksenberg RD, Silva PG, Ferrario BM, Buckel GE, Brahm BJ. Primary biliary cirrhosis : a thirteen years experience. Rev Med Chill, **134** : 469-474, 2006.
7. Teufel A, Weinmann A, Kahaly GJ, Centner C, Piendl A, Wörns M, Lohse AW, Galle PR, Kanzler S. Concurrent autoimmune disease in patients with autoimmune hepatitis. J Clin Gastroenterol, **44** : 208-213, 2010.
8. Marshall AL. Essential monoclonal gammopathy. In : Kenneth K, Marshall AL, Ernest BM, Thomas JK, Uri Seligsohn, Josef TP, eds. Williams Hepatology, 8th edn. New York : MacGraw-Hill : 1635-1641, 2010.
9. Zhao P, Han Y. Low incidence of positive smooth muscle antibody and high incidence of isolated IgM elevation in Chinese patients with autoimmune hepatitis and primary biliary cirrhosis overlap

syndrome : a reterospective study. BMC Gastroenterol. 12 : 1 http://www.biomedcentral.com/1471-230X/12/1

10. Kikuchi K, Lian ZX, Yang GX, Ansari AA, Ikehara S, Kaplan M, Miyakawa H, Coppel RL, Gershwin ME. Bacterial CpG induces hyper-IgM production in $CD27^+$ memory B cells in primary biliary cirrhosis. Gastroenterology, **128** : 304-312, 2005.
11. Selmi C, Meda F, Kasangian A, Invernizzi P, Tian Z, Lian Z, Podda M, Gershwin ME. Experimental evidence on the immunopathogenesis of primary biliary cirrhosis. Cell Mol Immunol, **7** : 1-10, 2010.
12. Shimoda S, Nakamura M, Shigematsu H, Tanimoto H, Gushima T, Gershwin ME, Ishibashi H. Mimicry peptides of human PDC-E2 163-176 peptide, the immunodominant T-cell epitope of primary biliary cirrhosis. Hepatology, **31** : 1212-1216, 2000.
13. Harada K, Tsuneyama K, Sudo Y, Masuda S, Nakanuma Y. Molecular identification of bacterial 165 ribosomal RNA gene in liver tissue of primary biliary cirrhosis : Is Propionibacterium acnes involved in granuloma formation? Hepatology, **33** : 530-536, 2001.
14. Yokokawa J, Saito H, Kanno Y, Honma F, Monoe K, Sakamoto N, Abe K, Takahashi A, Yokokawa H, Ohira H. Overlap of primary biliary cirrhosis and autoimmune hepatitis : Characteristics, therapy, and long term outcomes. J Gastroenterol Hepatol, **25** : 376-382, 2010.
15. Benias PC, Gopal K, Bodenheimer H Jr, Theise ND. Hepatic expression of toll-like receptors 3, 4, and 9 in primary biliary cirrhosis and chronic hepatitis C. Clin Res Hepatol Gastroenterol, **36** : 448-454, 2012.
16. Lan RY, Cheng C, Lian ZX, Tsuneyama K, Yang GX, Moritoki Y, Chuang YH, Nakamura T, Saito S, Shimoda S, Tanaka A, Bowlus CL, Takano Y, Ansari AA, Coppel RL, Gershwin ME. Liver-targeted and peripheral blood alterations of regulatory T cells in primary biliary cirrhosis. Hepatology, **43** : 729-737, 2006.
17. Ohira H, Takahashi A. Current trends in the diagnosis and treatment of autoimmune hepatitis in Japan. Hepatol Res, **42** : 131-138, 2012.