



Title	A muscle-preserving, spinous process-splitting approach for ossification of the ligamentum flavum in the thoracic spine in professional athletes: a report of three cases
Author(s)	Kato, Kinshi; Yabuki, Shoji; Otani, Koji; Nikaido, Takuya; Otoshi, Kenichi; Watanabe, Kazuyuki; Kobayashi, Hiroshi; Konno, Shin-Ichi
Citation	Fukushima Journal of Medical Science. 69(2): 143-150
Issue Date	2023
URL	http://ir.fmu.ac.jp/dspace/handle/123456789/2161
Rights	© 2023 The Fukushima Society of Medical Science. This article is licensed under a Creative Commons [Attribution-NonCommercial-ShareAlike 4.0 International] license.
DOI	10.5387/fms.2022-32
Text Version	publisher

[Case report]



A muscle-preserving, spinous process-splitting approach for ossification of the ligamentum flavum in the thoracic spine in professional athletes : a report of three cases

Kinshi Kato, Shoji Yabuki, Koji Otani, Takuya Nikaido, Kenichi Otoshi, Kazuyuki Watanabe,
Hiroshi Kobayashi and Shin-ichi Konno

Department of Orthopaedic Surgery, Fukushima Medical University School of Medicine, Fukushima City, Fukushima, Japan

(Received September 22, 2022, accepted March 6, 2023)

Abstract

A muscle-preserving, spinous process-splitting approach may be a less invasive approach to conventional laminectomy in patients with thoracic ossification of the ligamentum flavum. Few reports have discussed the usefulness of this procedure for thoracic lesions in professional athletes who need highly active thoracic spinal function after surgery. The treatment of thoracic ossification of the ligamentum flavum using a spinous process-splitting approach in 3 professional athletes is presented. In all three cases the patients could return to play within 3 months after surgery without complications, and in two of the cases, there was no spinal deformity or local recurrence of ossification of the ligamentum flavum at the final follow-up at least 8 years after surgery. The spinous process-splitting approach could be a safe procedure for multi-level and all other forms of ossification of the ligamentum flavum and is less invasive to the paraspinal muscles, relieves back symptoms, and restores function for athletes.

Key words : thoracic spine, ossification, ligamentum flavum, myelopathy, athletes, case report

Abbreviations : OLF, ossification of the ligamentum flavum ; MRI, magnetic resonance imaging ; CT, computed tomography

Introduction

Conventional laminectomy is commonly used for thoracic ossification of the ligamentum flavum (OLF).¹⁻⁴⁾ However, this procedure is associated with some well-known flaws including damage to the paraspinal muscles and posterior midline complexes, which may result in trunk extensor weakness and back pain.^{5,6)} Additionally, it can cause spinal instability leading to progressive kyphosis.^{6,7)} A spinous process-splitting approach has been recognized as a useful surgical technique for lumbar spinal stenosis, with advantages such as reduced postoperative pain, faster recovery, and reduced spinal instability following laminectomy.⁸⁻¹²⁾ However,

few reports have discussed the usefulness of this approach for thoracic OLF in professional athletes, who require highly active thoracic spinal function after surgery.¹³⁾

We present three cases of professional athletes with thoracic OLF who were successfully treated with a muscle-preserving, spinous process-splitting approach after posterior decompression.

Case presentation

The reporting of this study conforms to CARE guidelines.¹⁴⁾

Corresponding author : Kinshi Kato, MD, Ph D E-mail : kinshi@fmu.ac.jp

©2023 The Fukushima Society of Medical Science. This article is licensed under a Creative Commons [Attribution-NonCommercial-ShareAlike 4.0 International] license.
<https://creativecommons.org/licenses/by-nc-sa/4.0/>

Case 1

A 28-year-old right-handed professional baseball pitcher complained of left buttock and posterior thigh pain and numbness while pitching. His symptoms persisted despite oral non-steroidal anti-inflammatory drugs, leading to referral to our institution after one year of conservative treatment. Neurological examination revealed no muscle weakness or sensory disturbance, but a loss of the left cremaster reflex and increased deep tendon reflexes predominantly on the left side in the lower extremities, raising suspicion of a thoracic or thoracolumbar lesion. Computed tomography (CT) and magnetic resonance imaging (MRI) of the thoracic spine revealed left unilateral OLF at the T10-T11 and T11-T12 levels (Figure 1). Posterior decompression was performed via a spinous process-splitting approach at the T10-11 and T11-12 levels, using a T9, T10, and T11 spinous process-splitting approach (Figure 2). The T9, T10, and T11 spinous processes were split lengthwise in the middle with a bone saw, then detached from the base of the lamina and opened, exposing the lamina and preserving the bilateral paraspinal muscles. Laminectomy was carried out with a high-speed burr, utilizing a retractor between the split spinous process, and the bilateral OLF was removed en bloc (Figure 1f, g). The spinous processes were re-attached with absorbable sutures, and the interspinous and supraspinous liga-

ments were re-approximated with intermittent sutures. No surgical complications such as dural tear, cerebrospinal fluid leak, or surgical site infection were observed. No brace was used after surgery, and three weeks post-operatively, the patient's buttock pain and posterior thigh pain had resolved. He gradually increased his physical activity, throwing at 8 weeks and pitching on the mound 12 weeks after surgery. He resumed full training and was pitching at peak condition 4 months after surgery without symptoms such as back pain, stiffness, and restricted motion. On MRI evaluations 4 months after surgery, no evidence of damage to the paraspinal muscles was seen (Figure 1h, i). Nine months after surgery, he resumed participating in official league games as a starting pitcher, and retired from professional baseball two years after surgery without symptoms. An 8-year follow-up examination revealed no signs of spinal instability, kyphosis, local recurrence of OLF, or the development of OLF at adjacent levels.

Case 2

A 47-year-old professional racing cyclist experienced bilateral thigh numbness during training, followed by left leg weakness a month later. Neurological examination revealed spastic paraparesis (left iliopsoas muscle : manual muscle testing 4) and hyperesthesia of both legs. CT and MRI of the thoracic spine showed an un-fused, enlarged OLF com-

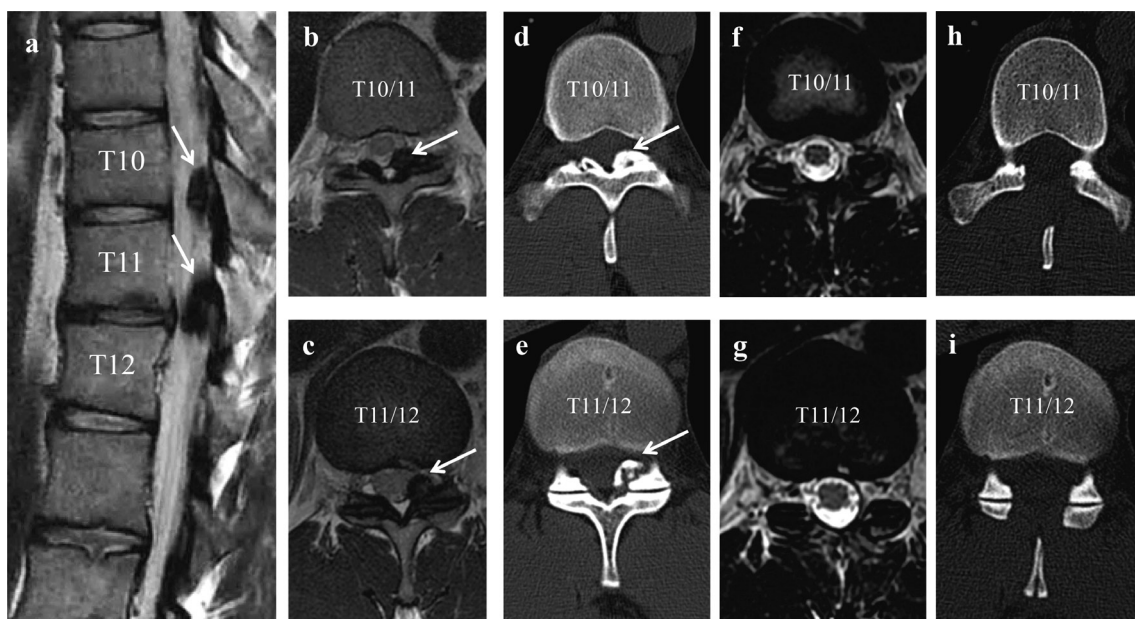


Fig. 1. Pre- and postoperative computed tomography (CT) and magnetic resonance imaging (MRI) findings of Case 1. Sagittal MRI (a) and axial CT and MRI show ossification of the ligamentum flavum (arrows) at T10/11 (b, d) and T11/12 (c, e). Satisfactory decompression is achieved after the spinous process-splitting approach with no evidence of muscle damage (f, g, h, i).

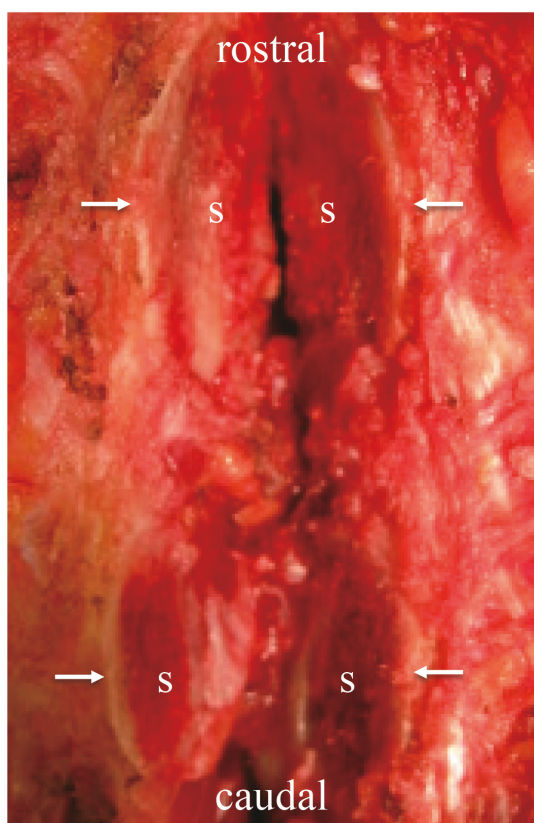


Fig. 2. Intraoperative photographs show the split spinous processes (S, arrows). The spinous process was split longitudinally in the midline and then divided at its base from the lamina of the thoracic spine, leaving the bilateral paraspinal muscles attached to the lateral aspects of the split spinous process.

pressing the spinal cord at the level of T10–T11 (Figure 3a, b). Posterior decompression using the spinous process-splitting approach at the T10–T11 level was performed, resulting in immediate alleviation of the patient's neurological symptoms. The patient started core strengthening exercises a week post-surgery and resumed cycling two weeks later. Four weeks after surgery, the patient resumed participation in official races and limb-strengthening weight training, and returned to optimal performance 12 weeks after surgery without experiencing any back symptoms. MRI scans conducted a year after surgery revealed adequate decompression of the spinal cord and canal without paraspinal muscle damage (Figure 3c, d). In addition, the split spinous processes of T10 had fused together (Figure 4a, b), and complete union was observed at the in-between split spinous process of T11 and the spinolaminar junction 1 year after surgery (Figure 4c, d). He retired from professional racing 2.5 years after surgery without symptoms. At 10 years after

surgery, follow-up examination did not show any spinal instability, kyphosis, local recurrence of OLF, or the development of OLF at adjacent levels.

Case 3

A 25-year-old left-handed professional baseball pitcher experienced left anterior thigh numbness and weakness while pitching during a game. Despite taking a two-week rest, these symptoms persisted and progressed to both thighs and legs. On examination at our institution, he was found to have muscle weakness in the left iliopsoas and quadriceps femoris muscles (manual muscle testing 4), sensory disturbances in both thighs, increased deep tendon reflexes in the lower extremities, and bilateral Babinski signs. CT and MRI of the thoracic spine showed an enlarged, unfused OLF compressing the spinal cord at the T10–T11 level (Figure 5a, b, c). Posterior decompression using the spinous process-splitting approach at this level resulted in immediate improvement of the patient's neurological symptoms (Figure 5d, e, f). He began stationary biking (20–30 minutes a day), core/trunk exercises (abdominal bracing, bridges, anti-rotation exercises), and lower extremity exercises (body weight squat, calf raises, single leg balance) 5 days after surgery. Throwing within 10 meters and jogging were initiated 2 weeks post-surgery. Fielding drills and throwing over 20 meters were started four weeks after surgery, while plyometric drills with full range trunk motion were initiated six weeks post-surgery. The patient was able to pitch on the mound eight weeks after surgery and resume playing in games 16 weeks after the procedure with no subsequent back symptoms or evidence of damage to the paraspinal muscles on MRI evaluation (Figure 5f). He continues to pitch professionally one year after surgery with regular follow-up.

Discussion

We present the treatment of thoracic OLF in 3 professional athletes following posterior decompression with a muscle-preserving, spinous process-splitting approach. All athletes resumed playing within 3 months post-surgery without complications, and two cases showed no spinal deformity or local recurrence of OLF at least 8 years after the procedure. Three significant findings were associated with this less invasive approach for thoracic OLF in athletes. First, it could be safely employed for multi-level and all other forms of OLF. Second, it caused less invasion to the paraspinal muscles, led

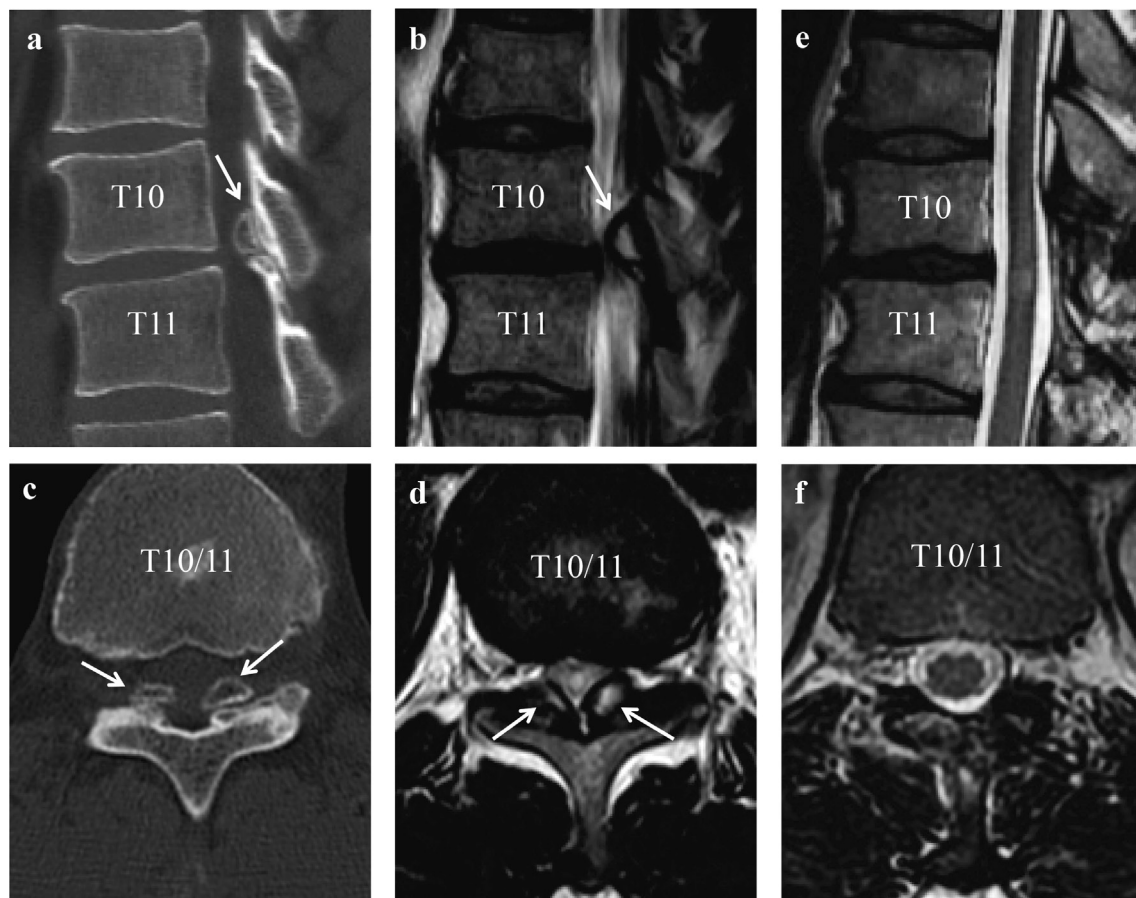


Fig. 3. Pre- and postoperative CT and MRI findings of Case 2. Sagittal CT (a) and MRI (b), axial CT (c) and MRI (d) show OLF at T10/11 (arrows). Satisfactory decompression is achieved after the spinous process-splitting approach (e), and there is no evidence of muscle damage (f).

to greater reduction in back symptoms, and improved function in athletes. Third, the procedure did not result in postoperative spinal deformity or local recurrence of OLF in athletes who require highly active movement of the thoracic spine to participate in their sports.

The muscle-preserving, spinous process-splitting approach could be adaptable to multi-vertebral cases and all forms of thoracic ossification. Thoracic OLF is classified into lateral, extended, enlarged, fusion, and nodular types based on axial CT,²⁾ and the current choice of surgical procedure for thoracic OLF depends on the type of OLF.¹⁻⁴⁾ Open laminectomy is the most commonly used means of achieving sufficient decompression for multi-level and all other forms of OLF, even if large and dural adhesions and ossification exist.^{3,4)} We intended to resect the OLF as much as possible to reduce the local recurrence risk because the repeated, localized mechanical stress caused by sports activity likely influenced the development of OLF, despite the fact that these patients were young.¹⁵⁾ This approach

could be used for both laminectomy and laminotomy, although it cannot be used in cases of small, curved spinous processes. Percutaneous full endoscopic posterior bilateral decompression surgery with a unilateral approach could be an ideal procedure for athletes, but in terms of safety and technical difficulties, patients with fused and nodular types or multi-level and all other forms of OLF cannot undergo this procedure.¹⁶⁾ Furthermore, with the muscle-preserving, spinous process-splitting approach, it is easier to obtain precise anatomical orientation and reflect preoperative planning, such as the extent of decompression, and it can be used with open, microscopic, or endoscopic thoracic surgeries.¹³⁾ In contrast, the disadvantage of this approach is that it may only partially avoid damage to the posterior midline complexes of the thoracic spine and may be more time-consuming than the conventional approach. Since these characteristics also apply to patients who are not athletes, this approach may also be of benefit to all patients.

We have to consider both reducing the symp-

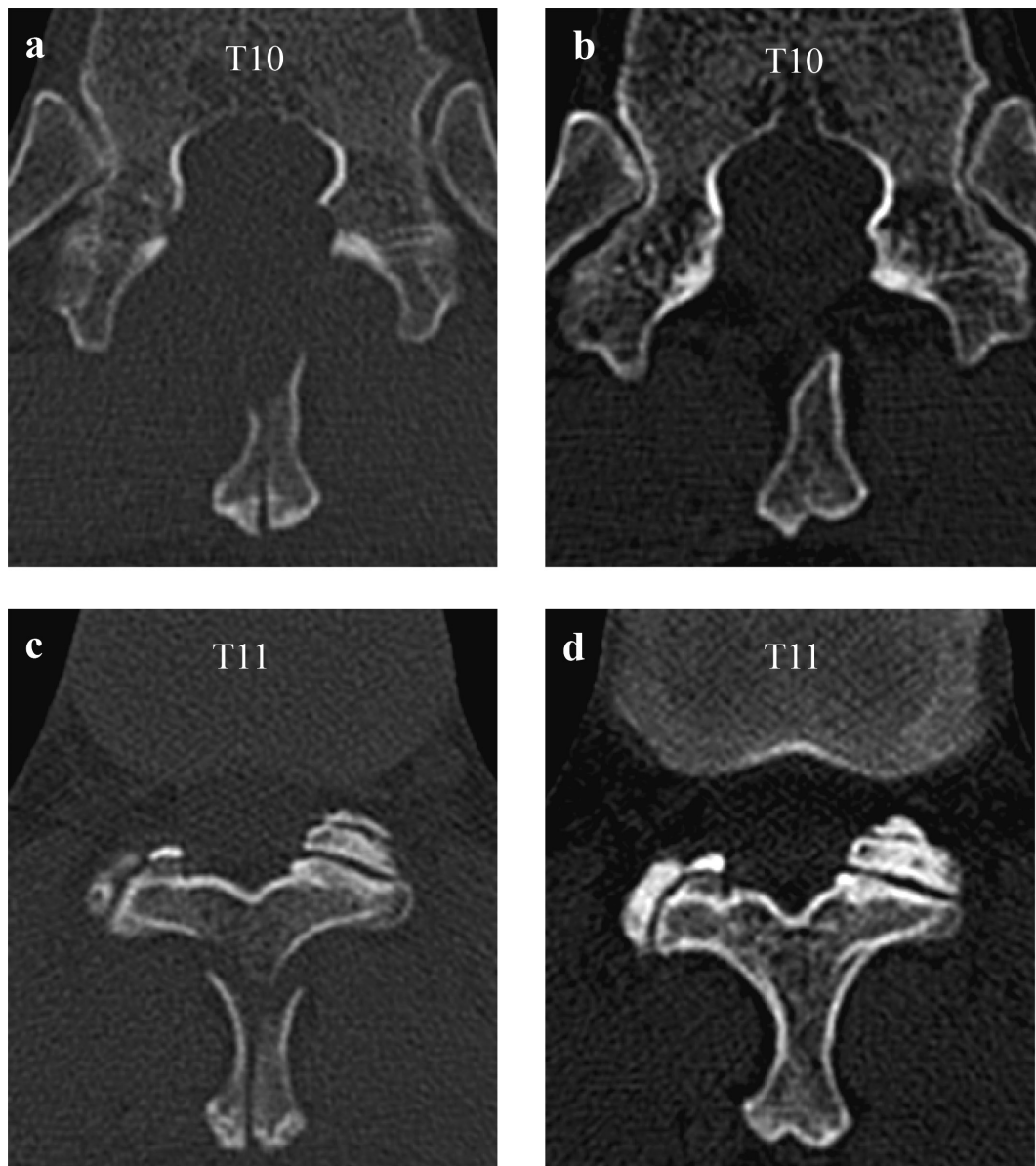


Fig. 4. Axial computed tomography findings of Case 2 at 1 week (a, c) and 1 year after surgery. Split spinous processes of T10 have fused together (b) 1 year after surgery. The spinous process of T11 is fused at the lamina 1 year after surgery (d).

toms and maintaining function after surgery in professional athletes, who have high and often strenuous activity levels. The present patients did not complain of any back pain after return to play, even though both baseball players and cyclists experience a high level of strain on their trunks. The high prevalence of postoperative back pain associated with conventional total laminectomy could be avoided by using this muscle-preserving approach.¹⁰⁾ The spinous process-splitting approach might also preserve the ligamentous structures that function as a mechanical strut in the movement of the spine, thereby allowing sustained postoperative muscle function.^{17,18)} Cases 1 and 3 were high-level baseball

pitchers, and these athletes usually need a wide range of motion of the thoracolumbar spine along with higher back muscle strength.¹⁹⁾ Case 2 was an elite racing cyclist, and this type of athlete needs specific kyphotic thoracic and lumbar spinal posture while cycling with the trunk flexed.²⁰⁾ In all cases, patients successfully returned to play with full strength and range of motion of the trunk. Thus, the less-invasive, spinous process-splitting approach could both eliminate back pain and promote a return to full function. In addition, Cases 1 and 3 started pitching two months after surgery; the pitcher who had conventional laminectomy or laminoplasty in the previous report started pitching six

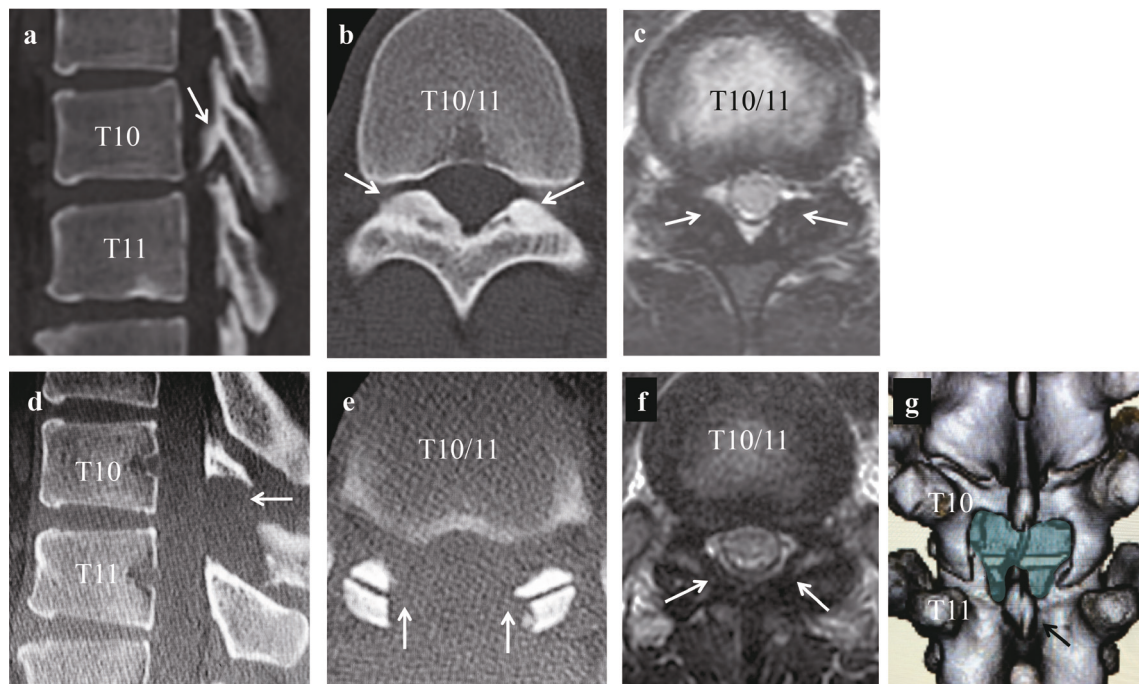


Fig. 5. Pre- and postoperative CT and MRI findings of Case 3. Sagittal CT (a), axial CT (b), and MRI (c) show OLF at T10/11 (arrows). Satisfactory decompression is achieved after the spinous process-splitting approach, with no evidence of muscle damage (d, e, f), and 3D-CT of the thoracic spine shows the area of decompression (blue colored) and the re-attached spinous processes of T10 (arrow) (g).

months after surgery.¹⁵⁾ The severity of preoperative neurological symptoms could strongly affect the timing of return to play, but this approach may also contribute to an earlier return to play.

Additionally, neither case experienced segmental instability nor required a secondary stabilization procedure during the follow-up period. Traditional open laminectomy may be a potential cause of instability because of the removal of bone tissue and destruction of the posterior tension band.^{6,7,21)} Instability can subsequently result in progressive kyphotic deformity and associated neurological deterioration, local recurrence of OLF, or development of OLF at adjacent proximal levels.^{21,22)} Concurrent posterior instrumentation and fusion have been proposed as a strategy to prevent thoracic kyphosis progression from surgical decompression, although this approach remains controversial.²²⁾ Thoracic OLF might increase in size and become exacerbated within a few years in certain athletes, such as professional baseball pitchers, who experience repeated, localized, mechanical stress on the thoracic spine.²³⁾ Although the present cases did not show any local recurrence of OLF or the development of OLF at adjacent levels, long-term follow-up is needed to confirm the results, because every decompressive procedure carries the risk of secondary instability.

Thoracic OLF is primarily observed in middle-aged men, thus rendering young, high-level athletes such as those in their twenties atypical patients. The pathogenesis of OLF is not entirely understood, although mechanical stress is implicated in the hypertrophy and development of OLF.^{15,23,24)} Repetitive and asymmetrical rotatory mechanical stress generated by pitching motions in high-level Asian baseball players, particularly pitchers, may increase the risk of developing symptomatic thoracic OLF regardless of age.^{15,23)} According to previous and present reports, young athletes typically exhibit unilateral symptoms irrespective of the presence of radiculopathy or myelopathy.^{15,23)} This unilateral symptomatology is a feature of thoracic OLF in young athletes and is uncommon in middle-aged patients. Therefore, further epidemiological research is necessary to investigate thoracic OLF in athletes and to gather data on neurological symptoms.

In conclusion, successful outcomes of thoracic OLF cases after posterior decompression with a muscle-preserving, spinous process-splitting approach in professional athletes were described. The spinous process-splitting approach for thoracic spinal diseases provides a sufficient surgical field with minimal damage to the paraspinal muscles for multi-level and all other form types of OLF. As such, this procedure may be recommended for ath-

letes requiring highly active thoracic spine function post-surgery to enable them to continue their athletic pursuits.

Declaration of conflicting interest

The authors declare that there is no conflict of interest regarding the publication of this paper.

Ethics statement

At our institution, case reports do not require ethics review committee approval. The patients described in this paper provided written, informed consent for publication.

Funding

This research received no specific grant from any funding agency in the public, commercial, or not-for-profit sectors.

References

1. Liao CC, Chen TY, Jung SM, *et al.* Surgical Experience with Symptomatic Thoracic Ossification of the Ligamentum Flavum. *J Neurosurg Spine*, **2** : 34-39, 2005.
2. Aizawa T, Sato T, Sasaki H, *et al.* Thoracic Myelopathy Caused by Ossification of the Ligamentum Flavum : Clinical Features and Surgical Results in the Japanese Population. *J Neurosurg Spine*, **5** : 514-519, 2006.
3. Sun X, Sun C, Liu X, *et al.* The Frequency and Treatment of Dural Tears and Cerebrospinal Fluid Leakage in 266 Patients with Thoracic Myelopathy Caused by Ossification of the Ligamentum Flavum. *Spine (Phila Pa 1976)*, **37** : E702-707, 2012.
4. Yu S, Wu D, Li F, *et al.* Surgical Results and Prognostic Factors for Thoracic Myelopathy Caused by Ossification of Ligamentum Flavum : Posterior Surgery By Laminectomy. *Acta Neurochir (Wien)*, **155** : 1169-1177, 2013.
5. Macnab I, Cuthbert H, Godfrey CM. The Incidence of Denervation of the Sacrospinalis Muscles Following Spinal Surgery. *Spine*, **2** : 294-298, 1977.
6. Yasuoka S, Peterson HA, MacCarty CS. Incidence of Spinal Column Deformity after Multilevel Laminectomy in Children and Adults. *J Neurosurg*, **57** : 441-445, 1982.
7. Papagelopoulos PJ, Peterson HA, Ebersold MJ, *et al.* Spinal Column Deformity and Instability after Lumbar or Thoracolumbar Laminectomy for Intraspinal Tumors in Children and Young Adults. *Spine (Phila Pa 1976)*, **22** : 442-451, 1997.
8. Watanabe K, Hosoya T, Shiraishi T, *et al.* Lumbar Spinous Process-Splitting Laminectomy for Lumbar Canal Stenosis. *J Neurosurg Spine*, **3** : 405-408, 2005.
9. Kim K, Isu T, Sugawara A, *et al.* Comparison of the Effect of 3 Different Approaches to the Lumbar Spinal Canal on Postoperative Paraspinal Muscle Damage. *Surg Neurol*, **69** : 109-113, 2008.
10. Watanabe K, Matsumoto M, Ikegami T, *et al.* Reduced Postoperative Wound Pain after Lumbar Spinous Process-Splitting Laminectomy for Lumbar Canal Stenosis : A Randomized Controlled Study. *J Neurosurg Spine*, **14** : 51-58, 2011.
11. Uehara M, Takahashi J, Hashidate H, *et al.* Comparison of Spinous Process-Splitting Laminectomy versus Conventional Laminectomy for Lumbar Spinal Stenosis. *Asian Spine J*, **8** : 768-776, 2014.
12. Nomura H, Yanagisawa Y, Arima J, *et al.* Clinical Outcome of Microscopic Lumbar Spinous Process-Splitting Laminectomy. *J Neurosurg Spine*, **21** : 187-194, 2014.
13. Ikuta K, Tarukado K, Senba H, *et al.* Decompression procedure using a microendoscopic technique for thoracic myelopathy caused by ossification of the ligamentum flavum. *Minim Invasive Neurosurg*, **54** : 271-273, 2012.
14. Gagnier JJ, Kienle G, Altman DG, Moher D, Sox H, Riley D ; CARE Group. The CARE guidelines : consensus-based clinical case reporting guideline development. *Headache*, **53** : 1541-1547, 2013.
15. Kaneyama S, Doita M, Nishida K, *et al.* Thoracic Myelopathy Due to Ossification of the Yellow Ligament in Young Baseball Pitchers. *J Spinal Disord Tech*, **21** : 68-71, 2008.
16. Li X, An B, Gao H, *et al.* Surgical Results and Prognostic Factors Following Percutaneous Full Endoscopic Posterior Decompression for Thoracic Myelopathy Caused by Ossification of the Ligamentum Flavum. *Sci Rep*, **10** : 1305, 2020. doi : 10.1038/s41598-020-58198-x.
17. Oda I, Abumi K, Lü D, *et al.* Biomechanical Role of the Posterior Elements, Costovertebral Joints, and Rib Cage in the Stability of the Thoracic Spine. *Spine (Phila Pa 1976)*, **21** : 1423-1429, 1996.
18. Cho DY, Lin HL, Lee WY, *et al.* Split-spinous Process Laminotomy and Discectomy for Degenerative Lumbar Spinal Stenosis : A Preliminary Report. *J Neurosurg Spine*, **6** : 229-239, 2007.
19. Laudner K, Lynall R, Williams JG, *et al.* Thoracolumbar Range of Motion in Baseball Pitchers and

- Position Players. *Int J Sports Phys Ther*, **8** : 777–783, 2013.
20. Muyor JM, López-Miñarro PA, Alacid F. Spinal Posture of Thoracic and Lumbar Spine and Pelvic Tilt in Highly Trained Cyclists. *J Sports Sci Med*, **10** : 355–361, 2011.
21. Okada K, Oka S, Tohge K, *et al.* Thoracic Myelopathy Caused by Ossification of the Ligamentum Flavum. Clinicopathologic Study and Surgical Treatment. *Spine (Phila Pa 1976)*, **16** : 280–287, 1991.
22. Wang T, Yin C, Wang D, *et al.* Surgical Technique for Decompression of Severe Thoracic Myelopathy due to Tuberous Ossification of Ligamentum Flavum. *Clin Spine Surg*, **30** : E7–E12, 2017.
23. Kato K, Otoshi K, Hakoziaki M, Konno SI. Progressive enlargement of thoracic ossification of the ligamentum flavum in professional baseball pitchers : a report of two cases. *J Int Med Res*, **49** : 3000605211059465, 2021.
24. Otani K, Aihara T, Tanaka A, Shibasaki K. Ossification of the ligamentum flavum of the thoracic spine in adult kyphosis. *Int Orthop*, **10** : 135–139, 1986.