Title	A case of transgastric gallbladder puncture as a complication during endoscopic ultrasound-guided drainage of a pancreatic pseudocyst
Author(s)	Hikichi, Takuto; Irisawa, Atsushi; Takagi, Tadayuki; Shibukawa, Goro; Wakatsuki, Takeru; Imamura, Hidemichi; Takahashi, Yuta; Sato, Ai; Sato, Masaki; Oyama, Hitoshi; Sato, Naoto; Yamamoto, Go; Mokonuma, Tatsuyuki; Obara, Katsutoshi; Ohira, Hiromasa
Citation	Fukushima Journal of Medical Science. 53(1): 11-18
Issue Date	2007-06
URL	http://ir.fmu.ac.jp/dspace/handle/123456789/203
Rights	© 2007 The Fukushima Society of Medical Science
DOI	10.5387/fms.53.11
Text Version	publisher

Fukushima J. Med. Sci.,
Vol. 53, No. 1, 2007

[**Case Report**]

A CASE OF TRANSGASTRIC GALLBLADDER PUNCTURE AS A COMPLICATION DURING ENDOSCOPIC ULTRASOUND-GUIDED DRAINAGE OF A PANCREATIC PSEUDOCYST

TAKUTO HIKICHI[1], ATSUSHI IRISAWA[2], TADAYUKI TAKAGI[2], GORO SHIBUKAWA[2], TAKERU WAKATSUKI[2], HIDEMICHI IMAMURA[2], YUTA TAKAHASHI[2], AI SATO[2], MASAKI SATO[2], HITOSHI OYAMA[2], NAOTO SATO[2], GO YAMAMOTO[2], TATSUYUKI MOKONUMA[2], KATSUTOSHI OBARA[1] and HIROMASA OHIRA[2]

[1]*Department of Endoscopy, Fukushima Medical University Hospital, 960-1295, Japan*
[2]*Department of Internal Medicine II, Fukushima Medical University School of Medicine, 960-1295, Japan*

(Received July 18, 2006, accepted November 13, 2006)

Abstract: A 43-year-old man, a regular drinker, developed a pseudocyst in the pancreatic tail as a result of acutely worsening chronic pancreatitis. Because the pseudocyst, 10 cm in diameter, did not disappear despite conservative treatment, an internal drainage stent was placed transgastrically under endoscopic ultrasound (EUS) guidance. However, cyst infection occurred, and EUS-guided drainage was performed, when the gallbladder was punctured inadvertently. Immediately a nasocystic drain was placed in the gallbladder. Owing to this timely measure, only mild and localized peritonitis developed. Conservative treatment with fasting and an antibiotic was administered, and peritonitis subsided quickly. On the same day, another nasocystic drain was placed for the pancreatic pseudocyst, and it disappeared. As far as we know, this is the first case in which gallbladder puncture was inadvertently performed during EUS-guided drainage of a pancreatic pseudocyst.

Key words: gallbladder puncture, pancreatic pseudocyst, EUS-FNA, EUS-guided drainage, complication

引地拓人，入澤篤志，高木忠之，澁川悟朗，若槻　尊，今村秀道，髙橋裕太，佐藤　愛，佐藤匡記，大山　仁，佐藤直人，山本　豪，茂古沼達之，小原勝敏，大平弘正
Correspondence to: Takuto Hikichi, Department of Endoscopy, Fukushima Medical University Hospital, Fukushima City 960-1295, Japan.
E-mail: takuto@fmu.ac.jp

INTRODUCTION

A pancreatic pseudocyst is a nonepithelial cyst formed after acute deterioration of acute and chronic pancreatitis, and injury to and resection of the pancreas. It often resolves spontaneously with conservative treatment. If it does not, complications, such as cyst infection and bleeding and rupture of the digestive tract, may ensue, threatening life. Therefore, in the past it has been removed surgically or drained percutaneously. Recently, with the advances in endoscopic therapy, endoscopic transmural drainage has become possible[1-3]. However, the problem with this method using a conventional endoscope was that puncture under direct vision had to be blind puncture, causing complications, such as bleeding and digestive tract perforation. In recent years, endoscopic ultrasound (EUS)-guided transmural drainage has been developed, and its safety and usefulness are estimated to be superior to those of the conventional method[4-12].

Complications of EUS-guided pancreatic pseudocyst drainage are divided into two groups: early complications associated with surgical techniques, and late complications occurring in the course of recovery. Common early complications include bleeding and perforation, and late complications are mostly cyst infections due to obstruction of a drainage tube[4]. Kruger *et al.*[5] reported that no early complications occurred in the 35 patients they had seen, and Giovannini *et al.*[6] reported that only 1 (2.9%) of their 35 patients developed mild pneumoperitoneum, which resolved quickly. Vosoghi *et al.*[7], however, reported that in 1 (7%) of their 14 patients, bleeding occurred 2 days after the procedure, requiring surgery. Thus, in performing EUS-guided drainage, although it is regarded as safer than the conventional method, the knowledge of how to prevent and how to cope with complications is important. We inadvertently injured the gallbladder of a patient with pancreatic pseudocyst during EUS-guided drainage. We report here how we coped with it and how it could have been prevented.

CASE REPORT

A 43-year-old man, a regular drinker, presented to our hospital complaining of an abdominal pain in April 2001. Because a CT scan showed a 10-cm pseudocyst and bleeding into the cyst in the pancreatic tail, he was hospitalized and underwent conservative treatment for 56 days. However, the pseudocyst did not reduce, and so he was rehospitalized to undergo EUS-guided drainage in December 2001. On admission, although there was no abdominal pain, and a blood test showed no inflammation reaction or elevated tumor marker, CT scan showed a 10-cm pseudocyst in the pancreatic tail (Fig. 1); therefore, EUS-guided cystogastrostomy was performed on the fifth hospital day. A curved linear-array echo endoscope (FG-36UX; Pentax Corp., Tokyo, Japan) was inserted into the stomach, and an

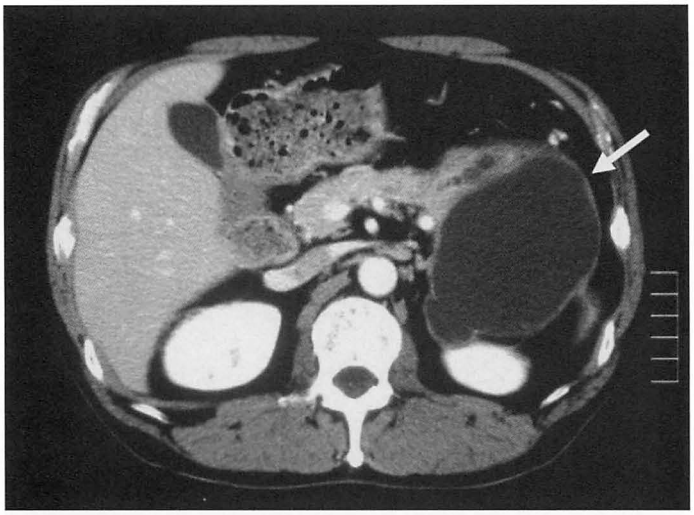

Fig. 1. Contrast-enhanced abdominal CT image. A dilated pancreatic duct and a 10 cm diameter cyst were seen in the pancreatic tail (arrow). The cyst was considered a pseudocyst because there was no evidence of malignancies, such as mural nodules at the cyst wall or a tumor in the pancreas.

ultrasound imaging device attached to it (EUB-6000 ; Hitachi Ltd., Tokyo, Japan) depicted a pancreatic pseudocyst as a uniform granular echo pattern (Fig. 2). After the pseudocyst was punctured with a 19G needle (ECHOTIP ; Wilson-Cook Medical Inc., Osaka, Japan) without electricity, the stomach wall (upper gastric body) and cyst wall of the puncture site were stretched with a dilator, and a Zimmon Biliary Stent 7Fr, 4 cm (Wilson-Cook Medical Inc., Osaka, Japan) was placed (Fig. 3). However, the pseudocyst did not resolve ; the temperature and inflammation reaction increased, suggesting cyst infection due to stent clogging. The patient's condition remained unimproved with conservative treatment, and on the 34th hospital day, EUS-guided nasocystic drainage (ENCD) of the pseudocyst was performed transgastrically. Before puncture, transgastric EUS had confirmed a cyst-like structure whose interior was visualized as two layers, i.e., an echoic and anechoic areas (Fig. 4). This cyst-like structure was punctured under EUS guidance, and a 5 Fr endoscopic nasobiliary drainage (ENBD) tube (Flexima ; Boston Scientific Corp., Tokyo, Japan) was placed. Fluoroscopic observation of the patient in the supine position revealed the tube in the right side of the abdomen, from which it was evident that the gallbladder had been punctured, not the pancreatic pseudocyst (Fig. 5). Careful review showed that the puncture site was in the lower gastric body when it should have been in the upper gastric body. The tube was left in the gallbladder so that bile would not leak into the abdominal cavity causing bile peritonitis. The pseudocyst was drained by reinserting the EUS and placing a 5Fr ENBD tube (ENBD-5 ; Wilson-Cook Medical Inc., Osaka, Japan) in the cyst. The fluid was milky white.

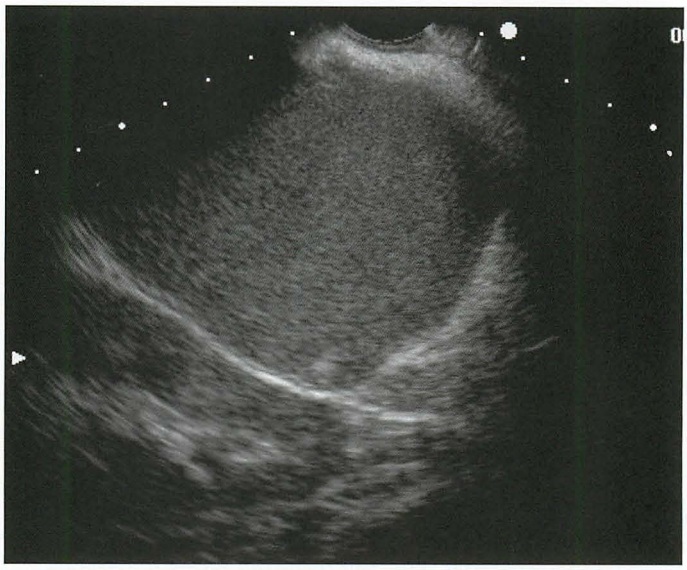

Fig. 2. EUS image. The pancreatic pseudocyst showed no wall thickening and had a granular echo pattern with relatively uniform inner echo density.

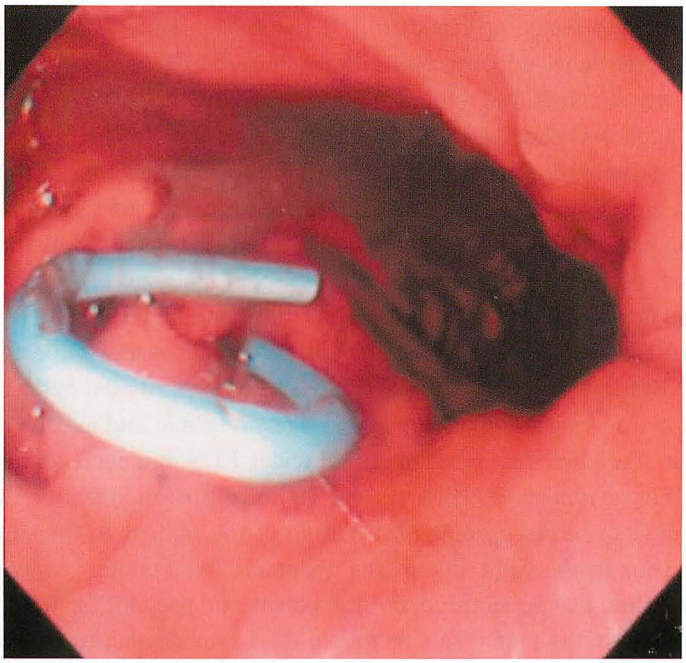

Fig. 3. Endoscopic image. A stent was inserted into the pancreatic pseudocyst from the posterior wall of the greater curvature of the stomach.

Fig. 4. EUS image. A cyst-like structure with the interior visualized as two layers.

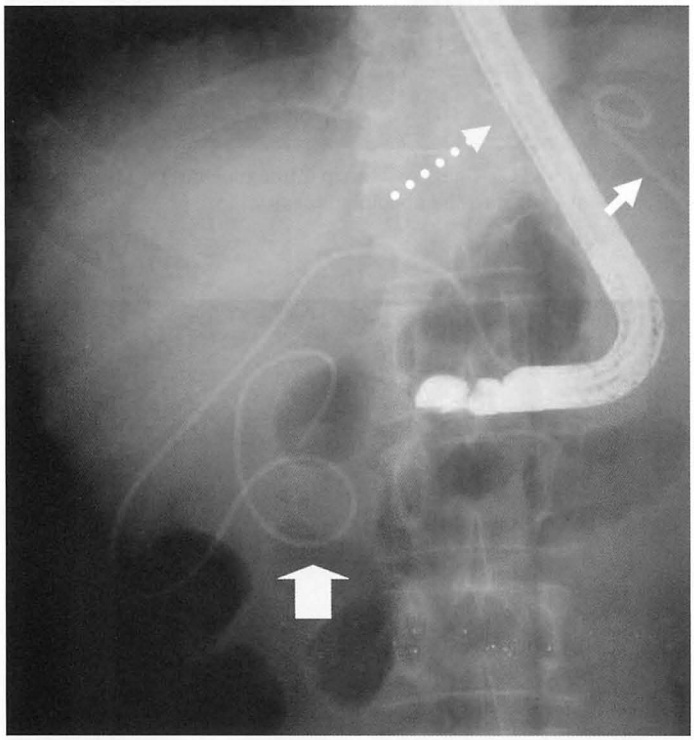

Fig. 5. Plain abdominal roentgenogram in the supine position. The nasocystic drain (broad arrow) is located away from the stent (arrow) placed in the pancreatic pseudocyst. The dotted arrow indicates the ultrasonic endoscope used.

Abdominal roentgenogram taken on the following day showed that the tip of the tube in the gallbladder had moved slightly. A CT scan performed 2 days later confirmed that it had slipped out of the gallbladder into the abdominal cavity (Fig. 6). Three days later, that part of the tube that had slipped out of the gallbladder was removed under fluoroscopic observation, taking care that the rest of the pseudocyst did not fall out. To prevent leakage of gastric juice from the puncture

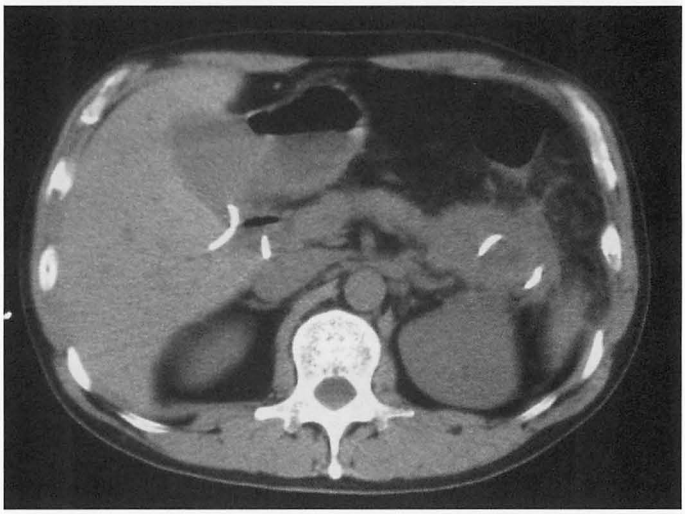

Fig. 6. Plain abdominal CT image. The tip of the tube inserted into the gallbladder was slipped out of it into the abdominal cavity.

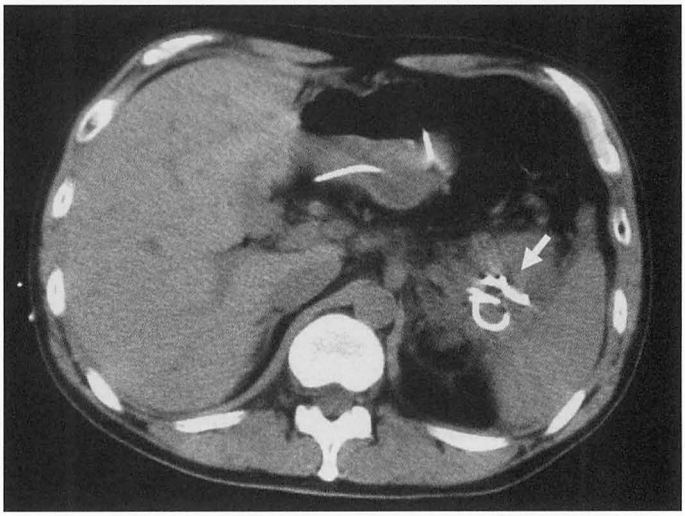

Fig. 7. Plain abdominal CT image. The pancreatic pseudocyst subsided considerably, and inside it was the tube that had been placed (arrow).

site into the abdominal cavity, a tube was inserted into the stomach through the nose. Continuous administration of antibiotics during fasting controlled the inflammatory reaction. A CT scan performed 7 days later showed that the pseudocyst subsided considerably (Fig. 7). A restricted diet was started on the 48th hospital day, 14 days after the first drainage, and the ENCD tube in the pseudocyst was removed on the 54th hospital day, 19 days after the first drainage. Even after the tube was removed, the inflammatory reaction remained controlled, and a CT scan showed no infection or enlargement of the cyst, and so the patient was released from the hospital on the 65th hospital day.

DISCUSSION

Grimm *et al.*[8] first reported EUS-guided transmural drainage of pancreatic pseudocysts in 1992. Before then, pseudocysts had been punctured and drained under direct vision using a regular endoscope. The traditional method, however, involved blind puncture and was inapplicable to patients without a luminal bulge in the digestive tract[9]. Furthermore, there were risks of bleeding and perforation as complications. The new technique, using the EUS image as a guide, is safe as many investigators report[4-12] and permits puncture in real time. Vosoghi *et al.*[7], who reviewed the complication rates of various treatments, reported the highest safety of EUS-guided transmural drainage as follows: the complication rates of surgical treatment, percutaneous drainage, transpapillary drainage, endoscopic puncture drainage under direct vision and EUS-guided puncture drainage were 28%, 18%, 12%, 15% and 1.5%, respectively.

Thus, EUS-guided transmural drainage is the first-choice treatment for patients with pancreatic pseudocyst, if they can tolerate the endoscopic procedure. However, although its complication rate is lower than that of any other treatment, those who perform this procedure should have a thorough knowledge of the complications that can arise from it. The early complications associated with this technique include bleeding, perforation and intraperitoneal emphysema[5,7,10-12]. Binmoeller *et al.*[3] reported a case (4.1%) of inadvertent puncture of the gallbladder during the attempted puncture of a pancreatic pseudocyst under direct vision. In their case, bile leaked, and a surgical operation was required. Fortunately, in our case, no surgery was needed. After inadvertent puncture of the gallbladder and subsequent stretch of the puncture site, a small amount of bile leaked into the abdominal cavity. However, an ENCD tube reduced the pressure in the gallbladder, eventually stopping the bile leak and eliminating the need for surgery. The factors considered to have led to inadvertent puncture of the gallbladder in this case are: 1) The gallbladder that enlarged because of long fasting was unusually visible from the stomach. 2) Because there was a large amount of debris in the gallbladder, it was mistaken for an infected pancreatic pseudocyst (pancreatic abscess). 3) Because the entire procedure was performed with the patient in the left lateral decubitus position, the

pancreatic pseudocyst and gallbladder overlapped on the x-ray fluoroscopic image. To prevent similar complications, it is essential to accurately identify a pancreatic pseudocyst on EUS images and carefully choose a puncture site in the stomach on endoscopic images. Moreover, the pancreatic pseudocyst should also be confirmed under X-ray fluoroscopy with the patient's position changed from left decubitus, taken when the endoscope is inserted, to supine.

In conclusion, EUS-guided transmural drainage of pancreatic pseudocysts is safer than the blind puncture technique using a regular endoscope. However, endoscopists should realize again that because many different objects surrounding the digestive tract are visible, the target can be mistaken, leading to a complication. Those who perform this procedure need to fully understand the possibility of a complication such as ours, and keeping in mind how to cope with it, they should strive for accuracy in diagnosis and every aspect of this procedure.

REFERENCES

1. Cremer M, Deviere J, Engelholm L. Endoscopic management of cysts and pseudocysts in chronic pancreatitis: long-term follow up after 7 years of experience. Gastrointest Endosc, **35**: 1-9, 1989.
2. Sahel J, Bastid C, Pellat B, Schurgeres F, Sarles H. Endoscopic cystogastrostomy of cysts of chronic calcifying pancreatitis: a report of 20 cases. Pancreas, **2**: 447-453, 1987.
3. Binmoeller KF, Seifert H, Walter A, Soehendra N. Transpapillary and transmural drainage of pancreatic pseudocysts. Gastrointest Endosc, **42**: 219-224, 1995.
4. Fockens P. EUS in drainage of pancreatic pseudocysts. Gastrointestinal Endosc, **56**(Suppl): S93-97, 2002.
5. Kruger M, Schneider AS, Manns MP, Meier PN. Endoscopic management of pancreatic pseudocysts or abscesses after an EUS-guided 1-step procedure for initial access. Gastrointestinal Endosc, **63**: 409-416, 2002.
6. Giovannini M, Pesenti C, Rolland AL, Moutardier V, Delpero JR. Endoscopic ultrasound-guided drainage of pancreatic pseudocysts or pancreatic abscess using a therapeutic echo endoscope. Endoscopy, **33**: 473-477, 2001.
7. Vosoghi M, Sial S, Garrett B, Feng J, Lee T, Stabile BE, Eysselein VE. EUS-guided pancreatic pseudocyst drainage: review and experience at Harbor-UCLA Medical Center. Med Gen Med, **4**: 2, 2002.
8. Grimm H, Binmoeller KF, Soehendra M. Endosonography-guided drainage of a pancreatic pseudocysts. Gastrointest Endosc, **38**: 170-171, 1992.
9. ASGE guideline: the role of endoscopy in the diagnosis and the management of cystic lesions and inflammatory fluid collections of the pancreas. Gastrointest Endosc, **61**: 363-370, 2005.
10. Binmoeller KF, Soehendra N. Endoscopic ultrasonography in the diagnosis and treatment of pancreatic pseudocysts. Gastrointest Endosc Clin N Am, **5**: 805-816, 1995.
11. Antillon MR, Shah RJ, Stiegmann G, Chen YK. Single-step EUS-guided transmural drainage of simple and complicated pancreatic pseudocysts. Gastrointest Endosc, **63**: 797-803, 2006.
12. Giovannini M, Binmoeller K, Seifert H. Endoscopic ultrasound-guided cystogastrostomy. Endoscopy, **35**: 239-245, 2003.