



Title	A case of polyarteritis nodosa limited to lower legs with a high titer of MPO-ANCA under precedence of idiopathic pulmonary fibrosis
Author(s)	Sugisaki, Kota; Takeda, Isao; Kanno, Takashi; Oguchi, Yoshihito; Kasukawa, Reiji
Citation	Fukushima Journal of Medical Science. 49(2): 141-148
Issue Date	2003-12
URL	http://ir.fmu.ac.jp/dspace/handle/123456789/145
Rights	© 2003 The Fukushima Society of Medical Science
DOI	10.5387/fms.49.141
Text Version	publisher

This document is downloaded at: 2024-04-25T22:29:13Z

**A CASE OF POLYARTERITIS NODOSA LIMITED TO LOWER LEGS
WITH A HIGH TITER OF MPO-ANCA UNDER PRECEDENCE
OF IDIOPATHIC PULMONARY FIBROSIS**

KOTA SUGISAKI¹⁾, ISAO TAKEDA¹⁾, TAKASHI KANNO¹⁾,
YOSHIHITO OGUCHI²⁾ and REIJI KASUKAWA¹⁾

¹⁾*Division of Rheumatology, Ohta Nishinouchi Hospital, Koriyama*

²⁾*Oguchi Clinic, Koriyama*

(Received May 16, 2003, accepted May 29, 2003)

Abstract: A 58-year-old man with a 15-year history of idiopathic pulmonary fibrosis was hospitalized for rapid progression of muscle weakness to bilateral foot drop. Although laboratory data revealed high titers of myeloperoxidase anti-neutrophil cytoplasmic antibody (489 EU), the patient was diagnosed as polyarteritis nodosa limited to the lower portions of the legs. Despite of the treatment with large doses of corticosteroids and cyclosporin A, his symptoms barely improved during the following two months.

Key words: vasculitic neuropathy, muscle weakness, cyclosporin A

INTRODUCTION

Polyarteritis nodosa (PAN) represents a heterogeneous group of vasculitides that have recently been subclassified into classical PAN and microscopic polyangiitis (MPA). In classical PAN, medium- to small-sized vessels in various organs are damaged, while in MPA, small vessels impairment predominates. Renal artery involvement without glomerular damage is often found in PAN, while a high prevalence of glomerulonephritis is observed in MPA.

Anti-neutrophil cytoplasmic antibody for myeloperoxidase (MPO-ANCA) reportedly represents a specific serological marker for small vessel vasculitis such as MPA and Churg-Strauss syndrome (CSS). However, some cases of classical PAN with low titers of MPO-ANCA have recently been reported. These reports indicate that the existence of MPO-ANCA does not always rule out a diagnosis of classical PAN. Careful clinical examination for vascular lesions is indispensable for

杉崎康太, 武田 功, 菅野 孝, 大口義人, 粕川禮司

Correspondence to: Kota Sugisaki, Department of Internal Medicine II, Fukushima Medical University School of Medicine, Fukushima City 960-1295, Japan.

diagnosing the conditions of patients with MPO-ANCA.

The present report describes a case of classical PAN limited to the lower portions of the legs. The patient had an exceedingly high titer of MPO-ANCA and a 15-year history of idiopathic pulmonary fibrosis (IPF).

CASE REPORT

A 58-year-old man noticed livedo reticularis with mild pain in the lower portions of his legs on May 28, 2002, and was examined at Oguchi Clinic. Because of no drug history, no symptom of infection and collagen disease, he had been diagnosed as IPF 15 years before. However, the patient had received no medical treatments for IPF as he lacked respiratory symptoms. He was not a smoker and never suffered from bronchial asthma. Laboratory data for the patient were as follows: C-reactive protein (CRP), 11.69 mg/dl (normal, less than 0.2 mg/dl); creatinine, 0.9 mg/dl (normal, less than 1.0 mg/dl); positive titer of rheumatoid factor, 105 IU/ml (normal, less than 20 IU/ml); positive titer of MPO-ANCA, 227 EU (normal, less than 10 EU). Neither proteinase-3 anti-neutrophil cytoplasmic antibody (PR3-ANCA) nor anti-nuclear antibody (ANA) was detected. Urinalysis revealed no proteinuria or microscopic hematuria. Systemic vasculitis and vasculitic neuropathy were suspected, and 30 mg/day of prednisolone was administered. Livedo reticularis and leg pain improved slightly. However, muscle weakness in the lower portions of the legs, particularly in bilateral tibialis anterior muscles, appeared suddenly on June 1, 2002, and rapidly progressed. The patient was referred and admitted to the Rheumatology Unit of Ohta Nishinouchi Hospital on June 3, 2002.

On admission, livedo reticularis in the lower sections of both legs (Fig. 1) and bilateral foot drop were noted. The patient's body temperature was 36.0°C, and no signs of Raynaud's phenomenon or arthritis were observed. Blood pressure was

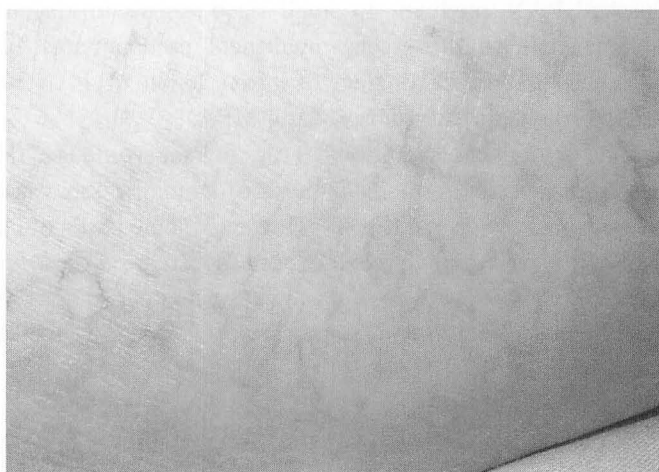

Fig. 1. Livedo reticularis in the lower portion of the right leg.

150/82 mmHg. Heart sounds were clear with a regular sinus rhythm, and the pulse rate was 104 beats/min. Weak fine crepitations without any wheezing were audible in both lung fields. No bruit was audible in the neck or abdomen. Mild edema was observed in both feet, while both dorsal pedis arteries were easily palpable. The patient reported mild stinging pain in the lower sections of his legs, especially in the soles. Manual muscle tests revealed severe muscle weakness equivalent to grade 0 or 1 in both tibialis anterior muscles. Due to significant muscle weakness in the lower sections of the legs, the patient was unable to stand unaided. Deep tendon reflex in the upper extremities and patellar tendon reflex were normal. However, the Achilles tendon reflex was absent bilaterally. Superficial sensations, such as thermal and touch senses, were slightly disturbed, while deep sensory disturbance was not observed.

Laboratory data on admission were as follows: erythrocyte sedimentation rate, 45 mm/h (normal, less than 15 mm/h); CRP, 2.3 mg/dl; white blood cells, 17,500/mm³ (normal, 3,000–10,000/mm³); Neutrophils, 78% (normal, (27–69%)); Eosinophils, 2% (normal, less than 10%); Lymphocytes, 14% (normal, 18–59%); hemoglobin, 14.3 g/dl (normal, 13.4–17.5 g/dl); platelets, 50.1×10^4 /mm³ (normal, 12.5 – 37.0×10^4 /mm³); total protein, 7.6 g/dl (normal, 6.5–8.3 g/dl); albumin, 3.9 g/dl (normal, 4.0–5.2 g/dl); aspartate aminotransferase, 38 IU/l (normal, 5–35 IU/l); alanine aminotransferase, 62 IU/l (normal, 5–40 IU/l); lactate dehydrogenase, 220 U/ml (normal, 110–220 U/ml); blood urea nitrogen, 14.2 mg/dl (normal, 8–20 mg/dl); creatinine, 0.68 mg/dl; KL-6, 1,310 IU/ml (normal, less than 500 IU/ml); 24-h creatinine clearance, 185.8 l/day. ANA, anti-DNA, anti-RNP, anti-Sm, anti-Ro, anti-La and anti-Scl-70 antibodies were not detected using commercial ELISA kits. Levels of C₃, C₄ and hemolytic complement (CH₅₀) were normal. The immune complex level measured by the C1q binding method was 3.5 µg/ml (normal, less than 2.9 µg/ml). There was an exceedingly high titer of MPO-ANCA (489 EU), while PR3-ANCA was not detected. No evidence of chronic infection with hepatitis B or C virus was observed. Urinalysis revealed no abnormal sedimentation or urinary cast. Chest X-ray and computed tomography of the chest revealed diffuse interstitial fibrosis throughout both lung fields with no alveolar hemorrhage or pleural effusion (Fig. 2). Both pulmonary function test and arterial blood gas analysis showed no abnormality. An immunological fecal occult blood test was negative.

The clinical course of this case is shown in Fig. 3. Following the 1990 American Collage of Rheumatology criteria, the patient's condition was diagnosed as classical PAN. The diagnosis was based on livedo reticularis, weakness of muscles and multiple mononeuropathies, although histological examination of arteries was not performed. To prevent additional progression of motor and sensory nerve disturbances, methylprednisolone drip infusion therapy at a dosage of 500 mg/day for 3 days was started on June 3, 2002. The infusion therapy was followed by administration of prednisolone at a dosage of 60 mg/day. The patient's livedo reticularis was subsequently ameliorated. However, no remarkable improvements in the sensory

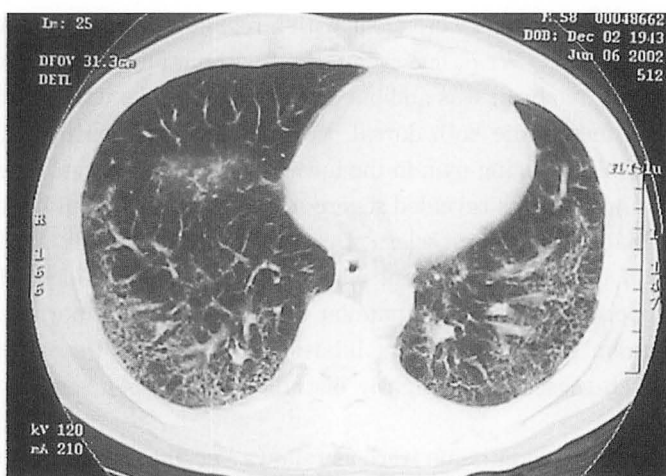


Fig. 2. Computed tomography of the chest taken on June 25, 2002, showing diffusely increased intensity of interstitial lung figures with partial honeycombing in bilateral back fields. No alveolar hemorrhage or pleural effusion was found.

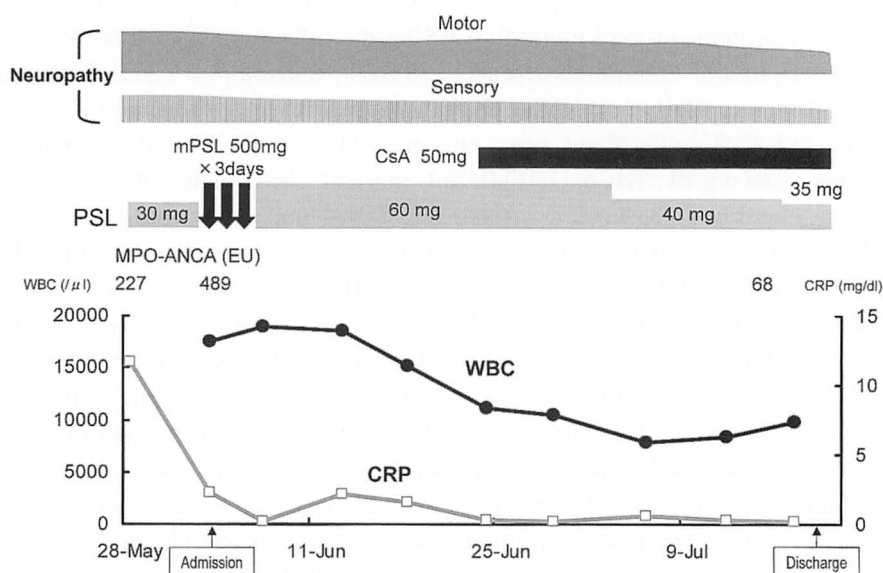


Fig. 3. Clinical course of the patient. White blood cell (WBC) counts and C-reactive protein (CRP) levels are presented with the therapeutic regimen and severity of motor and sensory neuropathy.

PSL, prednisolone; mPSL, methylprednisolone; CsA, cyclosporin A.

disturbance or foot drop were observed. Motor nerve conduction studies of bilateral peroneal and tibial nerves and sensory nerve conduction studies of bilateral sural nerves were performed on June 25. Action potentials were absent in all examined nerves (Fig. 4). These results suggested the existence of axonal degeneration that was probably caused by peri-neuronal vasculitides. No malignancy was

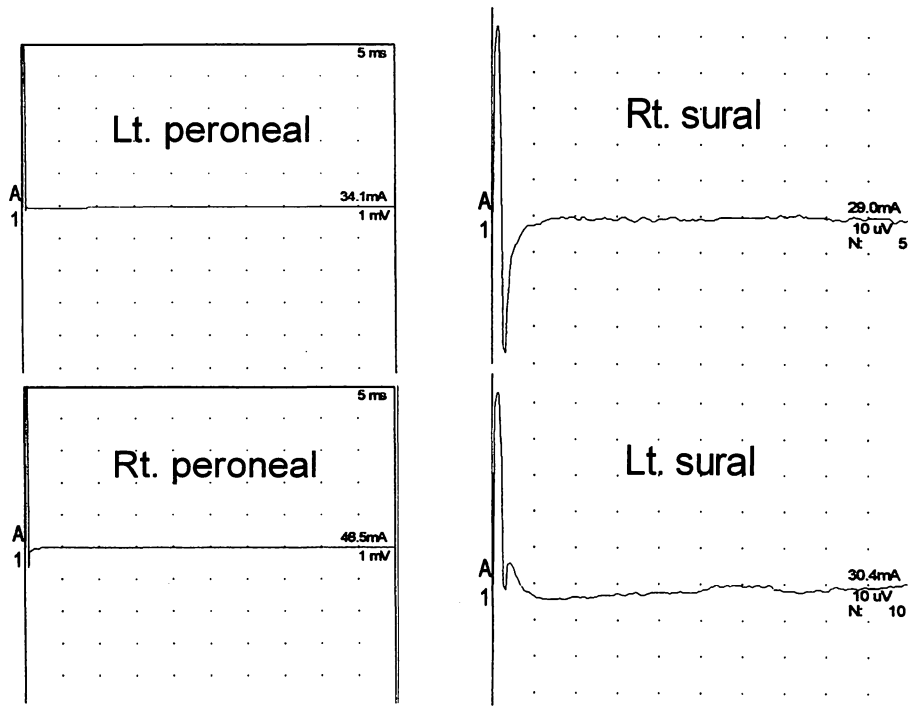


Fig. 4 [a]

Fig. 4 [b]

Fig. 4. Nerve conduction studies. Absence of action potential was observed in the bilateral peroneal motor nerves [a] and the bilateral sural sensory nerves [b].

found by routine gastrointestinal endoscopy, chest computed tomography and abdominal ultrasonography.

Because of the complication of severe IPF and the prevention of the rapid progression of the interstitial pulmonary lesion, treatment with cyclosporin A (CsA) at a dosage of 50 mg/day was commenced on July 5. Thereafter, the levels of CRP decreased to 0.2 mg/dl, and the titer of MPO-ANCA decreased to 68 EU on July 18. Blood CsA trough-level ranged between 45-213 ng/ml.

DISCUSSION

MPO-ANCA is widely recognized as a specific serological marker for small vessel vasculitis such as MPA¹⁾ and CSS²⁾. It has been reported that MPO-ANCA is found in 50-80% of patients with MPA and 20% of patients with classical PAN³⁾, and some cases of classical PAN with low titers of MPO-ANCA have been recently reported⁴⁾⁻⁶⁾. These reports indicate that the existence of MPO-ANCA does not always rule out the diagnosis of classical PAN.

Nephropathy, especially glomerulonephritis, is often found in patients with MPA, but it is rarely seen in patients with classical PAN^{1),7)}. Our patient had no

renal dysfunction or abnormal urinary findings. Alveolar hemorrhage is the most common and fatal complication of MPA⁸⁾⁻¹⁰⁾, but alveolar hemorrhage rarely occurs in patients with classical PAN. Our patient did not develop alveolar hemorrhage.

Peripheral neuropathy, including multiple mononeuropathies, is a common complication of systemic vasculitis. Approximately 60% of classical PAN and MPA patients develop multiple mononeuropathies⁷⁾. Moreover, motor neuron disturbance is often seen in patients with classical PAN^{11),12)}, while sensory disturbance is more common in patients with MPA¹³⁾. Severe motor neuropathies, such as drop foot, are rarely seen in patients with MPA. In our patient, motor neuron-dominant neuropathy, which was demonstrated by drop foot, was observed with mild sensory nerve disturbance. This strongly suggested the presence of PAN.

Despite a high titer of MPO-ANCA, the diagnosis of classical PAN was made. The diagnosis was based on the lack of both nephritis and alveolar hemorrhage and the presence of motor neuron-dominant neuropathy, calf muscle weakness and livedo reticularis. We did not find any signs of vasculitis in other parts of the body. It is plausible that the patient did not have high fever or weight loss, which are often found in cases of classical PAN, because this was a limited form of PAN that was quickly and intensively treated.

Pulmonary fibrosis is a rare complication of classical PAN and MPA. Some cases of MPA accompanied by IPF have been recently reported^{14),15)}. Interestingly, in most of these cases, IPF preceded the vasculitis. These reports indicate that IPF may affect the pathogenesis of MPA. Various kinds of autoantibodies, such as ANA, have been detected in patients with IPF^{16),17)}. Moreover, a predominantly T-helper-2 cytokine profile, which is indispensable for autoantibody production, was observed in patients with IPF^{18),19)}. We speculate that the high titer of MPO-ANCA in our patient was produced because the patient had a 15-year history of IPF. However, the IPF observed in this patient was considered to be unrelated to the formation of PAN.

MPO-ANCA has been reported to be related to various kinds of tissue damage. The titer of MPO-ANCA is supposed to be correlated with the severity of vasculitis. However, Geffriaud-Ricouard *et al.* reported that the titer of ANCA is not always correlated with the severity of disease²⁰⁾. Moreover, Fuji *et al.* reported that MPO-ANCA obtained from patients with MPO-ANCA-associated glomerulonephritis recognized particular epitopes of MPO²¹⁾. According to their reports, MPO-ANCA that reacts with the upstream site near the N-terminus and the downstream site near the C-terminus of the MPO molecule is related to clinical outcomes and is more frequently pathogenic than MPO-ANCA that evenly reacts with all epitopes. Suzuki *et al.* also reported that most MPO-ANCA obtained from patients with PAN or MPA reacted with only the N- or C-terminus of the heavy chain of the MPO molecule²²⁾. These reports indicate that MPO-ANCA, like other autoantibodies, is heterogeneous and not always harmful. Despite an exceedingly high titer of MPO-ANCA in our patient, he did not develop progressive nephritis or fatal alveolar

hemorrhage, indicating that MPO-ANCA did not cause major tissue damage.

REFERENCES

1. Bakkaloglu A, Ozen S, Baskin E, Besbas N, Gur-Guven A, Kasapcopur O, Tinaztepe K. The significance of antineutrophil cytoplasmic antibody in microscopic polyangitis and classic polyarteritis nodosa. *Arch Dis Child*, **85**: 427-30, 2001.
2. Solans R, Bosch JA, Perez-Bocanegra C, Selva A, Hugueta P, Alijotas J, Orriols R, Armadans L, Vilardell M. Churg-Strauss syndrome: outcome and long-term follow-up of 32 patients. *Rheumatology (Oxford)*, **40**: 763-71, 2001.
3. Guillemin L, Lhote F. Polyarteritis nodosa and microscopic polyangitis. *Clin Exp Immunol*, **101**: 22-3, 1995.
4. Iwama K, Komori H, Niiya Y, Hasegawa H, Sakai I, Fujita S, Yoshida M, Nose M. A case of polyarteritis nodosa limited to both calves with a low titer of MPO-ANCA. (in Japanese) *Ryumachi*, **41**: 875-9, 2001.
5. Tsunoda K, Akaogi J, Ohya N, Murofushi T. Sensorineural hearing loss as the initial manifestation of polyarteritis nodosa. (in Japanese) *J Laryngol Otol*, **115**: 311-2, 2001.
6. Bohgaki T, Mukai M, Notoya A, Kohno M. Two cases of classical polyarteritis nodosa associated with a low titer of MPO-ANCA. (in Japanese) *Ryumachi*, **40**: 9-15, 2000.
7. Handa R, Wali JP, Gupta SD, Dinda AK, Aggarwal P, Wig N, Biswas A. Classical polyarteritis nodosa and microscopic polyangiitis—A clinicopathologic study. *J Assoc Physicians India*, **49**: 314-9, 2001.
8. Lauque D, Cadranet J, Lazor R, Pourrat J, Ronco P, Guillemin L, Cordier JF. Microscopic polyangiitis with alveolar hemorrhage. A study of 29 cases and review of the literature. *Groupe d'Etudes et de Recherche sur les Maladies "Orphelines" Pulmonaires (GERM"O" P)*. *Medicine (Baltimore)*, **79**: 222-33, 2000.
9. Lee CK, Koh JH, Cha HS, Kim J, Huh W, Chung MP, Koh EM. Pulmonary alveolar hemorrhage in patients with rheumatic diseases in Korea. *Scand J Rheumatol*, **29**: 288-94, 2000.
10. Guillemin L, Durand-Gasselin B, Cevallos R, Gayraud M, Lhote F, Callard P, Amouroux J, Casassus P, Jarrousse B. Microscopic polyangiitis: clinical and laboratory findings in eighty-five patients. *Arthritis Rheum*, **42**: 421-30, 1999.
11. Bosch X, Navarro M, Lopez-Soto A, Grau JM, Martinez-Orozco F. Primary polyarteritis nodosa presenting as acute symmetric quadriplegia. *Clin Exp Rheumatol*, **17**: 232-4, 1999.
12. Tsukaguchi M, Takeuchi H, Yamada A, Kazushi D, Nishioka M. Extensive mononeuritis multiplex in polyarteritis nodosa. A case report. (in Japanese) *Shinkei Naika*, **44**: 356-60, 1996.
13. Penas PF, Porras JJ, Fraga J, Bernis C, Sarria C, Dauden E. Microscopic polyangiitis. A systemic vasculitis with a positive P-ANCA. *Br J Dermatol*, **134**: 542-7, 1996.
14. Mansi IA, Opran A, Sondhi D, Ayinla R, Rosner F. Microscopic polyangiitis presenting as idiopathic pulmonary fibrosis: is anti-neutrophilic cytoplasmic antibody testing indicated? *Am J Med Sci*, **321**: 201-2, 2001.
15. Becker-Merok A, Nossent JC, Ritland N. Fibrosing alveolitis predating microscopic polyangiitis. *Scand J Rheumatol*, **28**: 254-6, 1999.
16. Chapman JR, Charles PJ, Venables PJ, Thompson PJ, Haslam PL, Maini RN, Turner Warwick ME. Definition and clinical relevance of antibodies to nuclear ribonucleoprotein and other nuclear antigens in patients with cryptogenic fibrosing alveolitis. *Am Rev Respir Dis*, **130**: 439-43, 1984.
17. Holgate ST, Haslam P, Turner-Warwick M. The significance of antinuclear and DNA antibodies in cryptogenic fibrosing alveolitis. *Thorax*, **38**: 67-70, 1983.

18. Pardo A, Selman M. Molecular mechanisms of pulmonary fibrosis. *Front Biosci*, **7**: D1743-61, 2002.
19. Majumdar S, Li D, Ansari T, Pantelidis P, Black CM, Gizycki M, du Bois RM, Jeffery PK. Different cytokine profiles in cryptogenic fibrosing alveolitis and fibrosing alveolitis associated with systemic sclerosis: a quantitative study of open lung biopsies. *Eur Respir J*, **14**: 251-7, 1999.
20. Geffriaud-Ricouard C, Noel LH, Chauveau D, Houhou S, Grunfeld JP, Lesavre P. Clinical spectrum associated with ANCA of defined antigen specificities in 98 selected patients. *Clin Nephrol*, **39**: 125-36, 1993.
21. Fujii A, Tomizawa K, Arimura Y, Nagasawa T, Ohashi YY, Hiyama T, Mizuno S, Suzuki K. Epitope analysis of myeloperoxidase (MPO) specific anti-neutrophil cytoplasmic autoantibodies (ANCA) in MPO-ANCA-associated glomerulonephritis. *Clin Nephrol*, **53**: 242-52, 2000.
22. Suzuki K. Auto-antibody in vasculitis: Antibody of neutrophilic cytoplasmic antibody ANCA. (in Japanese) *Saishin Igaku*, **55**: 2636-46, 2000.